

# A disfigured foot with ulcer

Our patient had double trouble: An abnormally shaped foot and a large wound on the plantar surface

**A** 60-year-old woman came into our area hospital seeking relief for a foot wound that she'd had for several months (**FIGURE 1A**). The patient said that she had used several antibiotics (prescribed by her primary care physician over the past few months) and she changed her dressings daily, but the wound was not going away. Her podiatrist had evaluated her for osteomyelitis, and the results of the bone biopsy were pending.

The patient had a large wound on the plantar surface of her left foot. The skin over the surface had full-thickness breakdown of the epidermis and dermis, with partial necrosis of the subcutaneous tissue.

Following the wound edges did not reveal undermining, and there was no evidence of sinus tract formation. The ulcer did not extend through the fascia, and there was no gross damage to underlying muscle, bone, or tendon.

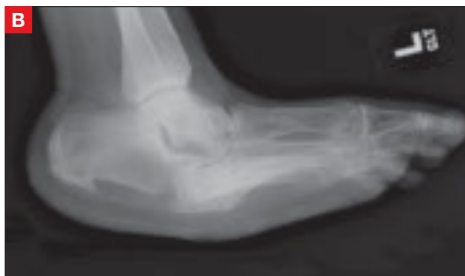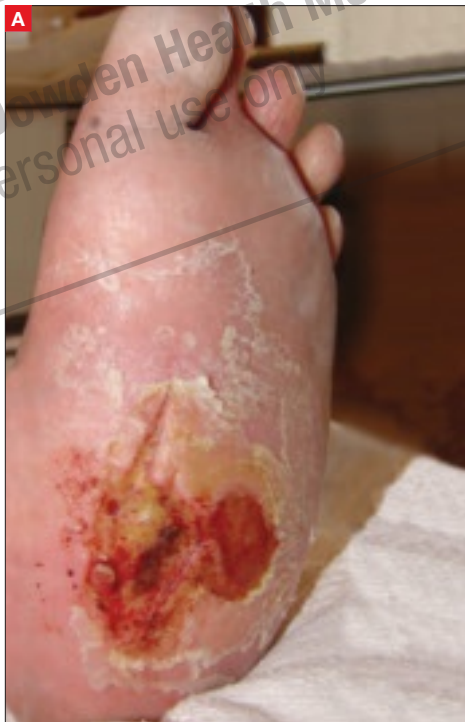Her past medical history was significant for diabetes with neuropathy, nephropathy, and retinopathy. A radiograph was taken (**FIGURE 1B**).

■ **What is your diagnosis of her foot deformity?**

■ **What is the stage of her pressure ulcer?**

**FIGURE 1**

**Abnormally shaped foot and pressure ulcer**



Our 60-year-old patient had full-thickness breakdown of the epidermis and dermis of the plantar surface of her left foot. A radiograph was also taken.

**Shauna Marie Grace, MD**  
University of Colorado,  
Department of Family Medicine,  
Denver

**Daniel L. Stulberg, MD,  
FAAFP**  
University of New Mexico  
Department of Family  
and Community Medicine,  
Albuquerque, NM  
DStulberg@salud.unm.edu

**EDITOR**

**Richard P. Usatine, MD**  
University of Texas Health  
Science Center at San Antonio

**FAST TRACK**

**The patient's podiatrist had evaluated her for osteomyelitis; results of the bone biopsy were pending**

PHOTO BY DANIEL L. STULBERG, MD, FAAFP

TABLE

**Pressure ulcer staging<sup>4</sup>**

<b>Suspected deep tissue injury</b>	Localized area of discolored intact skin or blood-filled blister. Area may be surrounded by tissue that is painful, firm, mushy, boggy, or warmer/cooler than adjacent tissue
<b>Stage I</b>	Nonblanchable erythema of intact skin
<b>Stage II</b>	Partial-thickness loss of dermis that presents as a shallow open ulcer with a red/pink wound bed, without slough
<b>Stage III</b>	Full-thickness tissue loss; subcutaneous fat may be visible, though bone, tendon, or muscle are not
<b>Stage IV</b>	Full-thickness tissue loss with exposed bone, tendon, or muscle. Slough or eschar may be present
<b>Unstageable</b>	Full-thickness tissue loss in which the base of the ulcer is covered by slough and/or eschar

**■ Dx: “Rocker bottom foot,” Stage III pressure ulcer**

The radiograph of the patient’s left foot (**FIGURE 1B**) revealed extensive collapse of the inner arch and a “rocker bottom foot”—the result of Charcot joint changes. Our patient also had an associated Stage III pressure ulcer.

Charcot joint, also known as neurogenic arthropathy, has been linked to tabes dorsalis, but is more commonly seen in diabetic neuropathy, syringomyelia, spinal cord injury, pernicious anemia, peripheral nerve injury, and from prolonged hydrocortisone injections into the joint.<sup>1</sup> The prevalence of Charcot joint in diabetic patients with neuropathy is estimated to be 0.8% to 7.5%. Nine percent to 35% of affected patients have bilateral involvement.<sup>2</sup>

In patients like ours with diabetic neuropathy, secondary degenerative changes to the joints occur as normal muscle tone, proprioception, temperature perception, and pain perception are lost. The joints become loose, enlarged, and boggy. Though the joint is painless, there can be extensive cartilage erosion or osteophyte formation. The normal plantar and heel forces are increased, producing eccentric loading of the foot, leading to microfractures, ligament laxity, and progression to bony destruction.<sup>2</sup>

The area of the foot most likely to be involved is the midfoot (70%), with

the forefoot and rearfoot comprising the other 30% (15% and 15%, respectively). Charcot joint can occur in a short amount of time in patients with diabetic neuropathy who have experienced even minor trauma.<sup>3</sup> In our patient’s case, her trauma history was unknown, though she did comment that her feet initially would ache with walking and then became progressively more disfigured.

**The ulcer connection**

Approximately 50% of diabetic patients with Charcot joint will have an associated plantar ulcer, secondary to the pressure.<sup>3</sup> Our patient had a Stage III pressure ulcer—an ulcer with full-thickness skin loss. With Stage III pressure ulcers, there is also damage or necrosis of the subcutaneous tissue, which may extend down to, but not through, the underlying fascia. (For more on staging pressure ulcers, see **TABLE 4**.)

**A patient with her share of challenges**

Our patient’s podiatrist had diagnosed her with Charcot joint several years prior, and more recently, her primary care physician had put her on antibiotics several times out of concern for cellulitis.

In fact, 2 weeks before we saw her, our patient had started taking antibiotics for a recurrence of infection. Wound cultures which had been sent on the patient were positive for *Staphylococcus aureus* and *Enterococcus*, so she began taking linezolid and clindamycin (she was allergic to penicillin and fluoroquinolones).

Worries that she might have a more serious infection prompted a trip to the podiatrist, who performed an MRI, which was questionable for osteomyelitis. The podiatrist then did a bone biopsy to determine if osteomyelitis was present, and provided mechanical debridement for the wound.

While awaiting the biopsy results, the patient developed increasing pain in her

**FAST TRACK**

**About half of diabetic patients with Charcot joint will have a plantar ulcer**

foot and developed new drainage from the ulcerated wound, so she sought treatment at our hospital over the weekend. Our pressing concern: Was this an acute process, such as osteomyelitis, or worsening Charcot joint?

The biopsy provided our answer: It was negative for osteomyelitis.

### ■ Simple test distinguishes Charcot from infection

A useful test to distinguish Charcot joint from infection in patients who have plantar ulcers is to elevate the affected extremity for 5 to 10 minutes. If swelling and redness persist when the foot is elevated, it is more likely an infectious process. If the swelling and redness resolve, a Charcot process is most likely.

In cases where it's unclear whether the patient has Charcot joint or an infection, it may be necessary to obtain a synovial or bone biopsy to make the diagnosis.<sup>2</sup>

### ■ Treat the pressure ulcer before Charcot joint

The mainstays of treatment for pressure ulcers are relieving local pressure, keeping the area clean, using antibiotics for infection (if needed), debriding as necessary, and applying a dressing.

**Relieving local pressure** is important to reduce formation/progression of pressure ulcers. This can be achieved by careful evaluation of the patient's skin and bony prominences. If the skin is red or irritated—suggesting that the tissue is under increased pressure—the patient can reduce pressure on the area. Custom orthotics can help toward that end. Frequent evaluation for skin breakdown is key to determining whether the intervention is working.

In our patient's case, steps had been taken to relieve pressure. Her physician had instructed her to spend part of her days in a wheelchair (to reduce time spent with direct pressure on the soles of her feet) and the other part wearing custom

## Wound care resources

- **Medline Plus**, at [www.nlm.nih.gov/medlineplus/pressuresores.html](http://www.nlm.nih.gov/medlineplus/pressuresores.html), provides access to basic information regarding pressure ulcers, as well as links to patient information pages from *JAMA* and the American Academy of Family Physicians.
- **The National Pressure Ulcer Advisory Panel (NPUAP)**, at [www.npuap.org](http://www.npuap.org), provides various resources, including staging information.
- **The Braden Score**, developed for neurosurgical patients to predict their risk of skin breakdown, may be a useful tool for evaluating other patients' risk. See [www.bradenscale.com/braden.PDF](http://www.bradenscale.com/braden.PDF) for the assessment form.

orthotics. Unfortunately, she had not been wearing the orthotics. She felt that her regular shoes were more comfortable.

**Keeping the area clean** is of course essential, but there is no need to treat with systemic antibiotics unless there are signs of systemic cellulitis or osteomyelitis on MRI. Topical antibiotics may be used, but be sure to avoid any topical agents or disinfectants that can inadvertently damage new tissue growth.

**Debriding necrotic tissue** decreases bacterial load, increases effectiveness of topical antimicrobials, improves the body's own antimicrobial function, and shortens the inflammatory phase of the wound. It can be accomplished in various ways, including: sharp debridement, mechanical debridement via gauze dressing changes or whirlpool, applied enzymatic agents, autolytic debridement via occlusive dressings, and biologic debridement using sterile maggots to remove necrotic tissue.

**Applying an appropriate dressing** is of course essential. Options include films, hydrogels, hydrocolloids, alginates, foams, and vacuum dressings. Topical dressings help maintain moisture and facilitate healing. Occlusive dressings facilitate autolytic debridement and act as a barrier against soiling. Hydrogels, hydrocolloids, and alginates help to absorb moisture. Vacuum dressings remove excess moisture and facilitate wound contracture and healing.

CONTINUED

### FAST TRACK

**A total contact cast is often needed to relieve the pressure on the prone portion of the foot**

## Next step: Apply a cast

A total contact cast is often utilized to relieve the pressure on the prone portion of the foot. As edema of the affected lower limb decreases over the first week, you'll need to remove the cast and reapply another. Afterward, you can change the cast every 2 to 4 weeks. Recasting can continue for up to 4 months, with interval radiographs recommended every 4 to 6 weeks during this process.<sup>2</sup>

When the extremity is no longer swollen and erythematous, you can transition the patient to an ankle foot orthosis or patellar tendon-bearing brace. Surgical options include resecting bony prominences, osteotomies to re-approximate normal anatomy, and amputation.

continued her wound care with wet to dry dressings alone for further debridement until cellulitis resolved. (Moist healing is usually recommended to allow new tissue growth.)

While we did not treat our patient's pressure ulcers with casting, our plan was to do so when the infection resolved. The patient stayed in the hospital for 6 days and was discharged home with 4 weeks of IV vancomycin via a PICC. ■

### Correspondence

Daniel L. Stulberg, MD, University of New Mexico, Department of Family and Community Medicine, MSC 09 5040, Albuquerque, NM 87131-0001; DStulberg@salud.unm.edu

### Disclosure

The authors reported no potential conflict of interest relevant to this article.

### References

1. Tierney L, McPhee S, Papadakis M. *Current Medical Diagnosis and Treatment*. 4th ed. New York, New York: McGraw Hill Medical Publishing Division; 2004:830.
2. Sommer T, Lee T. Charcot Foot: The Diagnostic Dilemma. *Am Fam Physician*. 2001;64:1591-1598.
3. Armstrong DG, Todd WF, Lavery LA, Harkless LB, Bushman TR. The natural history of acute Charcot's arthropathy in the diabetic foot specialty clinic. *Diabet Med*. 1997;14:357-363.
4. National Pressure Ulcer Advisory Panel. Pressure ulcer stages revised by NPUAP. Available at www.npuap.org. Accessed April 2, 2008.


## Getting our patient back on her feet

Once we learned that our patient's biopsy was negative for osteomyelitis, we began treating her with IV vancomycin for her resistant wound infection. We debrided the pressure ulcer for necrotic tissue.

We initially applied Accuzyme ointment, covered it with Telfa pads, and wrapped it in Kerlix. But the patient developed sensitivity to the Accuzyme, and after discussion with podiatry, we con-

# SUPPLEMENT CORRECTION

In the March 2008 supplement to THE JOURNAL OF FAMILY PRACTICE, "Managing multiple cardiovascular risk factors," an error appeared on page S4 in Table 2. The correct table appears below and is available online at [www.jfponline.com/supplements.asp?id=5998](http://www.jfponline.com/supplements.asp?id=5998).



**TABLE 2**

**JNC 7 compelling indications for specific antihypertensive agents based on favorable outcomes data from clinical trials**

	Diuretic	Beta-Blocker	Angiotensin-Converting Enzyme Inhibitor	Angiotensin Receptor Blocker	Calcium Channel Blocker	Aldosterone Antagonist
CHF	✓	✓	✓	✓		✓
Post-MI		✓	✓	✓		✓
CAD Risk	✓	✓	✓		✓	
Diabetes Mellitus	✓	✓	✓	✓	✓	
Renal Disease			✓	✓		
Recurrent Stroke Prevention	✓		✓			

CAD, coronary artery disease; CHF, congestive heart failure; MI, myocardial infarction.

Chobanian AV, Bakris GL, Black HR, et al, for the National High Blood Pressure Education Program Coordinating Committee. The Seventh Report of the Joint National Committee on Prevention, Detection, Evaluation, and Treatment of High Blood Pressure: the JNC 7 report. *JAMA*. 2003;289:2560-2572.