

Verrucous nodules on the ankle

The scaly nodules appeared over the staple sites of a previous surgery. But did one have anything to do with the other?

A 56-year-old woman came into our medical center complaining of multiple pruritic, slowly growing scaly nodules over her right ankle (FIGURE 1A AND 1B). She indicated that the lesions started as small pink “bumps” at the staple sites of an open reduction and internal fixation surgery of her talus that she’d had 8 years ago.

There were no lesions elsewhere on her body and her past medical history was otherwise unremarkable.

■ **What is your diagnosis?**

■ **How would you manage this condition?**

Thomas M. Beachkofsky, MD, Oliver J. Wisco, DO, and Nicole M. Owens, MD
Wilford Hall Medical Center,
Lackland Airforce Base, Tex

wiscoderm@yahoo.com

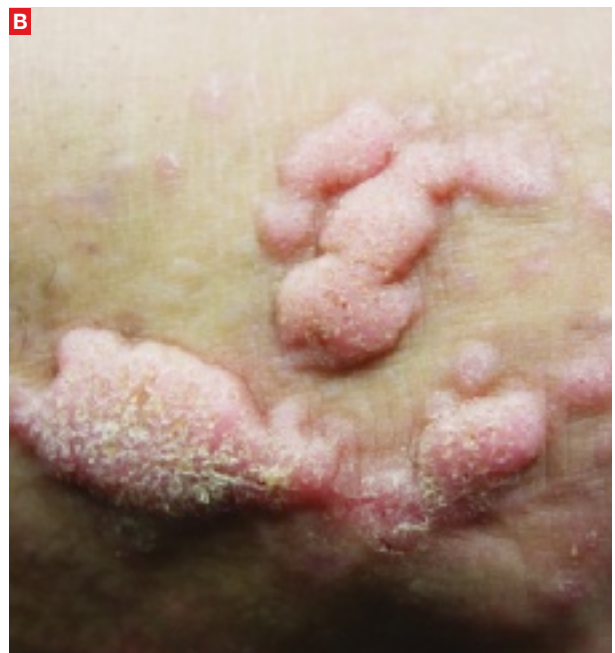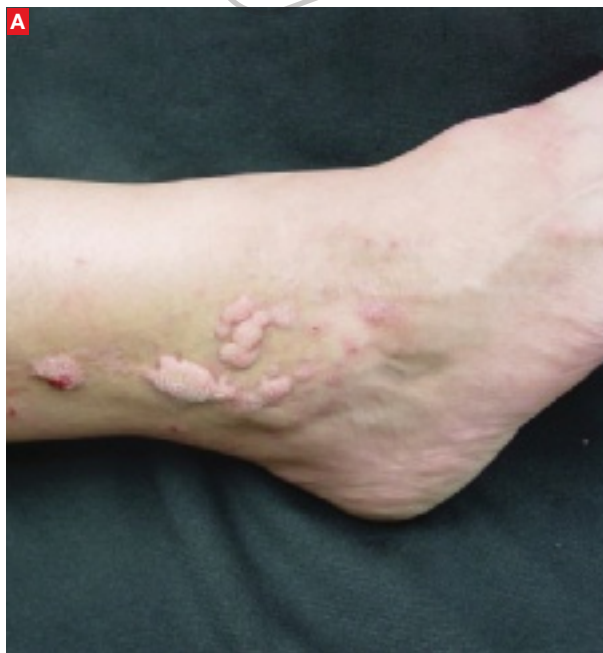Darryl S. Hodson, MD
Skin Surgery Center,
Winston-Salem, NC

EDITOR

Richard P. Usatine, MD
University of Texas Health
Science Center at San Antonio

FIGURE 1

Multiple pruritic, scaly nodules



The 56-year-old patient had multiple verrucous nodules on her right ankle. They appeared on the staple sites of an open reduction and internal fixation surgery of her talus.

PHOTOS COURTESY OF OLIVER J. WISCO, DO

FAST TRACK

The diagnosis of hypertrophic lichen planus is usually straightforward when there are surrounding classic lichen planus lesions. Our patient had no such surrounding lesions.

■ Diagnosis: Hypertrophic lichen planus

Hypertrophic lichen planus (HLP), a variant of lichen planus (LP), is a lesion that is usually found on the distal extremities. HLP plaques evolve from initial characteristic LP lesions (purple, planar, pruritic, polygonal papules or plaque) to form reddish-brown to violaceous, hypertrophic, verrucous round-to-elongated plaques. Primary lesions may be spread by scratching or other trauma and often develop dark brown hyperpigmentation over several years. Like other variants of LP, HLP most commonly affects adults 30 to 60 years of age, with a slight female predominance.¹

HLP may be idiopathic, drug induced, or associated with a systemic disease. Although many drugs have been linked to this lesion, the most commonly reported medications are gold salts, beta-blockers, antimalarials, thiazides, furosemide, and penicillamines. If your patient has HLP and is taking one of these medications, you should consider discontinuing the medication.¹ As with other forms of LP, HLP has been associated with hepatitis C. Consider transaminases and a hepatitis panel for all patients with HLP. Other HLP-associated conditions include venous insufficiency, herpes simplex virus, and varicella-zoster virus.¹

When the history confuses the diagnosis

When there are surrounding classic LP lesions, the diagnosis of HLP is fairly straightforward. However, when the patient has a history of surgery or trauma preceding the lesions and no surrounding classic LP lesions, the diagnosis may be less clear-cut. In such cases, the differential diagnosis includes lichen simplex chronicus, mycetoma, chromoblastomycosis, and squamous cell carcinoma.

Lichen simplex chronicus can be distinguished from HLP by reviewing the patient's history. Patients who describe habitual rubbing or scratching of the area are likely to have lichen simplex

chronicus. On exam, lichen simplex chronicus lesions are slightly erythematous, scaly, well-demarcated, and firm. There are rough plaques with exaggerated skin lines (lichenification) rather than the verrucous surface typically seen with HLP lesions. Wickham's striae (seen in LP) are not seen with lichen simplex chronicus, and the lesions are localized only to easily reached areas.²

Mycetoma is a tumor-like lesion produced by a fungus (eumycetoma) or bacteria (actinomycetoma), typically encountered in arid areas rather than humid environments.³ These chronic, localized, nonpainful subcutaneous nodules develop on the foot and lower extremity after traumatic inoculation with the bacteria or fungus. Mycetomas persist for many years and classically present with a triad of tumefaction, draining sinus tracts, and "sulfur grains" that distinguish it from the dry, hyperkeratotic lesions of HLP. Diagnosis requires biopsy for histologic examination and both fungal and bacterial culture in order to choose the appropriate therapy.

Chromoblastomycosis is a deep fungal infection most commonly caused by the pigmented fungus *Phialophora verrucosa* found in tropical climates.⁴ The fungi enter the skin of the lower extremity after minor trauma, resulting in a gradually expanding verrucous nodule or plaque. The nodular variant is often pedunculated with classic pigmented cauliflower-like florets. While the nodular variant is localized, the plaque variant may spread laterally, possibly metastasizing through lymphatic channels with a concomitant bacterial infection. There is also a characteristic unpleasant odor with lymph stasis.

On potassium hydroxide (KOH) mounts or histologic examination, the thick-walled cells (muriform bodies) of chromoblastomycosis are diagnostic. Patients with chromoblastomycosis have seen response rates >60% with 10 to 24 months of daily itraconazole (200 mg) therapy.⁵

Squamous cell carcinoma (SCC) is the second most common skin cancer and affects more than 250,000 Americans each year. While associated with sun exposure, it has also been linked to ionizing radiation, arsenic, human papilloma virus, cigarette smoking, and chronic nonhealing wounds and scars such as Marjolin's ulcer.¹

Marjolin's ulcer usually appears as a triad of nodule formation, induration, and ulceration at a scar site and thus may be confused with HLP. It is more common than sun-induced SCC in Asian and dark-skinned individuals.⁶ Marjolin's ulcer will usually present in the fifth decade, years after the initial insult. Diagnosis is supported by the clinical appearance and history of a preceding scar at the site. Marjolin's ulcer has a higher rate of recurrence and metastasis than other forms of SCC, and thus should be treated aggressively.^{7,8}

A biopsy may be needed

A drop of immersion oil can confirm your HLP suspicions by revealing the white, lacy reticular network of Wickham's striae.¹ Other clinical clues to the diagnosis of LP or one of its variants include a white reticular, erythematous, or ulcerative appearance on the buccal mucosa in addition to a dorsal pterygium and/or diffuse pitting on the nails.

A deep shave or punch biopsy may be necessary, however, when the clinical diagnosis is unclear. Histological findings demonstrate focal hyperorthokeratosis, saw-toothed rete ridges, vacuolar change at the basal layer, and a band-like lymphocytic infiltrate.

Corticosteroids are the treatment of choice

There have been few large-scale prospective studies exploring the treatment of HLP. However, treatment for HLP is similar to that of LP and typically begins with topical class I or II glucocorticoids or intralesional injections of triamcinolone. Narrow-band ultraviolet-B (UVB) markedly reduces pruritus and flattens plaques, and is considered second-line treatment (strength of recommendation [SOR]: C).⁹⁻¹¹ The retinoid acitretin may be effective for severe HLP at oral dosages of 30 mg/d for 8 weeks (SOR: A).¹² Azathioprine and cyclosporine have also been used successfully, but risk of renal dysfunction, hypertension, and increased viral and fungal infections make these agents third-line therapies (SOR: C).¹³⁻¹⁵

A good outcome for our patient

Our patient applied clobetasol ointment 0.05% to the affected areas twice daily until the lesions went away (approximately 2 months later). ■

CONTINUED

FAST TRACK

The patient applied clobetasol ointment 0.05% twice daily until the lesions went away (about 2 months later).

NEW

Test your diagnostic skills every Friday @ www.jfponline.com


You've enjoyed reading Photo Rounds—and testing your diagnostic skills—each month. Now you can take the challenge every week with **Photo Rounds Friday.**

Each Friday, we'll post a new photo with a brief description and challenge you to make the diagnosis. **Check it out at www.jfponline.com.**



If you're not visiting us at www.jfponline.com, here's what you're missing

THIS MONTH

 **Glucose control for the critically ill:**
 How to implement less aggressive goals
 Adam J. Zolotor, MD, MPH, University of North Carolina,
 Chapel Hill

How common is restless legs syndrome in your practice and what treatments do you typically recommend?

Join the discussion on:

OUR BLOG: <http://journaloffamilypractice.blogspot.com>

FACEBOOK: www.facebook.com/JFamPract

FOLLOW US ON TWITTER:

<http://twitter.com/JFamPract>

ONLINE EXCLUSIVES (See left-hand navigation bar)

- A survivor's guide for primary care physicians
- Use PT to head off this deformity in infants

INSTANT POLL:

What is your typical approach to glucose control in critically ill patients?

WEEKLY

NEW PHOTO ROUNDS FRIDAY

Enjoy our popular monthly feature 4 times as often, with a new image and diagnostic challenge every Friday

TWICE DAILY

PHYSICIAN'S BRIEFING NEWS

Today's headlines in family practice, updated twice daily

24/7

JFPFINDIT:

A lightning-fast search tool for family physicians



Check us out today at www.jfponline.com

PHOTO ROUNDS

Correspondence

Oliver J. Wisco, Maj, USAF, MC, FS, Department of the Air Force, Wilford Hall Medical Center, 59 MDW/SGOMD/Dermatology, 2200 Bergquist Drive, Suite 1, Lackland AFB, TX 78236-9908; wiscoderm@yahoo.com

Disclosure

The authors reported no potential conflict of interest relevant to this article. The views expressed in this article are those of the authors and do not reflect the official policy or position of the Department of Defense or the US government.

References

1. Bologna JL, Jorizzo JL, Rapini RP. *Dermatology*. 2nd ed. St. Louis, Mo: Mosby Elsevier; 2008.
2. Habif TP. *Clinical Dermatology: A Color Guide to Diagnosis and Therapy*. 4th ed. Philadelphia, Pa: Mosby; 2004:65.
3. Fitzpatrick T, Eisen A, Wolff K, et al. *Dermatology in General Medicine*. 5th ed. New York, NY: McGraw-Hill; 1999:2301.
4. Fitzpatrick T, Eisen A, Wolff K, et al. *Dermatology in General Medicine*. 5th ed. New York, NY: McGraw-Hill; 1999:2375.
5. Restrepo A. Treatment of tropical mycoses. *J Am Acad Dermatol*. 1994;31(3 Pt 2):S91-S102.
6. Chuang TY, Reizner GT, Elpern DJ, et al. Nonmelanoma skin cancer in Japanese ethnic Hawaiians in Kauai, Hawaii: an incidence report. *J Am Acad Dermatol*. 1995;33:422-426.
7. Treves N, Pack GT. The development of cancer in burn scars. An analysis and report of thirty-four cases. *Surg Gynecol Obstet*. 1930;51:749.
8. Lifeso RM, Rooney RJ, el-Shaker M. Post-traumatic squamous-cell carcinoma. *J Bone Joint Surg*. 1990; 72:12-18.
9. Gambichler T, Breuckmann F, Boms S, et al. Narrow-band UVB phototherapy in skin conditions beyond psoriasis. *J Am Acad Dermatol*. 2005;52:660-670.
10. Saricaoglu H, Karadogan SK, Baskan EB. Narrowband UVB therapy in the treatment of lichen planus. *Photodermatol Photoimmunol Photomed*. 2003;19:265-267.
11. Taneja A, Taylor CR. Narrow-band UVB for lichen planus treatment. *Int J Dermatol*. 2002;41:282-283.
12. Laurberg G, Geiger JM, Hjorth N, et al. Treatment of lichen planus with acitretin: a double-blind, placebo-controlled study in 65 patients. *J Am Acad Dermatol* 1991;24:434-437.
13. Kossard S, Artemi P. Acitretin for hypertrophic lichen planus-like reaction in a burn scar. *Arch Dermatol*. 2000;136:591-594.
14. Lear JT, English JS. Erosive and generalized lichen planus responsive to azathioprine. *Clin Exp Dermatol*. 1996;21:56-57.
15. Ho VC, Gupta AK, Ellis CN, et al. Treatment of severe lichen planus with cyclosporine. *J Am Acad Dermatol*. 1990;22:64-68.