

“Doctor, my thumb hurts”

How should you treat these common causes of nontraumatic thumb pain? Use this evidence-based review as a clinical decision-making guide.

PRACTICE RECOMMENDATIONS

› Do not treat de Quervain's tenosynovitis with a corticosteroid injection plus a nonsteroidal anti-inflammatory drug; the combination is no more effective than the injection alone. **B**

› Resection arthroplasty of the carpometacarpal (CMC) joint is the gold standard for surgical treatment of thumb CMC osteoarthritis, but should be offered only if conservative measures fail. **C**

› Percutaneous release of trigger thumb combined with a corticosteroid injection provides greater symptom relief than the injection alone. **C**

Strength of recommendation (SOR)

- A** Good-quality patient-oriented evidence
- B** Inconsistent or limited-quality patient-oriented evidence
- C** Consensus, usual practice, opinion, disease-oriented evidence, case series

Among the many possible causes of nontraumatic thumb pain are 3 conditions that primary care physicians are likely to encounter again and again: de Quervain's tenosynovitis (dQT), first carpometacarpal osteoarthritis (CMC OA), and trigger thumb (TT). Common as they are, however, there are no consensus guidelines for the treatment of these conditions.

With that in mind, we did a literature search for studies of treatments for common causes of nontraumatic thumb pain. After reviewing the findings, we developed this evidence-based summary—and the “bottom line” treatment guide on page 331—as an aid to clinical decision making.

de Quervain's tenosynovitis: An overuse injury

dQT is characterized by a gradual onset of pain in the first dorsal compartment of the wrist. The pain is reproduced on physical exam with clenched fist ulnar deviation of the wrist (Finkelstein test) (FIGURE). The suspected cause is overuse, leading to thickening of the tendons of the first dorsal compartment and subsequent resisted gliding of the tendons in their fibro-osseous canal.¹

NSAIDs and injection: No better than injection alone

Conservative treatment of dQT consists of topical or oral nonsteroidal anti-inflammatory drugs (NSAIDs), splinting, and corticosteroid injection.¹ We identified 2 studies using such conservative modalities. The first was a randomized double-blind, placebo-controlled trial, which found that oral NSAIDs combined with corticosteroid injection provided no statistically significant benefit compared with corticosteroid injection alone ($P=.69$).² The second study was a pooled qualitative analysis and showed that 83% (n=495) of patients were asymptomatic after corticosteroid injection alone.³ Treatment failure in the remaining 17% of patients was attributed to poor technique and anatomic variation within the first dorsal compartment.

CONTINUED

Justin A. Crop, DO;
Christopher W. Bunt,
MD, FAAFP

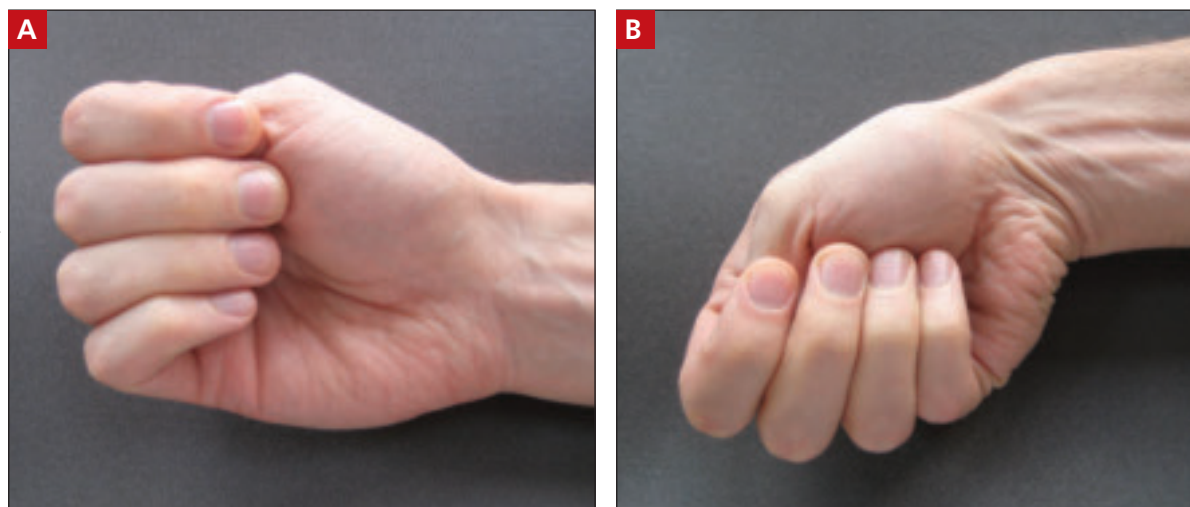
Nellis Air Force Base,
Las Vegas, Nev (Dr. Crop);
University of Nebraska
Medical Center, Omaha
(Dr. Bunt); Uniformed
Services University of the
Health Sciences, Bethesda,
Md (Dr. Bunt)

✉ Christopher.Bunt@offutt.af.mil

The authors reported no potential conflict of interest relevant to this article.

The views expressed here are those of the authors, and do not reflect the opinions of the University of Nebraska Medical Center, the Uniformed Services University, the US Air Force, or the US Department of Defense.

FIGURE
Finkelstein test for de Quervain’s tenosynovitis



PHOTOS COURTESY OF: STEPHANIE K. BUNT, PHD

With elbows flexed to 90°, the forearms parallel to each other and the floor, and the thumb clenched gently inside a fist (A), the patient drops the hand down (adduction) at the wrist (B). Pain over the first dorsal compartment is considered a positive test.

Another arm of the study compared the combination of corticosteroid injection and splinting with splinting alone, which yielded 61% and 14% success rates, respectively. Some patients were treated with NSAIDs and rest alone, but this intervention had a 0% success rate.³

Surgery has a high “cure rate”

Symptoms of dQT of >9 months’ duration may not respond as well to conservative therapy.⁴ In such cases—and for patients for whom conservative measures bring only short-term relief—a surgical referral may be the best approach.

Surgery for dQT, a relatively simple procedure in which the sheaths surrounding the inflamed tendons at the base of the thumb are released to relieve the pain and swelling, has uniformly positive results. The “cure rate”—resolution of symptoms without complications—is reported to be >90%.¹ One researcher found a positive correlation between a longer duration (>9 months) of preoperative symptoms and increased post-operative satisfaction ($P<.4$).⁴

First carpometacarpal OA: Pain, deformity, functional impairment

In a study of patients with joint-specific ar-

thritis of the hand, the prevalence of first CMC OA was reported at 21%.⁵ Symptoms include pain and deformity that may result in significant functional impairment of the thumb. Physical findings may include pain with palpation and swelling and warmth over the dorsal aspect of the CMC joint. The “grind test”—axial compression with internal and external rotation of the CMC joint—should reproduce the pain and may demonstrate crepitus.⁶ As with osteoarthritis in general, CMC OA radiographic findings do not directly correlate with the physical exam.

Splinting and physical therapy bring considerable relief

Conservative treatment options for CMC OA include NSAIDs, physical therapy, splinting, and corticosteroid injection. American College of Rheumatology guidelines support NSAIDs or acetaminophen as a first-line treatment for osteoarthritis pain of the knees and hips, but no guidelines specifically address CMC OA.⁷ Nor have there been any studies focused on NSAID therapy for CMC OA.

One retrospective study (n=130) evaluated splinting the thumb in abduction, and found that it reduced symptoms of CMC OA by an average of 54% to 61% at 6-month follow-up.⁸ The researchers studied the re-

Nontraumatic thumb pain: A bottom line treatment guide

■ **de Quervain's tenosynovitis.** Initially, corticosteroid injection has been found to be the most appropriate first-line treatment for dQT;^{1,4,5} the addition of an oral nonsteroidal anti-inflammatory drug (NSAID) does not result in any additional benefit.⁵ What's more, oral NSAIDs and thumb splinting are not effective.³ Overall, surgical repair has demonstrated the greatest success, but it is invasive and costly.^{1,4}

■ **First carpometacarpal osteoarthritis.** There are few valid clinical trials for CMC OA. The available evidence, however, suggests starting with NSAIDs and progressing to splinting and physical therapy, as needed. Corticosteroid injections provide no long-term pain relief.^{10,11} As with osteoarthritis in general, surgery for CMC OA is usually reserved for patients who fail to respond to conservative treatments.

■ **Trigger thumb.** There are various methods and levels of success for trigger digit treatment, but few studies specifically examining treatment of TT. The evidence suggests starting with conservative treatment—corticosteroid injection and splinting—in patients who are opposed to surgery.¹⁵ Both open and percutaneous surgical release of TT have high success rates, however, and can be offered at any time.¹³

sults of splinting in patients with stage 1 or 2 (mild to moderate) CMC OA vs those with stage 3 or 4 (moderate to severe) CMC OA, and found no significant difference in levels of improvement. In another study of patients with first CMC OA who were treated with splinting and physical therapy for 7 months, 70% of those who underwent treatment declined subsequent surgery, suggesting symptom improvement.⁹

Corticosteroid injections alone for CMC OA have had mixed results. One study compared corticosteroid injection with saline injection (n=40) and reported no difference at 24 weeks' posttreatment.¹⁰ Another found short-term improvement from a corticosteroid injection (n=25), as measured on a visual analog scale at 1 month ($P<.001$), but no significant improvement in symptoms after 3 months.¹¹

Consider surgery if conservative measures fail

As with most cases of osteoarthritis, surgery for CMC OA should be considered only after failure of conservative treatment. Surgical treatment options should be individualized, depending on the extent of disease.

■ **Resection arthroplasty of the CMC joint** is the gold standard for surgical treatment of thumb CMC OA.⁶ In one small study (n=24), researchers found that 90% of patients were satisfied with the outcome after 15 years.¹² There are numerous surgical al-

ternatives, however, and research addressing resurfacing, synthetic implants, and spacer materials is ongoing.⁶

Trigger thumb: Swelling, pain, limited motion

TT, also known as stenosing tenosynovitis, is characterized by swelling, limitation of thumb range of motion, and a "catching" sensation when the thumb is flexed. Pain is usually referred to the first dorsal compartment of the hand. The primary pathology is thickening of the A1 pulley, with resultant entrapment of the flexor tendon, thus forming a triggering mechanism.¹³

Early treatment leads to better response

Conservative treatment options for TT include splinting and corticosteroid injection; NSAIDs alone have not been found to provide any benefit.¹⁴ One study found that corticosteroid injection followed by splinting in 10° to 15° flexion for 3 to 12 weeks relieved symptoms for 66% of those with any trigger digit—but only 50% of patients with TT reported an improvement in symptoms.¹⁵

Overall, patients with TT symptoms for <4 months have been found to respond significantly better to any treatment ($P=.01$).¹⁶ This finding may be related to repeat injury to the tendon sheath, which leads to chronic inflammation and permanent sheath hyper-

➤ Surgical repair of de Quervain's tenosynovitis has a "cure rate" of >90%.

➤ **Early diagnosis and treatment of trigger thumb is important, as repeat injury leads to chronic inflammation and permanent hypertrophy and scarring of the tendon sheath.**

trophy and scarring,¹⁶ and highlights the importance of early diagnosis and treatment.

Limited research has been done on the effect of corticosteroid injection alone on TT. Maneerit et al performed a prospective study (n=115) comparing steroid injection alone with percutaneous release combined with corticosteroid injection, and found that the injection alone was successful in improving symptoms in 47% of patients.¹⁷ (The combination of percutaneous release and steroid injection, discussed below, had a much higher success rate.)

A retrospective study of treatment for trigger digits demonstrated significant improvement with corticosteroid injection in patients who did not have diabetes; 52% had full resolution and 47% had improvement in symptoms ($P=.04$).¹⁸ In contrast, corticosteroid injection led to symptom resolution for only 32% of patients with diabetes.

Surgery for TT: Percutaneous or open release

Surgical treatment options for TT include percutaneous or open release. Complications of surgical intervention for trigger digits include infection, digital nerve injury, scarring, tenderness, and joint contractures. Nimigan

et al reported a 99% improvement in symptoms and return to activity with open surgical release for patients with TT (n=72).¹⁸

In the study by Maneerit et al cited earlier, percutaneous release combined with corticosteroid injection had a success rate (indicated by decreased pain and triggering) of 91%, vs a 47% response rate for the group who received corticosteroid injection alone ($P=.001$).¹⁷ In another study, 25 patients with TT that had failed to respond to conservative treatment underwent percutaneous release. The result: An 84% success rate, as shown by a decrease in reported pain on a visual analog scale ($P<.001$), with no digital nerve damage reported.¹³

Digital nerve damage is more of a concern with percutaneous release than with open release, because of the proximity of the digital nerves to the A1 pulley.¹³ Success rates for percutaneous release vary from 38% to 100%, with improvement shown after appropriate physician training.¹³ **JFP**

ACKNOWLEDGEMENT

The authors thank Joshua Hodge, MD, for his constructive critique of this article.

CORRESPONDENCE

Christopher W. Bunt, MD, Major, USAF, MC, FAAFP, 2501 Capehart Road, Offutt AFB, NE 68113; Christopher.Bunt@offutt.af.mil

References

- Ilyas AM, Ast M, Schaffer AA, Thoder J. De Quervain tenosynovitis of the wrist. *J Am Acad Orthop Surg*. 2007;15:757-764.
- Jirarattanaphochai K, Saengnipanthkul S, Vipulakorn K, et al. Treatment of de Quervain disease with triamcinolone injection with or without nimesulide. A randomized, double-blind, placebo-controlled trial. *J Bone Joint Surg Am*. 2004;86A:2700-2706.
- Richie A, Briner W. Corticosteroid injection for treatment of de Quervain's tenosynovitis: a pooled quantitative literature evaluation. *J Am Board Fam Pract*. 2003;16:102-106.
- Ta KT, Eidelman D, Thomson JG. Patient satisfaction and outcomes of surgery for De Quervain's tenosynovitis. *J Hand Surg Am*. 1999;24:1071-1077.
- Wilder FV, Barrett JP, Farina EJ. Joint-specific prevalence of osteoarthritis of the hand. *Osteoarthritis Cartilage*. 2006;14:953-957.
- Van Heest AE, Kallemeier P. Thumb carpal metacarpal arthritis. *J Am Acad Orthop Surg*. 2008;16:140-151.
- American College of Rheumatology Subcommittee on Osteoarthritis Guidelines. Recommendations for the medical management of osteoarthritis of the hip and knee. *Arthritis Rheum*. 2000;43:1905-1915.
- Swigart CR, Eaton RG, Glickel SZ, et al. Splinting in the treatment of arthritis of the first carpometacarpal joint. *J Hand Surg Am*. 1999;24:86-91.
- Berggren M, Joost-Davidsson A, Lindstrand J, et al. Reduction in the need for operation after conservative treatment of osteoarthritis of the first carpometacarpal joint: a seven year prospective study. *Scand J Plast Reconstr Surg Hand Surg*. 2001;35:415-417.
- Meenagh GK, Patton J, Kynes C, et al. A randomized controlled trial of intra-articular corticosteroid injection of the carpometacarpal joint of the thumb in osteoarthritis. *Ann Rheum Dis*. 2004;63:1260-1263.
- Joshi R. Intraarticular corticosteroid injection for first carpometacarpal osteoarthritis. *J Rheumatol*. 2005;32:1305-1306.
- Freedman DM, Clickel SZ, Eaton RG. Long-term follow-up of volar ligament reconstruction of the thumb. *J Hand Surg Am*. 2000;25A:297-304.
- Cebesoy O, Kose KC, Baltaci ET, et al. Percutaneous release of the trigger thumb: is it safe, cheap and effective? *Int Orthop*. 2007;31:345-349.
- Akhtar S, Bradley MJ, Quinton DN, et al. Management and referral for trigger finger/thumb. *BMJ*. 2005;331:30-33.
- Patel MR, Bassini L. Trigger fingers and thumb: when to splint, inject, or operate. *J Hand Surg Am*. 1992;17:110-113.
- Rhoades CE, Gelberman RH, Manjarris JF. Stenosing tenosynovitis of the fingers and thumb. Results of a prospective trial of steroid injection and splinting. *Clin Orthop Relat Res*. 1984;190:236-238.
- Maneerit J, Sriworakun C, Budhbraja N, et al. Trigger thumb: results of a prospective randomized study of percutaneous release with steroid injection versus steroid injection alone. *J Hand Surg Br*. 2003;28:586-589.
- Nimigan AS, Ross DC, Gan BS. Steroid injections in the management of trigger fingers. *Am J Phys Med Rehabil*. 2006;85:36-43.