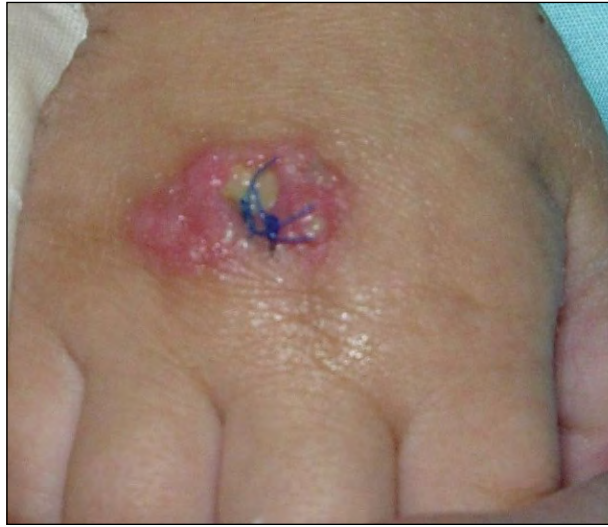

What Is Your Diagnosis?



A 17-month-old boy presented with a pink, erythematous, sharply demarcated nodular plaque on the dorsal aspect of the right hand of 3 days' duration that developed after being hospitalized for approximately 1 week for failure to thrive. Punch biopsy specimens were obtained from the dorsal aspect of the right hand and histologic analysis was performed with Grocott-Gomori methenamine-silver stain.

PLEASE TURN TO PAGE 223 FOR DISCUSSION

Shannon C. Trotter, DO; Dawn L. Sammons, DO

Dr. Trotter was from and Dr. Sammons is from the College of Osteopathic Medicine, Ohio University, Athens. Dr. Trotter currently is from the Division of Dermatology, The Ohio State University, Athens. Dr. Sammons also is in private practice, Athens.

The authors report no conflict of interest.

Correspondence: Shannon C. Trotter, DO, 2012 Kenny Rd, Columbus, OH 43221 (shannon.campbell@osumc.edu).

The Diagnosis: Primary Cutaneous Aspergillosis

The patient had a history of mitochondrial disorder complex I (MDCI) and had been hospitalized for approximately 1 week before being transferred to our institution. His medical history revealed that he had not received any vaccinations and there were no other family members with similar lesions. The patient had an intravenous catheter placed in the dorsal aspect of the right hand when he was hospitalized prior to presentation at our institution. Physical examination revealed a 2-cm, pink, erythematous, sharply demarcated nodular plaque on the dorsal aspect of the right hand (Figure 1).

A punch biopsy showed prominent epidermal hyperplasia, extensive papillary dermal edema, and mixed inflammatory infiltrates at all levels of the dermis. At higher power, abundant neutrophils and neutrophilic debris were noted focally within the deep dermis and an aggregate of basophilic material with the suggestion of septate hyphae was observed. Periodic acid–Schiff stain further revealed an endovascular collection of septate hyphae. Grocott-Gomori methenamine-silver stain highlighted the dermal aggregates of septate hyphae with acute angle branching, consistent with aspergillosis infection (Figure 2). A biopsy for tissue culture also was taken from the dorsal aspect of the right hand and was positive for *Aspergillus fumigatus*. A systemic laboratory evaluation, including blood cultures, computerized tomography of the chest, and lumbar puncture were negative for fungal elements. The patient was diagnosed with primary cutaneous aspergillosis (PCA) and was started on amphotericin B therapy.

Although ubiquitous in nature, *Aspergillus* typically only causes clinically significant infections in immunocompromised hosts.^{1,2} Although cutaneous aspergillosis is rare, *Aspergillus* itself ranks as the second most common cause of opportunistic fungal infections, outnumbered only by *Candida*.¹⁻³ Cutaneous aspergillosis is classified as primary or secondary based on the route of infection.⁴ Primary cutaneous aspergillosis is caused by direct inoculation, such as an intravenous site, which was the suspected route of entry in our case, while secondary cutaneous aspergillosis is the result of direct extension or hematogenous dissemination, with the respiratory tract serving as the most common source.¹ In disseminated aspergillosis, 5% to 10% of patients will develop secondary cutaneous aspergillosis.⁵ In addition to these 2 main types of cutaneous aspergillosis, a third type called contiguity aspergillosis has been offered in which *Aspergillus* first infects a body cavity

(eg, the sinuses) and then extends into the mucosa or skin.^{6,7}

Clinical findings in PCA vary depending on the time of presentation but typically include cellulitis, erythematous patches or plaques progressing to ulceration and eschar formation,^{5,7} hemorrhagic bullae,² nodules,⁴ and pustules.³ Due to the spectrum of presentation in cutaneous aspergillosis, the differential diagnosis can be extensive and is dependent

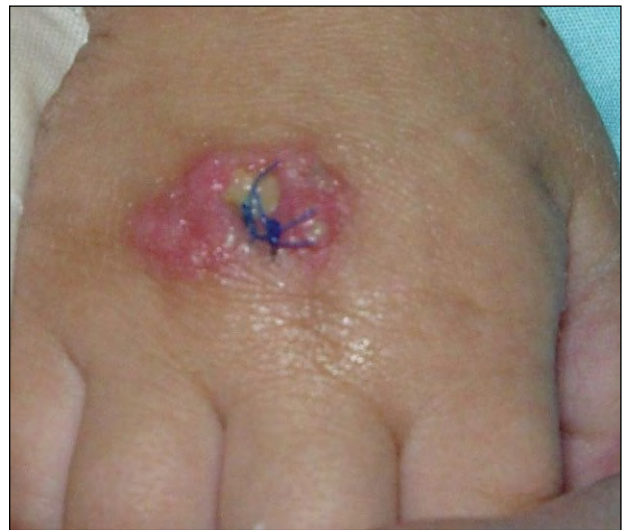

Figure 1. Pink, erythematous, sharply demarcated nodular plaque on the dorsal aspect of the right hand; biopsy sutures were present.

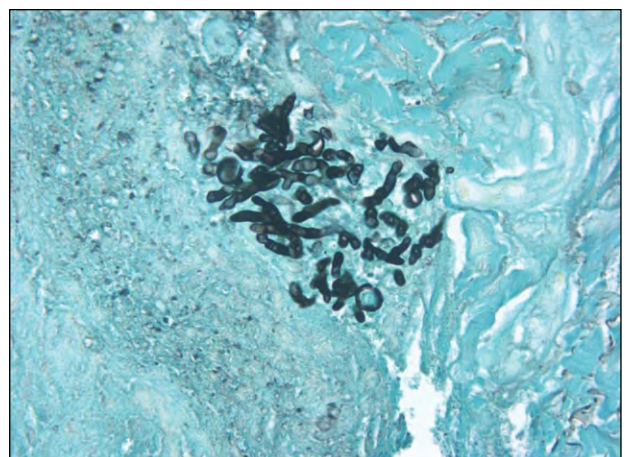


Figure 2. Dermal aggregates of septate hyphae with acute angle branching, consistent with aspergillosis infection (Grocott-Gomori methenamine-silver, original magnification $\times 40$).

on the clinical context of the patient. Diagnosis of PCA includes positive growth in culture, exclusion of other infectious causes, and exclusion of other organ involvement.

Microscopic evidence in PCA demonstrates acute angle branching and septate hyphae with extensive dermal necrosis and superficial inflammation.¹ On the contrary, secondary cutaneous aspergillosis shows inflammation focused in the deep dermal or subcutaneous tissues.¹ Treatment of choice for PCA is amphotericin B^{1,2} and/or itraconazole^{1,4} and also can include surgical excision.¹ Aggressive treatment of PCA is essential in preventing systemic infection.⁵

In our case, the patient also had MDCl, or nicotinamide adenine dinucleotide (reduced form) dehydrogenase deficiency, which belongs to the heterogeneous group of mitochondrial disorders.^{8,9} Mitochondrial disorders result in a variety of abnormalities that classically consist of neuromuscular changes and failure to thrive. Cutaneous and/or hair abnormalities have been detected in approximately 10% of children with mitochondrial disorders.¹⁰

Mitochondrial disorder complex I is the most common mitochondrial disorder and is the result of a defect in nicotinamide adenine dinucleotide dehydrogenase (quinone) oxidoreductase (complex I), one of 3 energy-transducing enzyme complexes of the respiratory chain in mitochondria.^{11,12} Mitochondrial disorder complex I is inherited via mutations in multiple genes, both nuclear and mitochondrial encoded, and consequently has various phenotypic presentations, ranging from Leigh disease to generalized disease with multisystem effects^{8,9,12} as well as increased susceptibility to infection.¹² Our patient had a generalized form of MDCl and an immunodeficiency panel performed on him revealed no abnormalities; however, his history of MDCl, frequent hospitalizations, and possible inoculation via an intravenous catheter may all have served as risk factors for the

development of an opportunistic infection despite no clear immunodeficiency.

REFERENCES

1. Murakawa GJ, Harvell JD, Lubitz P, et al. Cutaneous aspergillosis and acquired immunodeficiency syndrome. *Arch Dermatol.* 2000;136:365-369.
2. Mowad CM, Nguyen TV, Jaworsky C, et al. Primary cutaneous aspergillosis in an immunocompetent child. *J Am Acad Dermatol.* 1995;33:136-137.
3. Papouli M, Roilides E, Bibashi E, et al. Primary cutaneous aspergillosis in neonates: case report and review. *Clin Infect Dis.* 1996;22:1102-1104.
4. van Burik JA, Colven R, Spach DH. Cutaneous aspergillosis. *J Clin Microbiol.* 1998;36:3115-3121.
5. Andresen J, Nygaard EA, Størdal K. Primary cutaneous aspergillosis (PCA)—a case report. *Acta Paediatr.* 2005;94:761-762.
6. Galimberti R, Kowalczyk A, Hidalgo Parra I, et al. Cutaneous aspergillosis: a report of six cases. *Br J Dermatol.* 1998;139:522-526.
7. Woodruff CA, Hebert AA. Neonatal primary cutaneous aspergillosis: case report and review of the literature. *Pediatr Dermatol.* 2002;19:439-444.
8. Loeffen JL, Smeitink JA, Trijbels JM, et al. Isolated complex I deficiency in children: clinical, biochemical and genetic aspects. *Hum Mutat.* 2000;15:123-134.
9. Haas RH, Parikh S, Falk MJ, et al. Mitochondrial disease: a practical approach for primary care physicians. *Pediatrics.* 2007;120:1326-1333.
10. Bodemer C, Rötig A, Rustin P, et al. Hair and skin disorders as signs of mitochondrial disease. *Pediatrics.* 1999;103:428-433.
11. Sterky FH, Larsson NG. Complex I: a complex gateway to the powerhouse. *Cell Metab.* 2008;7:278-279.
12. What is mitochondrial disease? United Mitochondrial Disease Foundation Web site. <http://www.umdf.org/site/pp.aspx?c=8qKOJ0MvF7LUG&b=7934627>. Accessed October 2, 2013.