

# Case Letter

## Frontal Fibrosing Alopecia in an Adolescent Girl

To the Editor:

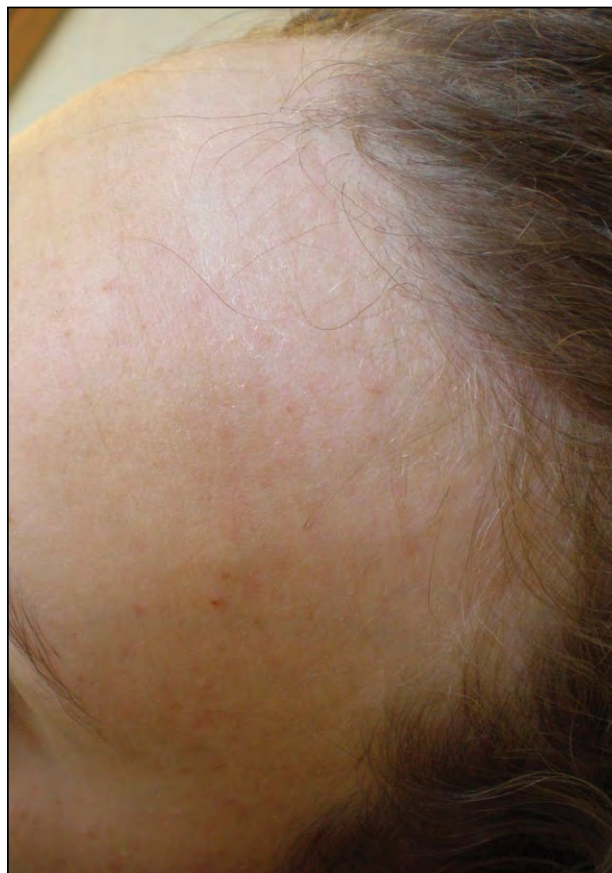Frontal fibrosing alopecia (FFA) is a form of cicatricial alopecia characterized by symmetric recession of the frontal hairline and perifollicular erythema. It usually affects postmenopausal women.<sup>1</sup> We present a rare case of FFA in an adolescent girl.

A 17-year-old adolescent girl presented with progressive alopecia of 1 year's duration. Her medical history, including gynecologic history, was unremarkable. Physical examination revealed a bandlike area of symmetric hair loss involving the frontoparietal area of the scalp with shorter remaining hairs and desquamation (Figure 1). No keratotic plugs or perifollicular erythema were evident. Eyebrows were sparse, and there were no cutaneous lesions on her body. The patient denied using hairstyling practices that exerted excessive tension on the hair, and she did not use chemical or physical straighteners. Laboratory tests, including a complete blood cell count, ferritin level, thyroid function, and sex hormonal assays, only revealed mild anemia. Cutaneous biopsy showed mild dermal fibrosis with a decrease of hair follicles and a sparse inflammatory infiltrate (Figure 2). These histologic findings together with the clinical picture were consistent with FFA. The patient was treated with minoxidil solution 5% and mometasone furoate solution 0.1% with mild improvement.

Postmenopausal FFA was first described by Kossard<sup>2</sup> in 1994. It is characterized by a scarring symmetric recession of the frontal hairline and perifollicular erythema.<sup>1,3-5</sup> Frontal fibrosing alopecia often is associated with alopecia of the eyebrows and less often with the axillae, pubic area, or limbs.<sup>3</sup> Although it predominantly affects postmenopausal women (80%),<sup>1,6</sup> there are reports of its occurrence in premenopausal women and men.<sup>1,3,4,6-9</sup> This form of alopecia now is simply called FFA. Our case of FFA in an adolescent

girl is rare, as the earliest age of onset of FFA reported in the literature is in the third decade of life.<sup>9</sup>

The etiopathogenesis is largely unknown. A T cell-mediated autoimmune reaction appears to play a major part.<sup>5,10</sup> Hormonal influence also has been suggested considering the predominance in women as well as usual postmenopausal onset. However, hormonal disturbances were not found in the laboratory test results of the patients reported in the literature, and hormone replacement therapy did not prevent the development of this condition.<sup>3,5,6,9</sup> Our patient did not report any gynecologic disturbances. Hormonal assays performed were within reference range.

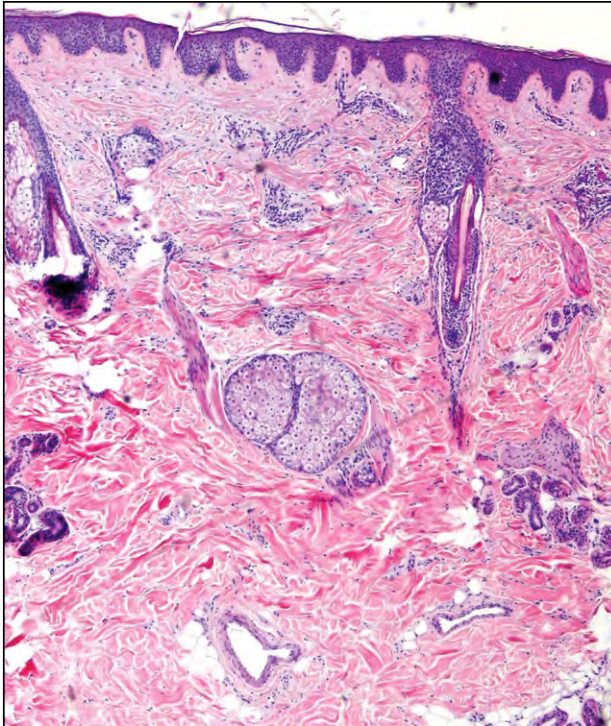


**Figure 1.** A bandlike area of symmetric hair loss involving the frontoparietal area of the scalp.

All from the Department of Dermatology, Complejo Hospitalario de Pontevedra, Spain. Dr. Gómez also is from the Department of Pathology.

The authors report no conflict of interest.

Correspondence: Celia Posada García, MD, Servicio de Dermatología, Hospital Provincial de Pontevedra, CHOP, C/Loureiro Crespo 2 Pontevedra, E-36001 Spain (cposada@aedv.es).



**Figure 2.** Biopsy revealed dermal fibrosis and a decrease of hair follicles with a sparse inflammatory infiltrate around the follicles (H&E, original magnification  $\times 40$ ).

The true nature of FFA is questioned. It is increasingly accepted as a variant of lichen planopilaris.<sup>1,3,6</sup> Although the clinical appearance differs in FFA and lichen planopilaris, histopathologic findings of the 2 entities are similar, with no clear-cut histologic differences between FFA and lichen planopilaris.<sup>5</sup> Lichenoid lesions in the oral cavity and the skin have been reported in association with FFA.<sup>3,6</sup> The differential diagnosis includes the ophiasis variant of alopecia areata, androgenic alopecia (female pattern alopecia), and traction alopecia.<sup>4,11</sup> Cutaneous biopsy ruled out alopecia areata in our patient, and the patient denied hairstyling practices that may cause traction alopecia.

The disease course is highly variable. Most commonly, the disease tends to stabilize spontaneously. There are no randomized clinical trials to evaluate the available modalities.<sup>6</sup> Corticosteroids are considered first-line therapy, but relapse is the rule on their discontinuation. Other options include intralesional triamcinolone acetonide, topical calcineurin inhibitors, and minoxidil. Antimalarials have been tried

with inconsistent results.<sup>1,6</sup> The use of  $5\alpha$ -reductase inhibitors have been reported with good results.<sup>12</sup>

Our case of FFA is unique in that the patient presented in adolescence. Although corticosteroids and minoxidil are considered first-line therapy, these agents achieved poor response in our case. The lack of hormonal disturbances and presentation in postmenopausal and premenopausal women make it difficult to establish the etiopathogenesis of this scarring alopecia.

Celia Posada García, MD  
 Álvaro Gómez, MD  
 Carlos de la Torre, MD

## REFERENCES

1. Samrao A, Chew AL, Price V. Frontal fibrosing alopecia: a clinical review of 36 patients. *Br J Dermatol.* 2010;163:1296-1300.
2. Kossard S. Postmenopausal frontal fibrosing alopecia. scarring alopecia in a pattern distribution. *Arch Dermatol.* 1994;130:770-774.
3. Chew AL, Bashir SJ, Wain EM, et al. Expanding the spectrum of frontal fibrosing alopecia: a unifying concept. *J Am Acad Dermatol.* 2010;63:653-660.
4. Moreno-Ramírez D, Camacho Martínez F. Frontal fibrosing alopecia: a survey in 16 patients. *J Eur Acad Dermatol Venereol.* 2005;19:700-705.
5. Poblet E, Jiménez F, Pascual A, et al. Frontal fibrosing alopecia versus lichen planopilaris: a clinicopathological study. *Int J Dermatol.* 2006;45:375-380.
6. Tan KT, Messenger AG. Frontal fibrosing alopecia: clinical presentations and prognosis [published online ahead of print September 22, 2008]. *Br J Dermatol.* 2009;160:75-79.
7. Jumez N, Bessis D, Guillot B. Frontal fibrosing alopecia is not always post-menopausal [in French]. *Ann Dermatol Venereol.* 2005;132:263.
8. Faulkner CE, Wilson NJ, Jones SK. Frontal fibrosing alopecia associated with cutaneous lichen planus in a premenopausal woman. *Australas J Dermatol.* 2002;43:65-67.
9. Kossard S, Lee MS, Wilkinson B. Postmenopausal frontal fibrosing alopecia: a frontal variant of lichen planopilaris. *J Am Acad Dermatol.* 1997;36:59-66.
10. MacDonald A, Clark C, Holmes S. Frontal fibrosing alopecia: a review of 60 cases. *J Am Acad Dermatol.* 2012;67:955-961.
11. Kwong RA, Kossard S. Alopecia areata masquerading as frontal fibrosing alopecia. *Australas J Dermatol.* 2006;47:63-66.
12. Katoulis A, Georgala, Bozi E, et al. Frontal fibrosing alopecia: treatment with oral dutasteride and topical pimecrolimus. *J Eur Acad Dermatol Venereol.* 2009;23:580-582.