

# Consensus Recommendations From the American Acne & Rosacea Society on the Management of Rosacea, Part 3: A Status Report on Systemic Therapies

James Q. Del Rosso, DO; Diane Thiboutot, MD; Richard Gallo, MD; Guy Webster, MD; Emil Tanghetti, MD; Lawrence F. Eichenfield, MD; Linda Stein-Gold, MD; Diane Berson, MD; Andrea Zaenglein, MD

*The third article in this 5-part series reviews systemic therapies used to treat cutaneous rosacea based on consensus recommendations from the American Acne & Rosacea Society (AARS) on the management of the common presentations of cutaneous rosacea. The consensus recommendations are based on current understanding of research that describes pathophysiologic mechanisms that*

*appear to be operative in rosacea, correlation of these underlying pathophysiologic mechanisms with specific clinical manifestations of rosacea, and outcomes from clinical trials that evaluate therapies for rosacea both as monotherapy and in combination with other agents. Systemic agents used for treatment of rosacea have been administered as oral formulations (ie, tablets, capsules).*

---

Dr. Del Rosso is from Touro University College of Osteopathic Medicine, Henderson, Nevada, and Las Vegas Skin and Cancer Clinics/ West Dermatology Group, Las Vegas and Henderson. Dr. Thiboutot is from Penn State University Medical Center, Hershey. Dr. Gallo is from the University of California, San Diego. Dr. Webster is from Jefferson Medical College, Philadelphia, Pennsylvania. Dr. Tanghetti is from the Center for Dermatology and Laser Surgery, Sacramento. Dr. Eichenfield is from Rady Children's Hospital, San Diego, California, and the University of California, San Diego School of Medicine. Dr. Stein-Gold is from Henry Ford Hospital, Detroit, Michigan. Dr. Berson is from Weill Cornell Medical College and New York-Presbyterian Hospital, New York, New York. Dr. Zaenglein is from Dermatology and Pediatrics, Penn State Milton S. Hershey Medical Center, Hershey, Pennsylvania.

Dr. Del Rosso is an advisory board member and consultant for Allergan, Inc; Bayer Health Care Pharmaceuticals; Galderma Laboratories, LP; Onset Dermatologics; Promius Pharma; Ranbaxy Laboratories Limited; Unilever; Valeant Pharmaceuticals International, Inc; and Warner Chilcott. He also is a researcher for Allergan, Inc; Bayer Health Care Pharmaceuticals; Galderma Laboratories, LP; Onset Dermatologics; and Valeant Pharmaceuticals International, Inc. Dr. Del Rosso also is a speaker for Allergan, Inc; Bayer Health Care Pharmaceuticals; Galderma Laboratories, LP; Onset Dermatologics; Promius Pharma; Ranbaxy Laboratories Limited; Valeant Pharmaceuticals International, Inc; and Warner Chilcott. Dr. Thiboutot is a consultant and investigator for Allergan, Inc, and Galderma Laboratories, LP. Dr. Gallo is a consultant for and has received research grants from Allergan, Inc; Bayer Health Care Pharmaceuticals; and Galderma Laboratories, LP. Dr. Webster is a consultant for Allergan, Inc; Cutanea Life Sciences; Galderma Laboratories, LP; and Valeant Pharmaceuticals International, Inc. Dr. Tanghetti is a consultant, speaker, and investigator for Allergan, Inc; Cynosure, Inc; and Galderma Laboratories, LP. Dr. Eichenfield is a consultant and investigator for Galderma Laboratories, LP, and Stiefel, a GSK company. Dr. Stein-Gold is an advisory board member, consultant, investigator, and speaker for Galderma Laboratories, LP, and LEO Pharma; an advisory board member, consultant, and investigator for Anacor Pharmaceuticals, Inc; an advisory board member, investigator, and speaker for Stiefel, a GSK company; an advisory board member and consultant for Taro Pharmaceuticals USA, Inc; a consultant and investigator for Topica Pharmaceuticals, Inc; an investigator and speaker for Allergan, Inc, and Novartis Corporation; a speaker for Promius Pharma and Ranbaxy Laboratories Limited; and a consultant for Ferndale Laboratories, Inc. Dr. Berson is an advisory board member and consultant for Allergan, Inc; Anacor Pharmaceuticals, Inc; Galderma Laboratories, LP; La Roche-Posay Laboratoire Dermatologique; Procter & Gamble; and Rock Creek Pharmaceuticals. Dr. Zaenglein reports no conflict of interest. The American Acne & Rosacea Society and the authors did not receive any form of funding or compensation for this series of articles, including this manuscript.

This article is the third of a 5-part series. The fourth part will appear next month.

Correspondence: James Q. Del Rosso, DO (jqdelrosso@yahoo.com).

The only oral agent for rosacea approved by the US Food and Drug Administration (FDA) is a modified-release doxycycline 40-mg capsule. Other non-FDA-approved oral agents also are discussed including other tetracyclines, macrolides, metronidazole, and isotretinoin.

*Cutis.* 2014;93:18-28.

**P**art 1 of this 5-part series from the American Acne & Rosacea Society (AARS) provided an overview of rosacea and general measures on management of cutaneous rosacea.<sup>1</sup> Multiple recent publications provide thorough reviews of the pathophysiologic mechanisms that appear to correlate with many of the common clinical manifestations seen in patients with cutaneous rosacea.<sup>2-12</sup> In this article, systemic therapies are reviewed. The AARS brings forth these recommendations as a guide to assist clinicians in the management of the more common presentations of cutaneous rosacea based on both a thorough review of the medical literature and observations from clinical experience.

### Medical Therapies in the Management of Rosacea: Systemic Agents

In the literature, systemic agents used for treatment of rosacea have been administered as oral formulations (ie, tablets, capsules). Clinical studies and case reports on oral agents for treatment of cutaneous rosacea primarily have described the use of tetracycline derivatives (eg, tetracycline, oxytetracycline, doxycycline).<sup>13-20</sup> Despite widespread use of oral tetracycline and other tetracycline agents for treatment of rosacea for approximately 5 decades, the only oral agent that has been formally submitted for approval by the US Food and Drug Administration (FDA) for the treatment of inflammatory lesions of rosacea is a modified-release doxycycline capsule (40 mg once daily), which was approved in 2006.<sup>19,21,22</sup> As a result, there is more available evidence evaluating the use of this formulation versus other oral agents that are used to treat rosacea. In the literature, this once-daily modified-release capsule 40-mg formulation of doxycycline is classified as anti-inflammatory-dose doxycycline<sup>19,21,22</sup>; it also has been referred to as subantimicrobial-dose doxycycline, as it has been shown to reduce inflammatory lesions in patients with papulopustular rosacea (PPR) without producing antibiotic selection pressure, even with prolonged duration over several months.<sup>19,21,23,24</sup> Other oral agents that have been used to treat cutaneous rosacea in small studies and/or case reports include macrolide derivatives (eg, azithromycin, clarithromycin), metronidazole, ampicillin, and isotretinoin, though data

on these drugs are relatively limited compared with tetracyclines, particularly doxycycline.<sup>13,15-27</sup>

It is important to note that the therapeutic outcomes reported for all of these oral agents have been based almost exclusively on the treatment of patients with PPR (ie, facial erythema with papulopustular lesions). To our knowledge, there is little to no published data on the use of oral agents for treatment of erythematotelangiectatic rosacea (ie, facial erythema without papulopustular lesions) or phymatous rosacea (ie, thickened sebaceous proliferation and sometimes fibrosis commonly affecting the nose).<sup>13-18,20</sup> Although data are limited on the treatment of ocular rosacea, doxycycline (100 mg/d), anti-inflammatory-dose doxycycline, and oral azithromycin have been reported to be effective.<sup>28-30</sup>

### Reasons for Emphasis on Use of Oral Tetracyclines in Rosacea

The emphasis in the literature on oral tetracyclines versus other agents for treatment of rosacea likely is due to a spillover effect from the widespread use of tetracyclines for treatment of acne vulgaris, which began in the late 1950s and still continues today.<sup>20</sup> Tetracyclines have additional biologic effects that are unrelated to their antibiotic properties (eg, multiple anti-inflammatory mechanisms), which have attracted the interest of researchers in using this class of agents to treat inflammatory skin disorders such as rosacea and periodontal disease.<sup>27,31-34</sup> The use of oral tetracyclines for treatment of rosacea and acne vulgaris including long-term administration also has been supported by a favorable safety profile, which has been established over several decades (ie, tetracycline for approximately 6 decades; doxycycline for approximately 5 decades; minocycline for approximately 4 decades).<sup>13-15,17,18,20</sup> US Food and Drug Administration approval of anti-inflammatory-dose doxycycline for treatment of rosacea was supported by the publication of pivotal trials<sup>21</sup> with multiple other studies and analyses of study outcomes also reported.<sup>18,19,22,24,35-38</sup>

One review of the literature on oral tetracyclines for treatment of rosacea from 1966 to 1997 found that 69 patients with cutaneous rosacea from 4 different reports were treated with either tetracycline or doxycycline.<sup>20</sup> More recently, doxycycline has emerged in the United States as the most commonly used tetracycline in clinical studies regarding treatment of patients with rosacea, including antibiotic-dose doxycycline (50–200 mg/d) and anti-inflammatory-dose doxycycline.<sup>19,21,22,35-40</sup>

In 2011, an extensive, evidence-based review of interventions for rosacea evaluated 58 trials (N=6633) with emphasis on conclusions drawn from well-designed, randomized, controlled studies that

incorporated tetracycline, oxytetracycline, and doxycycline, especially anti-inflammatory-dose doxycycline.<sup>18</sup> Published data on the use of oral minocycline for treatment of rosacea are limited based on review of summary reports,<sup>13,18,20,41</sup> with only 1 known randomized controlled trial utilizing the extended-release tablet formulation in a low daily dose.<sup>41</sup>

### Anti-inflammatory Properties of Tetracyclines and Therapeutic Effects in Rosacea

To understand the therapeutic effects of oral tetracyclines in patients with rosacea, it is important to review the pathophysiology of rosacea that is relevant to the mechanisms of action of tetracyclines. Most recently, multiple reports suggest that rosacea is an inflammatory skin disease that is not definitively caused by a bacterium or microbial source.<sup>2,3,5-10,12,27,34,42-48</sup> Based on current research, the main pathophysiologic components that appear to be operative in cutaneous rosacea are neurovascular dysregulation and abnormal immune detection and response.<sup>2,3,5-10,43-49</sup> Abnormal immune detection and response in rosacea centers around augmented activation of the cathelicidin cascade, a major pathway that is physiologically involved in innate immunity and frontline antimicrobial defense. In patients with rosacea-prone skin, multiple components contribute to the dysregulation of the cathelicidin cascade, including overexpression in the facial skin of pattern recognition receptors (eg, toll-like receptor 2) that detect environmental trigger factors and signal activation of the cathelicidin pathway via matrix metalloproteinases (MMPs) involved directly in early activation of the cascade, as well as an increase in the quantity and activity of the serine protease enzyme (kallikrein 5 [KLK5]) involved in the production of cathelicidin LL-37 from its precursor (hCAP18 [human cationic antimicrobial protein of 18 kDa]).<sup>1,4,5-10,44-46,48</sup> Other variant cathelicidin-derived peptides that may contribute to the cascades of inflammation are also produced in the overexpressed state demonstrated in rosacea-affected skin.<sup>5,8</sup>

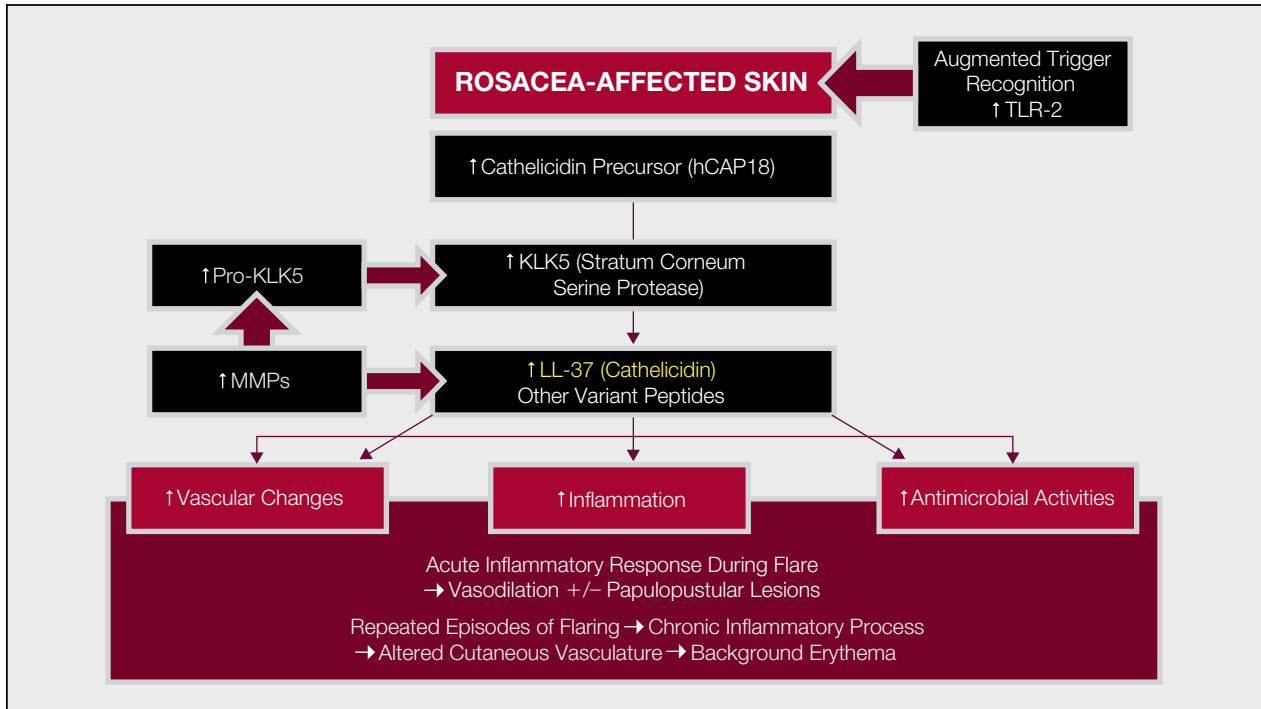
In addition to its normal function as an antimicrobial peptide, cathelicidin LL-37 has been shown in various research models to induce inflammation, vasodilation, and increased vascularity (ie, angiogenesis [increase in vascular endothelial growth factor]), which are all upregulated in rosacea-affected skin.<sup>5,7,8</sup> These cathelicidin LL-37-induced effects correlate with pathophysiologic features and visible manifestations noted in rosacea.<sup>4,5,8,9</sup> The inflammation associated with the increase in cathelicidin LL-37 that occurs during an active rosacea flare contributes to the increased magnitude of facial erythema and possibly the development of papules and pustules along

with IL-8, a potent neutrophil chemoattractant.<sup>2-8</sup> The vasodilation relates to the increase in diffuse erythema with associated soft edema and a warm sensation in the facial skin, which commonly are reported by and observed in patients during a rosacea flare.<sup>2,4,8-10</sup> In the medical literature on rosacea, this vasodilation is referred to as flushing. Although cathelicidin LL-37 appears to contribute to the vasodilation process, it does not operate in a vacuum. Some contradictions exist in the literature, but several other inflammatory mediators and neuropeptides (eg, pituitary adenylate cyclase-activating peptide) appear to play major roles in the emergence of vasodilation, flushing, and neurosensory symptoms in rosacea.<sup>1,2,5,8,11,43-49</sup> Facial telangiectases are almost universally present in rosacea with persistence of diffuse centrofacial erythema commonly noted between rosacea flares.<sup>3,8-11</sup> Both telangiectases and persistent diffuse centrofacial erythema appear to correlate with fixed changes in superficial cutaneous vasculature characterized by an increase in size and possibly number of vessels.<sup>4-11,43</sup> Cathelicidin LL-37 has been shown to increase vascular growth; to induce downstream signaling of cascades, which can increase vascular proliferation and angiogenesis; and to contribute to the production of numerous enlarged facial vessels, along with other chemical messengers (eg, vascular endothelial growth factor, pituitary adenylate cyclase-activating peptide) that correlate with persistent diffuse centrofacial erythema.<sup>5-9</sup>

Although cathelicidin LL-37 does not work alone, as other chemical mediators play important roles, the increased levels of cathelicidin LL-37 observed in rosacea-affected skin play a major role in the pathophysiology of rosacea and appear to contribute to specific visible manifestations of the disease (Figure). Examples of trigger factors, which can induce the activation of the cathelicidin pathway in rosacea-prone skin and induce flares, include ambient heat, UV light exposure, and *Demodex* mite proliferation.<sup>5,8</sup>

### Correlation of Tetracycline Modes of Action and Rosacea Pathophysiology

Tetracyclines have been shown to exhibit multiple anti-inflammatory properties, some correlating with therapeutic activity in rosacea, such as inhibition of several MMPs and inhibition of neutrophil chemotaxis.<sup>31-34</sup> A mechanism of action reported more recently with doxycycline using a human keratinocyte model that appears to relate to therapeutic activity in rosacea is the inhibition of MMP activity, which leads to a reduction in KLK5 activation and activity. This inhibition is ultimately followed by decreased production of cathelicidin LL-37.<sup>50</sup> Minocycline also has been shown to reduce KLK5 activity.<sup>5</sup> The suppression of cathelicidin LL-37 formation through MMP



Formation and effects of increased cathelicidin LL-37 levels and altered peptide formation in the skin during a rosacea flare. TLR-2 indicates toll-like receptor 2; hCAP18, human cationic antimicrobial protein of 18 kDa; KLK5, kallikrein 5; MMP, matrix metalloproteinase. Adapted from Del Rosso.<sup>8,9</sup>

inhibition is clinically relevant, as the inhibition of cathelicidin LL-37 production by this mechanism would be expected to interfere with multiple cascades of inflammation that appear to cause specific clinical manifestations that often are present in cutaneous rosacea.<sup>5-8,27,49</sup> In several studies, subantimicrobial-dose doxycycline has been shown to be effective in the treatment of PPR, both as monotherapy and in combination with topical therapy.<sup>18-22,35-38,51-53</sup> Most studies essentially have shown marked reduction in papules and pustules and at least some reduction in overall facial erythema from a decrease in inflammatory redness (ie, lesional and perilesional erythema).<sup>3,4,8,10,15,18</sup> The favorable therapeutic outcomes of subantimicrobial-dose doxycycline further support the notion that antibiotic activity is not needed for treatment of rosacea and that improvement of signs and symptoms most likely is the result of anti-inflammatory effects.<sup>2,5-9,27,34,42,54,55</sup>

### FDA-Approved Systemic Agent

The only systemic agent that has been approved by the FDA for treatment of PPR is a modified-release doxycycline capsule (40 mg once daily) that has been shown to provide subantimicrobial dosing and is referred to in the literature as anti-inflammatory-dose

doxycycline.<sup>21,23</sup> Approved by the FDA in 2006, this formulation is indicated for treatment of inflammatory lesions of rosacea and allows for immediate release of 30 mg and delayed release of 10 mg of doxycycline, which produces pharmacokinetic and microbiologic profiles shown to be devoid of antibiotic selection pressure (subantimicrobial) while still exhibiting anti-inflammatory effects.<sup>21,24,27,33,34,51,54-61</sup> These anti-inflammatory effects appear to correlate with many of the biologic properties reported with tetracycline derivatives, which are unrelated to antibiotic effects.<sup>13,17-20,27,31-34,51,54-60</sup> The absence of selection pressure in support of subantimicrobial dosing of doxycycline was demonstrated in multiple microbiologic studies of long-term administration and longitudinal microbiologic testing for 6 to 18 months with specimens obtained from the skin, mouth, gastrointestinal (GI) tract, and vaginal tract.<sup>21,24,55-57</sup> Although many tetracycline agents other than doxycycline exhibit a variety of biologic properties that modulate several inflammatory cascades, doxycycline is the only agent with a specified daily dosing and a specific formulation that has been developed to provide anti-inflammatory effects with no antibiotic activity (ie, absence of selective pressure; absence of generation of antibiotic resistance).<sup>21,23</sup> This separation of antibiotic

from anti-inflammatory activities was based on studies of long-term administration of subantimicrobial-dose doxycycline versus placebo, longitudinal completion of microbiologic studies including cultures and antibiotic sensitivity testing both during use (6–18 months) and posttherapy (≤6 months), analysis of dose-finding and pharmacokinetic profiles, and assessment of therapeutic outcomes in clinical trials.<sup>18-24,33-38,50-59,62</sup> The efficacy and safety of anti-inflammatory–dose doxycycline in patients with PPR has been established in multiple clinical trials.<sup>18,19,21,22,35-38,51,62,63</sup> Regardless of the dosage, tetracyclines are not to be administered during pregnancy.<sup>64</sup>

**Management Caveats**—The only oral formulation and dosing regimen that is FDA approved for the treatment of rosacea is anti-inflammatory–dose doxycycline (40 mg once daily), which was based on pivotal studies evaluating its use as monotherapy in patients with PPR.<sup>21,23</sup> Additional studies have demonstrated the efficacy of anti-inflammatory–dose doxycycline as monotherapy or in combination with topical therapy (eg, metronidazole, azelaic acid) for treatment of PPR.<sup>18,19,21,22,35-38,51,63</sup>

The magnitude of the effects of anti-inflammatory–dose doxycycline on inflammatory lesions of rosacea (ie, percent reduction in lesion count) has been shown to be relatively consistent irrespective of the patient's weight or rosacea severity rating at baseline.<sup>19,54</sup> In a study of patients with PPR (predominantly of moderate severity) treated with topical metronidazole and either anti-inflammatory–dose doxycycline or antibiotic-dose doxycycline (nonenteric-coated formulation [100 mg once daily]), the therapeutic response was nearly identical in both groups based on reduction of inflammatory lesion counts and investigator global assessment scores.<sup>38</sup> Gastrointestinal side effects (eg, nausea, vomiting, diarrhea, abdominal discomfort/pain) occurred only within the antibiotic-dose doxycycline treatment group.<sup>38</sup>

Studies completed over 12 weeks in patients with moderate to severe PPR have shown that the combination of oral doxycycline (including either anti-inflammatory–dose or antibiotic-dose doxycycline) with metronidazole gel 1% or azelaic acid gel 15% has been shown to induce faster onset of therapeutic effects and augment the magnitude of improvement based primarily on lesion count reduction and investigator global assessment scores.<sup>19,22,35,38,39,40,63</sup> A survey of 300 dermatologists in clinical practice across the United States showed that 83.7% utilized this combination therapy approach initially in patients with moderate to severe PPR, with the objective of achieving quicker and better control of rosacea signs and symptoms before switching to a maintenance

regimen.<sup>65</sup> More studies are needed to further evaluate the efficacy and optimal use of combination therapies in patients with PPR as well as in other clinical presentations of the disease.<sup>18,63</sup>

There currently is no definitive evidence to show that rosacea is caused by a specific bacterium or that antibiotic activity is needed to effectively treat rosacea.<sup>2,5,6,8,12</sup> The AARS has recommended that PPR initially should be treated with an approach that incorporates drugs with anti-inflammatory activities that have been shown to be of therapeutic benefit and that avoids antibiotic exposure, which induces the selection of antibiotic-resistant bacteria.<sup>42</sup> When treatment with oral agents is deemed necessary, subantimicrobial-dose doxycycline is a rational initial approach and can be achieved with the use of anti-inflammatory–dose doxycycline or with the use of immediate-release doxycycline 20 mg twice daily. The latter subantimicrobial approach is FDA approved for treatment of chronic gingivostomatitis and has been shown to be effective in reducing inflammatory lesions of PPR, though it is not FDA approved for rosacea.<sup>20,52,53</sup> An advantage of anti-inflammatory–dose doxycycline over immediate-release doxycycline 20 mg twice daily is that patients are more likely to comply with a once-daily regimen. Compliance-related factors may explain why anti-inflammatory–dose doxycycline produced a reduction in inflammatory lesions that was approximately 2-fold greater than the reductions shown with immediate-release doxycycline 20 mg twice daily in adults with PPR, despite the use of nearly identical study protocols.<sup>21,52</sup>

The GI absorption and systemic bioavailability of the second-generation tetracyclines (ie, doxycycline, minocycline) are reported to be less affected by coingestion with food, including some divalent and trivalent metal ions (ie, calcium, magnesium, aluminum) compared with tetracycline.<sup>64,66-68</sup> It is important to recognize that not all individuals exhibit the same amount of GI absorption after administration of a specific drug in a given dosage and same formulation, including with tetracyclines,<sup>66</sup> which can lead to marked differences in bioavailability from one patient to another. The actual amount of drug absorbed from the GI tract exhibits interpatient variability with some individuals being high absorbers and some low absorbers of a given agent.<sup>66</sup> When prescribing a lower dose of a tetracycline such as doxycycline or minocycline, there is a risk that certain factors can decrease GI absorption of the drug (ie, concurrent metal ion ingestion in vitamins/supplements, antacids) even to a modest extent in a patient who is classified as a low absorber, which could decrease systemic bioavailability in some of these patients to a subtherapeutic

level.<sup>64,68</sup> It is prudent to advise patients to ingest any foods, vitamins/supplements, and/or medications (eg, antacids) that contain substantial amounts of metal ions at least 2 hours after taking a tetracycline agent, especially when the drug is given in a low dose. Iron has been shown to bind avidly to both doxycycline and minocycline.<sup>68,69</sup>

Clinical trials completed with subantimicrobial-dose doxycycline did not elicit any adverse effects or new safety signals beyond what is already known with doxycycline use; some adverse effects may be circumvented or reduced in frequency.<sup>13,15,16,19-21,36</sup> In addition to avoidance of both antibiotic selection pressure and the production of antibiotic-resistant bacterial strains, use of subantimicrobial-dose doxycycline appears to reduce the risk for photosensitivity, which is a dose-related adverse event.<sup>19-21,70</sup> The risk for vaginal candidiasis also appears to be absent or negligible with subantimicrobial-dose doxycycline.<sup>19-21</sup>

In patients who are low absorbers of doxycycline, it may be necessary to administer a higher daily dose of the drug to overcome the reduction in systemic bioavailability if the therapeutic response to a sufficient course of subantimicrobial-dose doxycycline is not adequate. Because there is no method to determine if a patient is a low absorber, the need to alter the dosing regimen must be determined by clinical evaluation and assessment of patient adherence. This dosing adjustment is made to obtain greater bioavailability to achieve more effective results by using a daily doxycycline dose of 50 mg or more, with the trade-off being that antibiotic selection pressure would no longer be avoided.<sup>19-21,56</sup>

### Alternative Systemic Therapies (Non-FDA Approved)

Non-FDA-approved systemic therapies for rosacea have primarily included oral antibiotics (ie, tetracyclines, macrolides, metronidazole) for PPR and oral isotretinoin in select refractory cases of PPR and early phymatous disease characterized predominantly by sebaceous gland hypertrophy and/or proliferation.<sup>13,15,17,18,25,26,64,66-73</sup> Oral ivermectin has been successfully used (often in combination with topical permethrin) in patients with demodicosis presenting with a rosaceaform eruption associated with marked facial proliferation of *Demodex* mites.<sup>74,75</sup> The clinical presentation of demodicosis is highly suggestive of moderate to severe PPR and often is refractory to therapies commonly used to treat rosacea. As demodicosis is described as a simulant of rosacea, it is not discussed further in this article. However, facial proliferation of *Demodex* mites may serve as a trigger to induce a flare in individuals with rosacea-prone skin.<sup>3,5,8,10,12</sup>

**Tetracyclines**—Oral antibiotics comprise the vast majority of non-FDA-approved systemic agents used for rosacea.<sup>13-18</sup> Tetracyclines have played a major role in conventional approaches to the treatment of rosacea for approximately 5 decades, incorporating dosage regimens that produce antibiotic activity; however, clinical trials in patients with rosacea are relatively limited and no oral antibiotic agent has ever been submitted to the FDA for approval for rosacea.<sup>13-18,20,56,62</sup> The most common tetracycline derivatives reported in clinical trials and cases series are tetracycline and doxycycline, with a conspicuous absence of published studies regarding minocycline in the treatment of rosacea.<sup>13-18,20,62</sup> The use of these agents has been empiric, with no dose-ranging studies completed and therapeutic benefit likely related to the anti-inflammatory properties of tetracyclines.<sup>18,20,27,31-34,62</sup> Overall, oral tetracyclines used in antibiotic doses are effective in reducing inflammatory lesions and inflammatory erythema (ie, lesional, perilesional) in patients with PPR; however, there are no comparative studies that demonstrate superiority of antibiotic-dose doxycycline over subantimicrobial-dose doxycycline.<sup>13,16,18,20,62</sup>

The overall safety of tetracyclines has been favorable; however, it is important for clinicians to be mindful of certain potential adverse events, especially because therapies for rosacea often are used for several weeks to months.<sup>64,67,71-73,76,77</sup> Gastrointestinal side effects, including pill esophagitis, occur most frequently with immediate-release doxycycline versus other tetracyclines, including nonenteric-coated formulations of doxycycline.<sup>38,64,71-73,77</sup> Dose-related phototoxicity also occurs more commonly with doxycycline, especially in doses of 100 mg daily or more.<sup>64,70-73</sup> Cutaneous hyperpigmentation (ie, blue or gray discoloration of skin and/or mucosa; patchy brown pigmentation, especially on the anterior legs; blue discoloration of acne scars) and acute vestibular side effects (eg, vertigo, dizziness) occur almost exclusively with minocycline.<sup>64,67,72,73</sup> Drug hypersensitivity syndrome (eg, drug reaction with eosinophilia and systemic symptoms [DRESS] syndrome), drug-induced lupuslike syndrome, and autoimmune hepatitis are relatively uncommon yet are potentially severe complications that have been associated with minocycline use.<sup>64,67,72,73</sup> Benign intracranial hypertension, commonly referred to as pseudotumor cerebri, is a rare but serious potential complication that can be caused by any of the tetracycline agents.<sup>64,67</sup> Early recognition of benign intracranial hypertension and discontinuation of the causative agent are vital to avoid permanent visual disturbances.<sup>64,67,71,76</sup>

**Macrolides**—Oral erythromycin has been reported to be effective in the treatment of PPR; however,

data are limited.<sup>13,17</sup> Additionally, the common occurrence of GI intolerance and the potential for several clinically relevant drug interactions support the use of other agents with less risk for adverse events and toxicity.<sup>64</sup> The second-generation macrolides, azithromycin and clarithromycin, have been used for treatment of PPR.<sup>13,17,18,78-81</sup> Although no known large-scale, randomized, controlled trials have been conducted, several small studies and case reports have demonstrated the effectiveness of oral azithromycin for PPR, with a variety of dosing regimens used.<sup>13,17,25,78-80</sup> Macrolides, specifically azithromycin, have been shown to exhibit a variety of immunomodulatory and anti-inflammatory effects in various models, with a reduction in reactive oxygen species shown in patients with PPR.<sup>82-84</sup> As azithromycin reaches high tissue levels, intermittent dosing schedules have been used (ie, 250 mg 3 days per week; 500 mg 3 consecutive days per week).<sup>17,18,80,84,85</sup> Clarithromycin also was reported to be effective; however, data are limited and its use has not gained widespread acceptance, likely due to greater risk for GI intolerance, metallic taste, and drug interactions compared with azithromycin.<sup>18,64,81</sup> Concerns regarding macrolide-induced antibiotic resistance and potential side effects (ie, QT prolongation) also have limited the widespread use of second-generation macrolide antibiotics, as they are commonly used for treatment of a variety of bacterial infections.<sup>64,86</sup>

**Metronidazole**—Although oral metronidazole once was popularized as a treatment for PPR primarily in Europe, data are limited on its use for this indication, with efficacy supported by only a few small studies.<sup>13,17,18</sup> Ingestion of alcohol must be completely avoided during treatment with oral metronidazole due to a disulfiramlike reaction.<sup>13,17</sup> Although rare, reports of seizures and neuropathy dampened enthusiasm for this agent as a commonly used therapy for rosacea.<sup>17</sup>

**Isotretinoin**—Oral isotretinoin has been shown to be effective in treating some refractory cases of PPR.<sup>13,17,26,87,88</sup> Available data indicate that isotretinoin (0.3 mg/kg daily) is an efficacious and well-tolerated option for the treatment of PPR and early phymatous rosacea and may serve as an alternative in selected cases of refractory PPR.<sup>26,87,88</sup> It is important to note that all US patients who are treated with isotretinoin must be enrolled in the iPLEDGE program and must fully comply with all elements of the program, including appropriate clinical and laboratory safety assessments and avoidance of pregnancy.<sup>89</sup>

Unlike in acne vulgaris, long-term remission of rosacea signs and symptoms does not occur when isotretinoin is discontinued, as therapeutic benefit requires continued use. In one study, 12 patients with

recalcitrant rosacea initially treated with isotretinoin (10 or 20 mg daily) for 4 to 6 months were transitioned to microdose isotretinoin, which utilized an individual continuous minimal dose ranging from 0.03 to 0.17 mg/kg daily (mean, 0.07 mg/kg daily).<sup>88</sup> Favorable improvements in the quality of life indices were noted in patients treated with this isotretinoin regimen for rosacea. Although cumulative doses of isotretinoin that were 1075 mg/kg or lower were not associated with any remarkable radiologic abnormalities, more studies are suggested to better confirm these findings.<sup>26,88</sup> Because data are limited overall on management of refractory cases of rosacea, microdose isotretinoin is best considered in select cases.<sup>26</sup>

Isotretinoin has been reported to reduce nasal volume, primarily in patients with early phymatous change that is characterized by sebaceous gland hypertrophy and hyperplasia; however, recurrence is highly likely after oral isotretinoin is discontinued.<sup>13,90</sup> Mucinous and fibrotic phymatous changes are not responsive to isotretinoin therapy.

**Management Caveats**—Although most are not approved by the FDA, oral tetracyclines (including antibiotic-dose doxycycline) have been shown to be effective in treating patients with PPR and ocular rosacea.<sup>13,18,28,42,56</sup> An increased risk for dose-related side effects and potential consequences of antibiotic selection pressure are major factors that may be associated with oral tetracycline antibiotic therapy and can be circumvented or reduced with subantimicrobial dosing of doxycycline in many cases.

No dosing regimens or formulations of minocycline have been shown to have subantimicrobial properties, including pelletized forms and extended-release tablets with or without weight-based dosing.<sup>66,91</sup>

Other than anti-inflammatory-dose doxycycline (40-mg modified-release capsule once daily) and doxycycline 20 mg twice daily, no other doxycycline formulations or regimens have been shown to have subantimicrobial properties, including enteric-coated doxycycline.<sup>19,20,21,64,92</sup> Enteric-coated doxycycline is associated with fewer GI side effects compared with conventional tablets or capsules.<sup>64,77</sup>

In patients with PPR who cannot use tetracycline agents, oral azithromycin appears to be a reasonable alternative, though more studies are needed for further evaluation of its efficacy and safety as well as optimal dosing regimens.<sup>13,17,78-80,84</sup> Oral isotretinoin may be a reasonable option in patients with refractory, moderate to severe PPR, as well as in patients with rhinophyma, especially in its early development, which is characterized by sebaceous gland proliferation.<sup>13,17,26,87,88,90</sup> However, unlike in acne vulgaris, long-term remission is not often achieved after oral isotretinoin is discontinued.

When selecting oral agents, clinicians are encouraged to assess the clinical response and carry out appropriate follow-up with patients to monitor for potential adverse reactions.<sup>64</sup> It is important to note that all of the oral agents discussed in this article should be avoided during pregnancy.

## Conclusion

Systemic therapy for rosacea has been limited to oral therapy, most commonly antibiotics, used primarily to treat PPR. The tetracyclines have been the predominant therapeutic class used in rosacea therapy. Despite widespread use of tetracycline for more than 5 decades and its major congeners (doxycycline, minocycline) for more than 4 decades, the only FDA-approved oral therapy for rosacea is anti-inflammatory-dose doxycycline (40 mg once daily), which is indicated for treatment of inflammatory lesions (papules, pustules). Subantimicrobial dosing of doxycycline provides therapeutic benefit with the advantage of not producing antibiotic selection pressure. Among the alternative oral therapies used for PPR in selected cases, azithromycin appears to be a reasonable option and consideration may also be given to metronidazole, though data are more limited with the latter agent. Although oral isotretinoin is not FDA approved for treatment of any form of rosacea, it is an option to consider in selected cases of refractory PPR and early rhinophyma, though prolonged remissions are not likely after the drug is stopped. Oral therapies for rosacea may be used in combination with topical therapies in cases of greater severity and/or when the clinician anticipates discontinuing the oral agents once the flare is controlled and continuing treatment with the topical agent alone. In cases of rosacea or a rosaceaform facial eruption induced by overgrowth of *Demodex* mites, oral ivermectin therapy may be effective, especially when other therapies for rosacea do not produce satisfactory therapeutic results.

**Acknowledgment**—The recommendations published here are primarily based on thorough literature review and observations from clinical experience and research when supported by reasonable consensus among the authors. They are not suggested as mandatory and are not intended to be inclusive of all situations encountered in clinical practice.

## REFERENCES

1. Del Rosso JQ, Thiboutot D, Gallo RL, et al. Consensus recommendations from the American Acne & Rosacea Society on the management of rosacea, part 1: a status report on the disease state, general measures, and adjunctive skin care. *Cutis*. 2013;92:234-240.
2. Steinhoff M, Buddenkotte J, Auber J, et al. Clinical, cellular, and molecular aspects in the pathophysiology of rosacea. *J Invest Dermatol Symp Proc*. 2011;15:2-11.
3. McAleer MA, Lacey N, Powell FC. The pathophysiology of rosacea. *G Ital Dermatol Venereol*. 2009;144:663-671.
4. Del Rosso JQ, Gallo RL, Tangchetti E, et al. An evaluation of potential correlations between pathophysiologic mechanisms, clinical manifestations, and management of rosacea. *Cutis*. 2013;91(suppl 3):1-8.
5. Yamasaki K, Gallo RL. The molecular pathology of rosacea [published online ahead of print May 29, 2009]. *J Dermatol Sci*. 2009;55:77-81.
6. Fleischer AB Jr. Inflammation in rosacea and acne: implications for patient care. *J Drugs Dermatol*. 2011;10:614-620.
7. Yamasaki K, Gallo RL. Rosacea as a disease of cathelicidins and skin innate immunity. *J Invest Dermatol Symp Proc*. 2011;15:12-15.
8. Del Rosso JQ. Advances in understanding and managing rosacea: part 1: connecting the dots between pathophysiological mechanisms and common clinical features of rosacea with emphasis on vascular changes and facial erythema. *J Clin Aesthet Dermatol*. 2012;5:16-25.
9. Del Rosso JQ. Advances in understanding and managing rosacea: part 2: the central role, evaluation, and management of diffuse and persistent facial erythema of rosacea. *J Clin Aesthet Dermatol*. 2012;5:26-36.
10. Crawford GH, Pelle MT, James WD. Rosacea: I. etiology, pathogenesis, and subtype classification. *J Am Acad Dermatol*. 2004;51:327-341; quiz 342-344.
11. Helfrich YR, Varani J, Fisher GJ, et al. Mast cell and neuropeptide expression are increased in erythematotelangiectatic rosacea in comparison to telangiectatic photoaging. Poster presented at: Society of Investigative Dermatology Annual Meeting; May 9-12, 2012; Raleigh, NC. P093.
12. Lazaridou E, Giannopoulou C, Fotiadou C, et al. The potential role of microorganisms in the development of rosacea [in English, German][published November 8, 2010]. *J Dtsch Dermatol Ges*. 2011;9:21-25.
13. Pelle MT, Crawford GH, James WD. Rosacea: II. therapy. *J Am Acad Dermatol*. 2004;51:499-512; quiz 513-514.
14. Del Rosso JQ. Medical treatment of rosacea with emphasis on topical therapies. *Expert Opin Pharmacother*. 2004;5:5-13.
15. Del Rosso JQ, Baum EW. Comprehensive medical management of rosacea: an interim study report and literature review. *J Clin Aesthet Dermatol*. 2008;1:20-25.
16. Odom R, Dahl M, Dover J, et al. Standard management options for rosacea, part 2: options according to rosacea subtype. *Cutis*. 2009;84:97-104.
17. Kennedy Carney C, Cantrell W, Elewski BE. Rosacea: a review of current topical, systemic and light-based therapies. *G Ital Dermatol Venereol*. 2009;144:673-688.
18. van Zuuren EJ, Kramer S, Carter B, et al. Interventions for rosacea [published online ahead of print March 16, 2011]. *Cochrane Database Syst Rev*. 2011:CD003262.



19. Del Rosso JQ. Anti-inflammatory dose doxycycline in the treatment of rosacea. *J Drugs Dermatol*. 2009;8:664-668.
20. Bikowski JB. Subantimicrobial dose doxycycline for acne and rosacea. *Skinmed*. 2003;2:234-245.
21. Del Rosso JQ, Webster GW, Jackson M, et al. Two randomized phase III clinical trials evaluating anti-inflammatory dose doxycycline (40-mg doxycycline, USP capsules) administered once daily for treatment of rosacea [published online ahead of print March 23, 2007]. *J Am Acad Dermatol*. 2007;56:791-802.
22. Fowler JF Jr. Combined effect of anti-inflammatory dose doxycycline (40-mg doxycycline, usp monohydrate controlled-release capsules) and metronidazole topical gel 1% in the treatment of rosacea. *J Drugs Dermatol*. 2007;6:641-645.
23. Oracea [package insert]. Fort Worth, TX: Galderma Laboratories LP; 2013.
24. Preshaw PM, Novak MJ, Mellonig J, et al. Modified-release subantimicrobial dose doxycycline enhances scaling and root planing in subjects with periodontal disease. *J Periodontol*. 2008;79:440-452.
25. Modi S, Harting M, Rosen T. Azithromycin as an alternative rosacea therapy when tetracyclines prove problematic. *J Drugs Dermatol*. 2008;7:898-899.
26. Park H, Del Rosso JQ. Use of oral isotretinoin in the management of rosacea. *J Clin Aesthet Dermatol*. 2011;4:54-61.
27. Korting HC, Schöllmann C. Tetracycline actions relevant to rosacea treatment [published online ahead of print September 25, 2009]. *Skin Pharmacol Physiol*. 2009;22:287-294.
28. Quarterman MJ, Johnson DW, Abele DC, et al. Ocular rosacea. signs, symptoms, and tear studies before and after treatment with doxycycline. *Arch Dermatol*. 1997;133:49-54.
29. Pfeffer I, Borelli C, Zierhut M, et al. Treatment of ocular rosacea with 40 mg doxycycline in a slow release form [in English, German][published online ahead of print June 15, 2011]. *J Dtsch Dermatol Ges*. 2011;9:904-907.
30. Bakar O, Demircay Z, Toker E, et al. Ocular signs, symptoms and tear function tests of papulopustular rosacea patients receiving azithromycin [published online ahead of print February 24, 2009]. *J Eur Acad Dermatol Venereol*. 2009;23:544-549.
31. Sapadin AN, Fleischmajer R. Tetracyclines: nonantibiotic properties and their clinical implications. *J Am Acad Dermatol*. 2006;54:258-265.
32. Webster G, Del Rosso JQ. Anti-inflammatory activity of tetracyclines. *Dermatol Clin*. 2007;25:122-135, v.
33. Golub LM, Lee HM, Ryan ME, et al. Tetracyclines inhibit connective tissue breakdown by multiple nonantimicrobial mechanisms. *Adv Derm Res*. 1998;12:12-26.
34. Del Rosso JQ. Update on rosacea pathogenesis and correlation with medical therapeutic agents. *Cutis*. 2006;78:97-100.
35. Del Rosso JQ, Bruce S, Jarratt M, et al. Efficacy of topical azelaic acid (AzA) gel 15% plus oral doxycycline 40 mg versus metronidazole gel 1% plus oral doxycycline 40 mg in mild-to-moderate papulopustular rosacea. *J Drugs Dermatol*. 2010;9:607-613.
36. Webster GF. An open-label, community-based, 12-week assessment of the effectiveness and safety of monotherapy with doxycycline 40 mg (30-mg immediate-release and 10-mg delayed-release beads). *Cutis*. 2010;86(suppl 5):7-15.
37. Del Rosso JQ. Effectiveness and safety of doxycycline 40 mg (30-mg immediate-release and 10-mg delayed-release beads) once daily as add-on therapy to existing topical regimens for the treatment of papulopustular rosacea: results from a community-based trial. *Cutis*. 2010;86(suppl 5):16-25.
38. Del Rosso JQ, Schlessinger J, Werschler P. Comparison of anti-inflammatory dose doxycycline versus doxycycline 100 mg in the treatment of rosacea. *J Drugs Dermatol*. 2008;7:573-576.
39. Thiboutot DM, Fleischer AB, Del Rosso JQ, et al. A multi-center study of topical azelaic acid 15% gel in combination with oral doxycycline as initial therapy and azelaic acid 15% gel as maintenance monotherapy. *J Drugs Dermatol*. 2009;8:639-648.
40. Fleischer A, Suephy C. The face and mind evaluation study: an examination of the efficacy of rosacea treatment using physician ratings and patients' self-reported quality of life. *J Drugs Dermatol*. 2005;4:585-590.
41. Jackson JM, Kircik LH, Lorenz DJ. Efficacy of extended-release 45 mg oral minocycline and extended-release 45 mg oral minocycline plus 15% azelaic acid in the treatment of acne rosacea. *J Drugs Dermatol*. 2013;12:292-298.
42. Del Rosso JQ, Baldwin H, Webster G; American Acne & Rosacea Society. American Acne & Rosacea Society rosacea medical management guidelines. *J Drugs Dermatol*. 2008;7:531-533.
43. Cribier B. Pathophysiology of rosacea: redness, telangiectasia, and rosacea. *Ann Dermatol Venereol*. 2011;138(suppl 3):S184-S191.
44. Yamasaki K, Kanada K, Macleod DT, et al. TLR2 expression is increased in rosacea and stimulates enhanced serine protease production by keratinocytes [published online ahead of print November 25, 2010]. *J Invest Dermatol*. 2011;131:688-697.
45. Meyer-Hoffert U, Schröder JM. Epidermal proteases in the pathogenesis of rosacea. *J Invest Dermatol Symp Proc*. 2011;15:16-23.
46. Gerber PA, Buhren BA, Steinhoff M, et al. Rosacea: the cytokine and chemokine network. *J Invest Dermatol Symp Proc*. 2011;15:40-47.
47. Schwab VD, Sulk M, Seeliger S, et al. Neurovascular and neuroimmune aspects in the pathophysiology of rosacea. *J Invest Dermatol Symp Proc*. 2011;15:53-62.
48. Sulk M, Seeliger S, Aubert J, et al. Distribution and expression of non-neuronal transient receptor potential (TRPV) ion channels in rosacea [published online ahead

- of print December 22, 2011]. *J Invest Dermatol*. 2012;132:1253-1262.
49. Del Rosso JQ, Gallo RL, Kircik L, et al. Why is rosacea considered to be an inflammatory disorder? the primary role, clinical relevance, and therapeutic correlations of abnormal innate immune response in rosacea-prone skin. *J Drugs Dermatol*. 2012;11:694-700.
  50. Kanada KN, Nakatsuji T, Gallo RL. Doxycycline indirectly inhibits proteolytic activation of tryptic kallikrein-related peptidases and activation of cathelicidin [published online ahead of print February 16, 2012]. *J Invest Dermatol*. 2012;132:1435-1442.
  51. McKeage K, Deeks ED. Doxycycline 40 mg capsules (30 mg immediate-release/10 mg delayed-release beads): anti-inflammatory dose in rosacea. *Am J Clin Dermatol*. 2010;11:217-222.
  52. Thiboutot D. Efficacy and safety of subantimicrobial-dose doxycycline for the treatment of rosacea. Poster presented at: 63rd Annual Meeting of the American Academy of Dermatology; February 18-22, 2005; New Orleans, LA. P128.
  53. Sanchez J, Somolinos AL, Almodóvar PI, et al. A randomized, double-blind, placebo-controlled trial of the combined effect of doxycycline hyclate 20-mg tablets and metronidazole 0.75% topical lotion in the treatment of rosacea [published online ahead of print September 15, 2005]. *J Am Acad Dermatol*. 2005;53:791-797.
  54. Theobald K, Bradshaw M, Leyden J. Anti-inflammatory dose doxycycline (40 mg controlled-release) confers maximum anti-inflammatory efficacy in rosacea. *Skinmed*. 2007;6:221-226.
  55. Thomas J, Walker C, Bradshaw M. Long-term use of subantimicrobial dose doxycycline does not lead to changes in antimicrobial susceptibility. *J Periodontol*. 2000;71:1472-1483.
  56. Skidmore R, Kovach R, Walker C, et al. Effects of subantimicrobial-dose doxycycline in the treatment of moderate acne. *Arch Dermatol*. 2003;139:459-464.
  57. Golub LM, Sorsa T, Lee HM, et al. Doxycycline inhibits neutrophil (PMN)-type matrix metalloproteinases in human adult periodontitis gingiva. *J Clin Periodontol*. 1995;22:100-109.
  58. Golub LM, Ramamurthy NS, McNamara TF, et al. Tetracyclines inhibit connective tissue breakdown: new therapeutic implications for an old family of drugs. *Crit Rev Oral Biol Med*. 1991;2:297-321.
  59. Hanemaaijer R, Visser H, Koolwijk P, et al. Inhibition of MMP synthesis by doxycycline and chemically modified tetracyclines (CMTs) in human endothelial cells. *Adv Dent Res*. 1998;12:114-118.
  60. Webster GF, Toso SM, Hegemann L. Inhibition of a model of in vitro granuloma formation by tetracyclines and ciprofloxacin. involvement of protein kinase C. *Arch Dermatol*. 1994;130:748-752.
  61. Amin AR, Attur MG, Thakker GD, et al. A novel mechanism of action of tetracyclines: effects on nitric oxide synthases. *Proc Natl Acad Sci USA*. 1996;93:14014-14019.
  62. Valentín S, Morales A, Sánchez JL, et al. Safety and efficacy of doxycycline in the treatment of rosacea. *Clin Cosmet Investig Dermatol*. 2009;2:129-140.
  63. Bhatia ND, Del Rosso JQ. Optimal management of papulopustular rosacea: rationale for combination therapy. *J Drugs Dermatol*. 2012;11:838-44.
  64. Kim S, Michaels BD, Kim GK, et al. Systemic antibacterial agents. In: Wolverson SE, ed. *Comprehensive Dermatologic Therapy*. 3rd ed. Philadelphia, PA: Elsevier Saunders; 2013:61-97.
  65. Del Rosso JQ. Patterns of use of topical and oral therapies in the treatment of different subtypes of rosacea. Presented at: 11th Annual South Beach Symposium; April 11-15, 2013; Miami Beach, Florida.
  66. Leyden JJ, Del Rosso JQ. Oral antibiotic therapy for acne vulgaris: pharmacokinetic and pharmacodynamic perspectives. *J Clin Aesthet Dermatol*. 2011;4:40-47.
  67. Smilack JD. The tetracyclines. *Mayo Clin Proc*. 1999;74:727-729.
  68. Stockley IH. Antibiotics and anti-infective agents. In: Stockley IH, eds. *Drug Interactions*. 5th ed. London, England: Pharmaceutical Press; 1999:196-197.
  69. Leyden JJ. Absorption of minocycline hydrochloride and tetracycline hydrochloride. effect of food, milk, and iron. *J Am Acad Dermatol*. 1985;12(2, pt 1):308-312.
  70. Layton AM, Cunliffe WJ. Phototoxic eruptions due to doxycycline—a dose-related phenomenon. *Clin Exp Dermatol*. 1993;18:425-427.
  71. Smith K, Leyden JJ. Safety of doxycycline and minocycline: a systematic review. *Clin Ther*. 2005;27:1329-1342.
  72. Sloan B, Scheinfeld N. The use and safety of doxycycline hyclate and other second-generation tetracyclines. *Expert Opin Drug Saf*. 2008;7:571-577.
  73. Del Rosso JQ. Systemic therapy for rosacea: focus on oral antibiotic therapy and safety. *Cutis*. 2000;66(suppl 4):7-13.
  74. Truchuelo-Díez MT, Alcántara J, Carrillo R, et al. Demodicosis successfully treated with repeated doses of oral ivermectin and permethrin cream. *Eur J Dermatol*. 2011;21:777-778.
  75. Forstinger C, Kittler H, Binder M. Treatment of rosacea-like demodicosis with oral ivermectin and topical permethrin cream. *J Am Acad Dermatol*. 1999;41(5, pt 1):775-777.
  76. Pierog SH, Al-Salihi FL, Cinotti D. Pseudotumor cerebri—a complication of tetracycline treatment of acne. *J Adolesc Health Care*. 1986;7:139-140.
  77. Berger RS. A double-blind, multiple-dose, placebo-controlled, cross-over study to compare the incidence of gastrointestinal complaints in healthy subjects given Doryx R and Vibramycin R. *J Clin Pharmacol*. 1988;28:367-370.
  78. Akhyani M, Ehsani AH, Ghiasi M, et al. Comparison of efficacy of azithromycin vs. doxycycline in the treatment of rosacea: a randomized open clinical trial. *Int J Dermatol*. 2008;47:284-288.

79. Bakar O, Demirçay Z, Gürbüz O. Therapeutic potential of azithromycin in rosacea. *Int J Dermatol*. 2004;43:151-154.
80. Fernandez-Obregon A. Oral use of azithromycin for the treatment of acne rosacea. *Arch Dermatol*. 2004;140:489-490.
81. Torresani C, Pavesi A, Manara GC. Clarithromycin versus doxycycline in the treatment of rosacea. *Int J Dermatol*. 1997;36:942-946.
82. Tamaoki J, Kadota J, Takizawa H. Clinical implications of the immunomodulatory effects of macrolides. *Am J Med*. 2004;117(suppl 9A):5S-11S.
83. Amsden GW. Anti-inflammatory effects of macrolides—an underappreciated benefit in the treatment of community-acquired respiratory tract infections and chronic inflammatory pulmonary conditions [published online ahead of print December 8, 2004]. *J Antimicrob Chemother*. 2005;55:10-21.
84. Bakar O, Demirçay Z, Yuksel M, et al. The effect of azithromycin on reactive oxygen species in rosacea [published online ahead of print January 18, 2007]. *Clin Exp Dermatol*. 2007;32(2):197-200.
85. Coda AB, Hata T, Miller J, et al. Cathelicidin, kallikrein 5, and serine protease activity is inhibited during treatment of rosacea with azelaic acid 15% gel [published online ahead of print July 18, 2013]. *J Am Acad Dermatol*. 2013;69:570-577.
86. Leyden JJ, Del Rosso JQ, Webster GF. Clinical considerations in the treatment of acne vulgaris and other inflammatory skin disorders: focus on antibiotic resistance. *Cutis*. 2007;79(suppl 6):9-25.
87. Gollnick H, Blume-Peytavi U, Szabó EL, et al. Systemic isotretinoin in the treatment of rosacea—doxycycline- and placebo-controlled, randomized clinical study [in English, German][published online ahead of print March 12, 2010]. *J Dtsch Dermatol Ges*. 2010;8:505-515.
88. Hofer T. Continuous ‘microdose’ isotretinoin in adult recalcitrant rosacea. *Clin Exp Dermatol*. 2004;29:204-205.
89. Pinheiro SP, Kang EM, Kim CY, et al. Concomitant use of isotretinoin and contraceptives before and after iPLEDGE in the United States [published online ahead of print August 3, 2013]. *Pharmacoepidemiol Drug Saf*. 2013;22:1251-1257.
90. Jansen T, Plewig G. Clinical and histologic variants of rosacea, including nonsurgical treatment modalities. *Facial Plast Surg*. 1998;14:241-253.
91. Solodyn [package insert]. Scottsdale, AZ: Medicis, a Division of Valeant Pharmaceuticals; 2011.
92. Doryx [package insert]. Rockaway, NJ: Warner Chilcott, LLC; 2013.