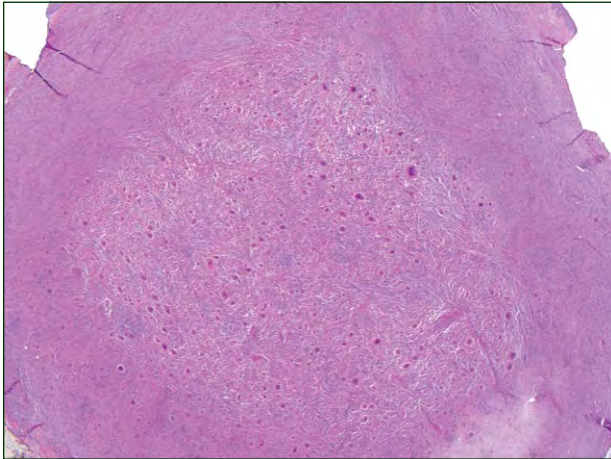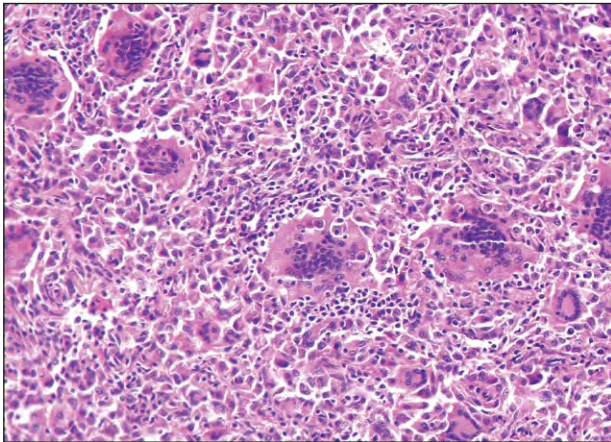


H&E, original magnification $\times 25$.



H&E, original magnification $\times 200$.

The best diagnosis is:

- a. atypical fibroxanthoma
- b. dermatofibroma
- c. giant cell tumor of soft tissue
- d. juvenile xanthogranuloma
- e. solitary reticulohistiocytoma

PLEASE TURN TO PAGE 286 FOR DERMATOPATHOLOGY DIAGNOSIS DISCUSSION

Scott C. Bresler, MD, PhD; Karolyn A. Wanat, MD; Rosalie Elenitsas, MD

Dr. Bresler was from the Perelman School of Medicine, University of Pennsylvania, Philadelphia, and currently is from the Department of Pathology, Brigham and Women's Hospital and Harvard Medical School, Boston, Massachusetts. Dr. Wanat was from and Dr. Elenitsas is from the Dermatopathology Division, Department of Dermatology, Hospital of the University of Pennsylvania. Dr. Wanat currently is from the Departments of Dermatology and Pathology, University of Iowa, Iowa City.

The authors report no conflict of interest.

Correspondence: Scott C. Bresler, MD, PhD, Department of Pathology, Brigham and Women's Hospital, 75 Francis St, Boston, MA 02115 (sbresler@partners.org).

Giant Cell Tumor of Soft Tissue

Giant cell tumors of soft tissue (GCTSTs) are uncommon tumors with low malignant potential. The majority of lesions are benign, and metastasis is rare. Giant cell tumors of soft tissue present as multilobulated masses in the skin or subcutaneous tissue, most commonly appearing on the trunk, upper extremities, and proximal aspect of the lower extremities. Similar to giant cell tumors of bone, GCTSTs grossly appear as brown, well-circumscribed, fleshy masses that microscopically consist of large multinucleated giant cells in a background of spindle cells and histiocytes (Figure 1).¹

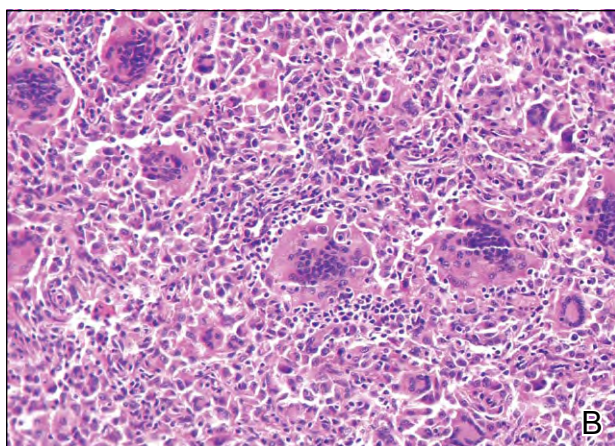
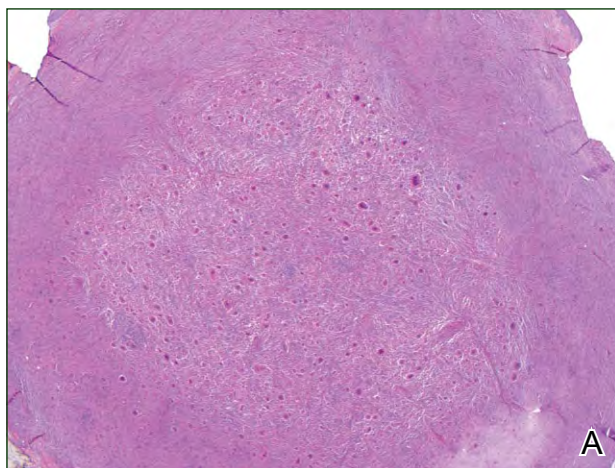


Figure 1. A highly cellular, well-circumscribed giant cell tumor of soft tissue with a considerable number of giant cells within its central region (A)(H&E, original magnification $\times 25$). At higher power, osteoclastlike giant cells with scalloped borders and many nuclei surrounded by histiocyte-like cells with multiple nuclei and a population of spindle cells can be seen (B)(H&E, original magnification $\times 200$).

Extravasated red blood cells and hemosiderin are common findings. Mitotic figures also can be present, but necrosis and cellular atypia are not characteristic of this lesion. Malignant giant cell tumors of soft parts usually are found in deep soft tissues and are distinguished from GCTSTs by their larger size and the presence of necrosis and cellular atypia. It remains unclear if they represent 2 ends of a spectrum or if they are distinct entities.²

The differential diagnosis of a GCTST includes other entities with giant cells. Different types of giant cells exist in neoplastic and inflammatory lesions, including Touton giant cells, foreign body giant cells, and osteoclastlike giant cells, among others. The presence of these types of cells may help in identifying the lesion but are not specific for diagnosis.² Giant cell tumors of soft tissue contain osteoclastlike giant cells, which often have scalloped borders and can contain up to 100 nuclei.³

Atypical fibroxanthomas are low-grade malignant tumors that also can contain osteoclastlike giant cells; however, they tend to occur more superficially than GCTSTs, often presenting in the dermis. Similar to squamous cell carcinomas, they often occur in sun-damaged areas in older patients. However, unlike squamous cell carcinoma, adjacent solar keratosis usually is not apparent.⁴ Histologically, atypical fibroxanthomas are densely cellular with giant, spindle, and histiocytoid cells; abnormal mitotic figures; and a heterogeneous inflammatory infiltrate (Figure 2).^{2,5} Immunohistochemistry generally

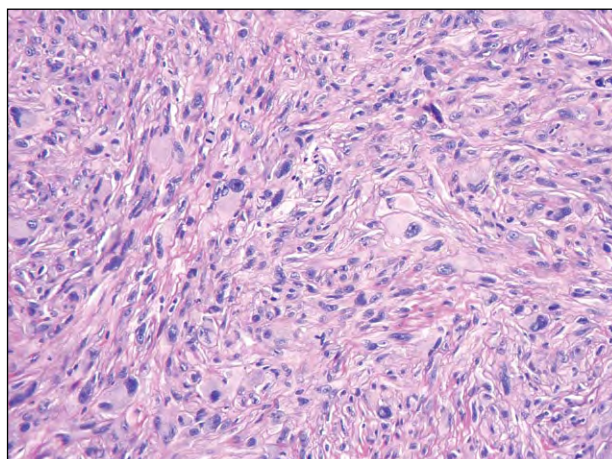


Figure 2. A highly cellular atypical fibroxanthoma with multinucleated cells and abnormal mitotic figures. Histiocyte-like cells with conspicuous nucleoli and spindle cells also can be seen (H&E, original magnification $\times 200$).

is necessary to exclude other malignant spindle cell tumors.

Touton giant cells, which contain a wreathlike arrangement of nuclei² at the periphery with surrounding foamy and eosinophilic cytoplasm, commonly are found in juvenile xanthogranulomas (Figure 3). This lesion type is more commonly found in children, though it also can occur in adults. The characteristic clinical presentation is an orange-pink papule found on the head, neck, or trunk. Typically found in the dermis, juvenile xanthogranulomas contain a heterogeneous population of cells with lymphocytes, foamy macrophages, eosinophils, and occasional Touton giant cells.⁶ Touton giant cells, despite being a classic finding, are not necessary for diagnosis.²

Dermatofibromas may contain all 3 types of giant cells. Lesions typically are slow-growing, brown to pink, indurated nodules that often are found on the arms and legs. Histopathologically, dermatofibromas consist of an admixture of fibroblastlike spindle cells and histiocytes that may demonstrate the various giant cell types (Figure 4). Epidermal hyperplasia often is present superficial to the lesion,⁷ and collagen trapping often is present at the lesion periphery, characterized by spindle cells wrapping around collagen bundles.² Variable numbers of blood vessels and other inflammatory cells also can be present.

Solitary reticulohistiocytomas, also known as solitary epithelioid histiocytomas, are thought to be reactive lesions,⁸ often presenting as a nonspecific papule anywhere on the body. The histopathologic appearance of solitary reticulohistiocytomas consists of sheets of epithelioid histiocytes with glassy pink cytoplasm, some with multiple (typically 2–3 but up to 10) randomly oriented nuclei (Figure 5).⁸ Various

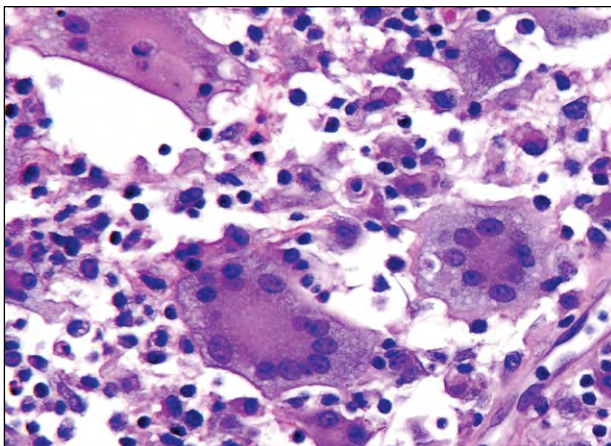


Figure 3. Juvenile xanthogranuloma demonstrating classic wreathlike Touton giant cells in a mixed background that includes lymphocytes and eosinophils (H&E, original magnification $\times 400$).

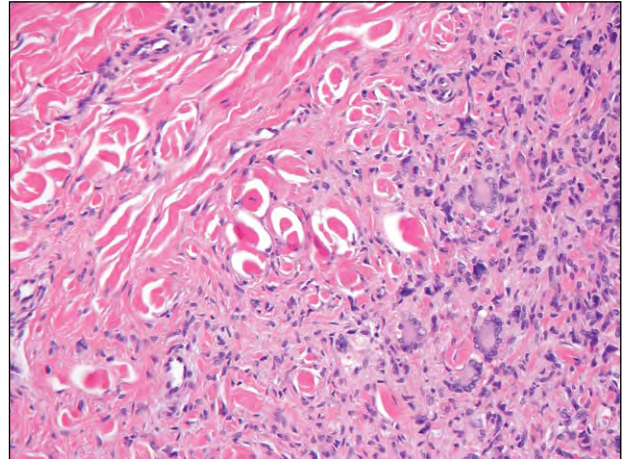


Figure 4. Dermatofibroma with dense collagen bundles among Touton giant cells and spindle cells (H&E, original magnification $\times 200$).

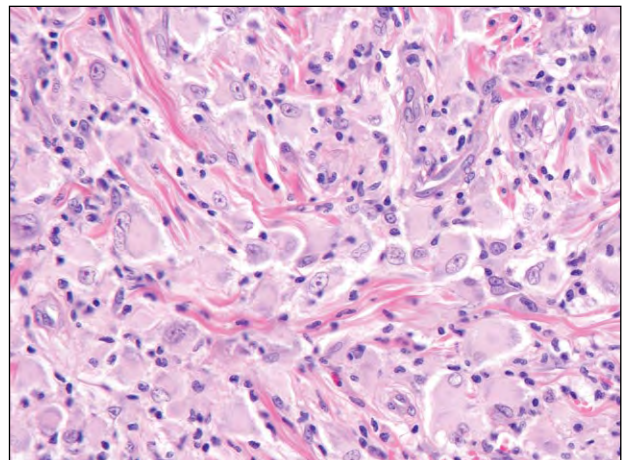


Figure 5. Solitary reticulohistiocytoma demonstrating histiocytes, some of them multinucleated, with glassy pink cytoplasm (H&E, original magnification $\times 400$).

other inflammatory cells also may present, including lymphocytes and granulocytes; solitary reticulohistiocytomas classically do not contain osteoclastlike or Touton giant cells.⁸ Histologically, these solitary lesions, which are not associated with systemic disease, are nearly identical to those of multicentric reticulohistiocytosis, which often is associated with mutilating arthritis and underlying malignancy.⁹

REFERENCES

1. Holst VA, Elenitsas R. Primary giant cell tumor of soft tissue. *J Cutan Pathol.* 2001;28:492-495.
2. Gómez-Mateo Mdel C, Monteagudo C. Nonepithelial skin tumors with multinucleated giant cells. *Semin Diagn Pathol.* 2013;30:58-72.

3. Guccion JG, Enzinger FM. Malignant giant cell tumor of soft parts: an analysis of 32 cases. *Cancer*. 1972;29:1518-1529.
4. Mirza B, Weedon D. Atypical fibroxanthoma: a clinicopathological study of 89 cases. *Australas J Dermatol*. 2005;46:235-238.
5. Luzar B, Calonje E. Morphological and immunohistochemical characteristics of atypical fibroxanthoma with a special emphasis on potential diagnostic pitfalls: a review. *J Cutan Pathol*. 2010;37:301-309.
6. Kraus MD, Haley JC, Ruiz R, et al. "Juvenile" xanthogranuloma: an immunophenotypic study with a reappraisal of histogenesis. *Am J Dermatopathol*. 2001;23:104-111.
7. Luzar B, Calonje E. Cutaneous fibrohistiocytic tumours—an update. *Histopathology*. 2010;56:148-165.
8. Miettinen M, Fetsch JF. Reticulohistiocytoma (solitary epithelioid histiocytoma): a clinicopathologic and immunohistochemical study of 44 cases. *Am J Surg Pathol*. 2006;30:521-528.
9. Fett N, Liu RH. Multicentric reticulohistiocytosis with dermatomyositis-like features: a more common disease presentation than previously thought. *Dermatology*. 2011;222:102-108.