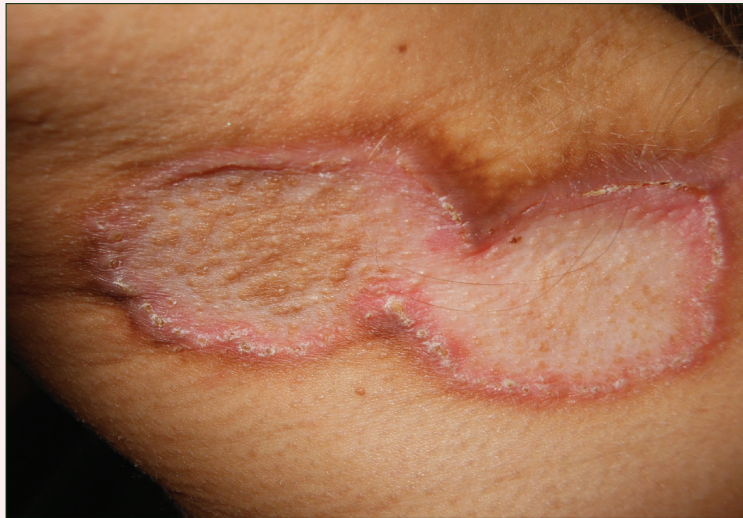

Asymptomatic Annular Plaques on the Neck

What's the diagnosis?



A 27-year-old woman was referred to our clinic with asymptomatic plaques on the neck of 1 year's duration. The patient reported that the annular plaque started as individual nummular lesions that subsequently coalesced. Her medical history included systemic sclerosis since 11 years of age. The patient's systemic sclerosis had involved the esophagus, small bowel, and heart, requiring placement of a defibrillator.

She was initially treated with hydroxychloroquine and then was placed on D-penicillamine for the last 10 years. Examination of the right side of the lateral neck revealed a 2×5-cm atrophic annular plaque with raised borders, and several 1.5-cm scaly, atrophic, nummular plaques were noted on the left side of the lateral neck. Other cutaneous manifestations included diffuse calcinosis cutis, sclerodactyly, and Raynaud phenomenon. A 4-mm punch biopsy of a raised margin of the annular plaque was performed.

Indy S. Chabra, MD, PhD; Lisa Maria Grandinetti, MD

From the Department of Dermatology, University of Pittsburgh, Pennsylvania.
The authors report no conflict of interest.

Correspondence: Lisa Maria Grandinetti, MD, University of Pittsburgh, Department of Dermatology, 200 Lothrop St, Medical Arts Bldg, 5th Floor, Pittsburgh, PA 15213 (grandinettilm@upmc.edu).

The Diagnosis: D-Penicillamine–Induced Elastosis Perforans Serpiginosa

A 27-year-old woman was referred to our clinic by her rheumatologist with a 2×5-cm annular plaque on the right side of the lateral neck along with nummular plaques on the left side of 1 year's duration (Figure 1). Her medical history was notable for systemic sclerosis that had been treated with oral D-penicillamine (750 mg daily) for the last 10 years. Histopathologic examination of the skin biopsy specimen revealed an epidermis with perforating channels of elastic fibers admixed with collagen (Figure 2). Verhoeff–van Gieson elastin stain highlighted “bramble bush or lumpy-bumpy” appearance of elastic fibers in the dermis (Figure 3), which confirmed the diagnosis of D-penicillamine–induced elastosis perforans serpiginosa (EPS).

Elastosis perforans serpiginosa is a rare entity that may present in many different settings. Some associated genetic conditions include Down syndrome, pseudo-xanthoma elasticum, Marfan syndrome, Ehlers-Danlos syndrome, acrogeria, osteogenesis imperfecta, Rothmund-Thomson syndrome, and moyamoya disease. Elastosis perforans serpiginosa also may be inherited in rare cases in an autosomal-dominant pattern.¹ There are solitary reports of EPS in the setting of renal disease, morphea, and systemic sclerosis. Most cases of EPS are iatrogenically acquired. As first reported in 1973, long-term D-penicillamine therapy for Wilson disease has been classically associated with the rare development of EPS.² Putative mechanisms include copper

chelation by D-penicillamine in the setting of altered copper homeostasis in Wilson disease and subsequent inhibition of elastic fiber cross-linking by copper-dependent lysyl oxidase. Another proposed mechanism is the direct inhibition of collagen cross-linking by D-penicillamine resulting in abnormal elastic fiber maturation.³ Outside of the context of Wilson disease, D-penicillamine–induced EPS also has developed during the treatment of juvenile rheumatoid arthritis and cystinuria.⁴ Our patient with systemic sclerosis also exemplifies the possibility of developing EPS from long-term D-penicillamine therapy even in the absence of coexisting Wilson disease.

Elastosis perforans serpiginosa lesions classically present as asymptomatic, serpiginously arranged, hyperkeratotic papules, nodules, and annular plaques in young adults and children. Lesions usually present on the neck, though other locations have been described. Histologically, transepidermal elimination

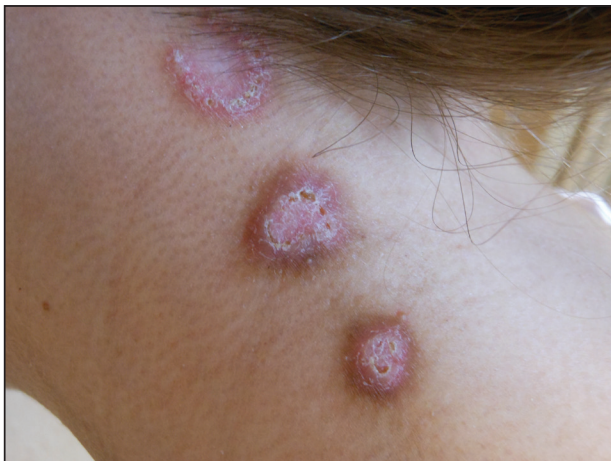

Figure 1. Nummular plaques on the left side of the lateral neck.

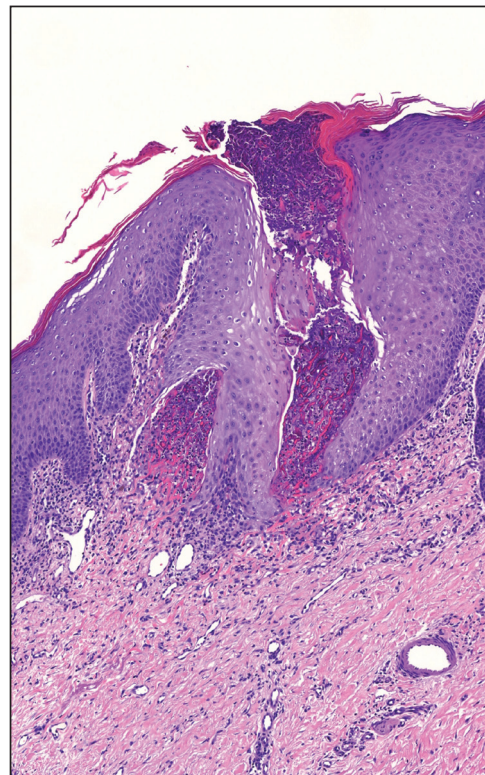


Figure 2. A punch biopsy specimen showed an epidermis with perforating channels of elastic fibers admixed with collagen (H&E, original magnification ×10).

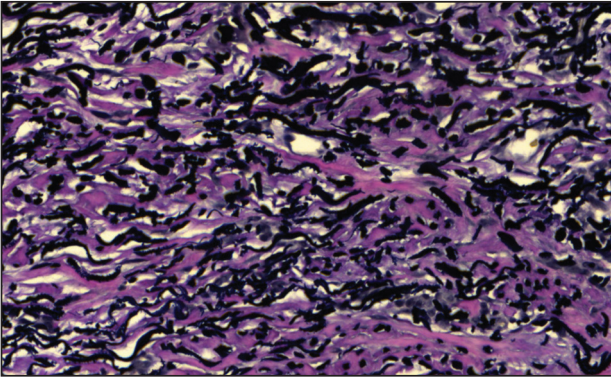


Figure 3. Verhoeff–van Gieson elastin stain highlighted “bramble bush or lumpy-bumpy” appearance of elastic fibers in the dermis (original magnification $\times 40$).

of elastic fibers, degenerated keratinocytes, and collagen is seen in the background of a foreign-body reaction with hematoxylin and eosin stain. Elastin stains show increased thickened elastic fibers in the dermis underlying the perforation. The histology of D-penicillamine–induced EPS is distinctive in that the elastic fibers are arranged in a bramble bush pattern with lateral buds.

The clinical course of D-penicillamine–induced EPS is variable, ranging from slow to no resolution

after drug discontinuation, with residual scarring, atrophy, and concern for systemic elastosis. Adjunctive therapies include oral and topical retinoids, cryotherapy, imiquimod, and CO₂ laser.⁵ For our patient, tazarotene gel 0.1% was recommended, but the patient became pregnant soon after the diagnosis was made. Despite being untreated, her lesions have remarkably improved during her pregnancy.

REFERENCES

1. Langeveld-Wildschut EG, Toonstra J, van Vloten WA, et al. Familial elastosis perforans serpiginosa. *Arch Dermatol.* 1993;129:205-207.
2. Pass F, Goldfischer S, Sternlieb I, et al. Elastosis perforans serpiginosa during penicillamine therapy for Wilson disease. *Arch Dermatol.* 1973;108:713-715.
3. Deguti MM, Mucenic M, Cancado EL, et al. Elastosis perforans serpiginosa secondary to D-penicillamine treatment in a Wilson's disease patient. *Am J Gastroenterol.* 2002;97:2153-2154.
4. Sahn EE, Maize JC, Garen PD, et al. D-penicillamine–induced elastosis perforans serpiginosa in a child with juvenile rheumatoid arthritis. report of a case and review of the literature. *J Am Acad Dermatol.* 1989;20:979-988.
5. Atzori L, Pinna AL, Pau M, et al. D-penicillamine elastosis perforans serpiginosa: description of two cases and review of the literature. *Dermatol Online J.* 2011;17:3.