

Late-Onset Nevus Comedonicus on Both Eyelids With Hypothyroidism

To the Editor:

A 62-year-old woman was referred to the dermatology clinic for papules on both eyelids of 6 months' duration. She underwent surgery for a thyroid gland adenoma 3 years prior and subsequently experienced hypothyroidism. Levothyroxine sodium was administered daily (100 µg initially; 50 µg over the last 1.5 years). Papules occurred on both eyelids 6 months prior to presentation and gradually increased in number. The center of each papule was filled with a black keratinous plug. The skin lesions became raised after the patient ate fatty foods. The lesions remained entirely asymptomatic and there was no family history of a similar disorder.

Physical examinations showed no systemic abnormalities. Dermatologic examination showed clustered 3- to 4-mm flesh-colored papules on both upper eyelids; the centers of the papules were filled with 1- to 2-mm black keratinous plugs (Figure 1A). Several similar skin lesions existed on the lower eyelids, nasal root, and right side of the nasal dorsum. On laboratory examination, the results of routine blood, urine, and stool tests, as well as renal and hepatic functions, electrolytes, and blood sugar levels, were within reference range. Indicators including triglyceride of 2.50 mmol/L (reference range, 0.40–1.90 mmol/L), total cholesterol of 6.31 mmol/L (reference range, 3.00–5.70 mmol/L), serum total thyroxine (T₄) of 5.32 µg/dL (reference range, 6.09–12.23 µg/dL), total triiodothyronine (T₃) of 64 ng/dL (reference range,

87–178 ng/dL), serum free thyroxine (FT₄) of 0.41 ng/dL (reference range, 0.61–1.12 ng/dL), serum free triiodothyronine (FT₃) of 182 pg/dL (reference range, 250–390 pg/dL), and thyrotropin of 33.75 µIU/mL (reference range, 0.34–5.60 µIU/mL) were not within reference range; however, thyroperoxidase antibodies, thyrotropin receptor antibodies, thyroglobulin antibodies, thyroglobulin,

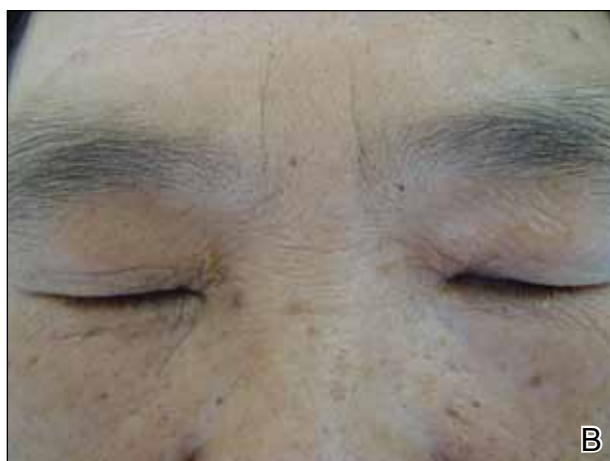
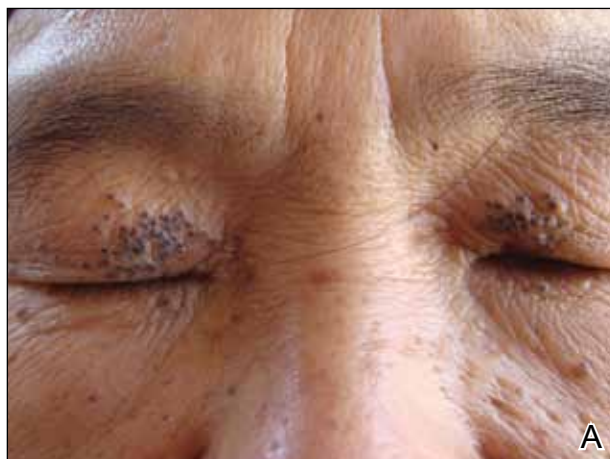
Figure 1. Clustered flesh-colored papules on both upper eyelids; the centers of the papules were filled with black keratinous plugs (A). Following treatment with levothyroxine sodium, most of the skin lesions had resolved (B).

Dr. Fan is from the Department of Dermatology, First People's Hospital of Changshu City, Changshu Hospital Affiliated to Soochow University, China. Dr. Zhang is from the Department of Dermatology, Traditional Chinese Medical Hospital of Changshu City. Dr. Song is from the Department of Dermatology, The First Hospital Affiliated to Soochow University, Suzhou, China. The authors report no conflict of interest.

Correspondence: Wenge Fan, MD, Department of Dermatology, First People's Hospital of Changshu City, Changshu Hospital Affiliated to Soochow University, Changshu 215500, Jiangsu Province, PR China (csyfwg@126.com).

and calcitonin were within reference range. Color ultrasonography indicated post-subtotal resection of the bilateral thyroid glands.

Histopathologic analysis of the skin lesions showed that the epidermis became atrophic and thinner, and several atrophic and cyst-dilated follicular structures existed inside the dermis. Some structures opened through the epidermis; the walls were squamous epithelium and keratin filled the structures (Figure 2). The condition was diagnosed as nevus comedonicus (NC).

The patient was referred to the endocrinology department and treated with levothyroxine sodium (100 µg daily). At 5-month follow-up, the T_4 , T_3 , FT_4 , FT_3 , and thyrotropin levels were within reference range and most of the skin lesions had resolved (Figure 1B).

Nevus comedonicus is an unusual skin lesion with a predilection for the face, neck, shoulders, upper arms, and trunk. The clinical manifestations include comedonelike papules with centers that are characterized by large, black, solid keratinous plugs. When the plugs are peeled off, volcanic craterlike pits will be left. The skin lesions usually are ribbonlike and clustered on 1 side of the body. Pathologic examination often shows that the epidermis is pitted downward, and the dilated follicular ostia are plugged with keratin.^{1,2} Paige and Mendelson³ divided NC into 2 types: inflammatory and noninflammatory. Approximately half of NC patients experience cysts, abscesses, fistulae, and scars.⁴

The exact etiology of NC is unclear. Some researchers believe that it is a congenital hair follicle deformity; more specifically, that it is caused by a developmental defect in the hair follicles in the embryonic stage (ie, abnormal differentiation of epithelial stem cells that differentiate into follicles). Most incidences of NC occur at birth or before growth and development. However, few studies have reported late-onset NC.⁵

The relationship between NC and thyroid disease is unique. Clinical research has shown that hypothyroidism can result in hair loss and cracks.⁶ In animal experiments, hypothyroidism model mice often experienced degenerative changes of their hair follicles and hair papillae as well as changes in the telogen phase, such as thinning of the outer and inner root sheaths.⁷ Meanwhile, decreased cell proliferation activity in the hair follicles was observed. Therefore, it is reasonable to conclude that thyroid hormones have regulatory effects on the growth and development of hair follicles.⁷

A study on human hair follicles found that thyroid hormone receptor β_1 is expressed in human hair follicles.⁸ Research on in vitro-cultured human

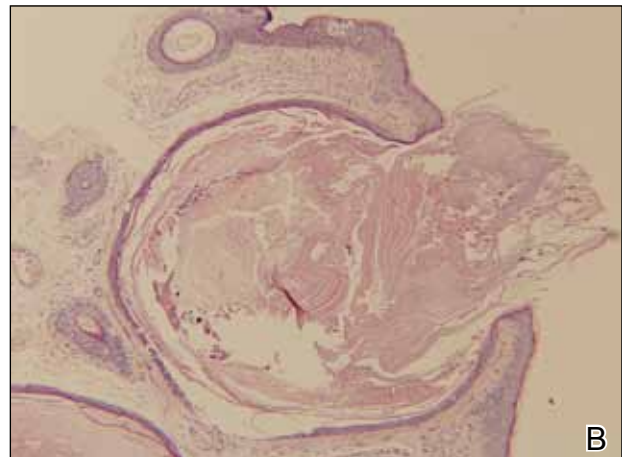
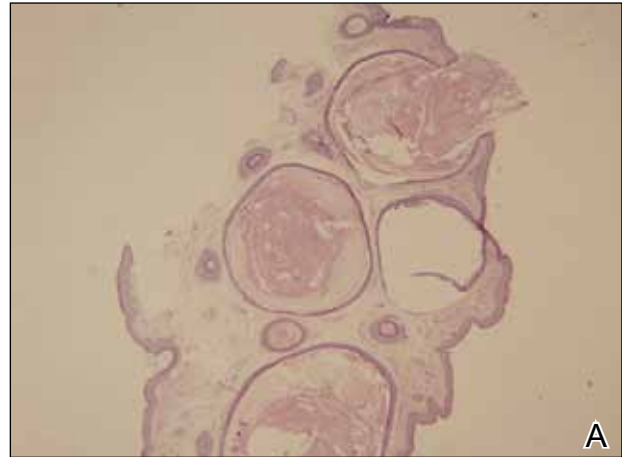


Figure 2. Several atrophic and cyst-dilated follicular structures existed inside the dermis. Some of them opened through the epidermis and were filled with keratin (A and B)(both H&E, original magnifications $\times 4$ and $\times 10$).

hair follicles showed that thyroid hormones T_3 and T_4 upregulated the proliferation of hair matrix cells and downregulated their apoptosis. Thyroid hormones also prolonged the duration of the hair growth phase (anagen).⁹ Furthermore, expression of thyrotropin receptor was detected in human hair follicles. Because increased serum thyrotropin levels can lead to clinical hair loss, thyrotropin may inhibit the growth of hair follicles via thyrotropin receptor.¹⁰ In our patient, NC occurred on both eyelids when the patient experienced hypothyroidism following thyroid gland adenoma surgery. Following treatment with levothyroxine sodium, the T_4 , T_3 , FT_4 , FT_3 , and thyrotropin levels were within reference range and most of the skin lesions resolved. Therefore, the occurrence of NC may be related

to hypothyroidism in this patient. The low thyroid hormone levels and elevated thyrotropin level possibly induced degenerative changes and injuries to the hair matrix cells, resulting in hair follicle obstruction and accumulation of keratin, which ultimately led to NC. However, the exact relationship between NC and thyroid diseases requires elucidation in future studies.

Wenge Fan, MD
Qingsong Zhang, MD
Linyi Song, MD

REFERENCES

1. Engber PB. The nevus comedonicus syndrome: a case report with emphasis on associated internal manifestations. *Int J Dermatol*. 1978;17:745-749.
2. Kirtak N, Inaloz HS, Karakok M, et al. Extensive inflammatory nevus comedonicus involving half of the body. *Int J Dermatol*. 2004;43:434-436.
3. Paige TN, Mendelson CG. Bilateral nevus comedonicus. *Arch Dermatol*. 1967;96:172-175.
4. James WD, Berger TG, Elston DM. *Andrews' Diseases of the Skin: Clinical Dermatology*. 10th ed. Philadelphia, PA: WB Saunders; 2006.
5. Ahn SY, Oh Y, Bak H, et al. Co-occurrence of nevus comedonicus with accessory breast tissue. *Int J Dermatol*. 2008;47:530-531.
6. Freinkel RK, Freinkel N. Hair growth and alopecia in hypothyroidism. *Arch Dermatol*. 1972;106:349-352.
7. Tsujio M, Yoshioka K, Satoh M, et al. Skin morphology of thyroidectomized rats. *Vet Pathol*. 2008;45:505-511.
8. Billoni N, Buan B, Gautier B, et al. Thyroid hormone receptor β 1 is expressed in the human hair follicle. *Br J Dermatol*. 2000;142:645-652.
9. van Beek N, Bodó E, Kromminga A, et al. Thyroid hormones directly alter human hair follicle functions: anagen prolongation and stimulation of both hair matrix keratinocyte proliferation and hair pigmentation. *J Clin Endocrinol Metab*. 2008;93:4381-4388.
10. Bodó E, Kromminga A, Bíró T, et al. Human female hair follicles are a direct, nonclassical target for thyroid-stimulating hormone. *J Invest Dermatol*. 2009;129:1126-1139.