

## THE CLINICAL PICTURE

**LAURA MIGUEL-GÓMEZ, MD**

Department of Dermatology, Ramón y Cajal Hospital, Madrid, Spain

**SERGIO VAÑÓ-GALVÁN, MD, PhD**

Department of Dermatology, Ramón y Cajal Hospital, Madrid, Spain

**BASIL SIDO-AHMED, MD**

Department of Dermatology, Ramón y Cajal Hospital, Madrid, Spain

**CARMEN MORENO GARCÍA DEL REAL, MD, PhD**

Department of Pathological Anatomy, Ramón y Cajal Hospital, Madrid, Spain

**PEDRO JAÉN-OLASOLO, MD, PhD**

Department of Dermatology, Ramón y Cajal Hospital, Madrid, Spain

# Sarcoidal infiltration of tattoos

**A** 42-YEAR-OLD WOMAN presented with painless lesions on her eyebrows that had been progressively growing for the past 3 months. Inspection and palpation revealed reddish papules and nodules on both eyebrows (FIGURE 1) and on the lips. The remainder of the physical examination was normal.

The patient said she had undergone cosmetic tattooing of her eyebrows and lips 10 years previously. She had no other significant medical history.

Her complete blood cell count and biochemistry and immunologic test panels were normal except for a high angiotensin-converting enzyme level.

Suspecting that the lesions represented sarcoidal infiltration of the tattoos, we obtained a biopsy. Histopathologic study showed multiple dermal noncaseating granulomas of epithelioid cells, together with polarizable foreign material and pigmented granules (FIGURE 2).

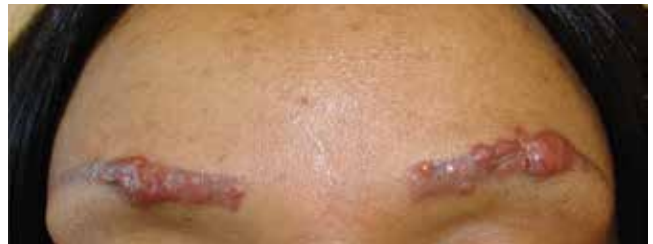Thoracic multislice computed tomography revealed multiple areas of lymphadenopathy in the mediastinum and both lung hila, with a perilymphatic micronodular interstitial pattern and with thickened and nodular bronchial walls (FIGURE 3). The patient's condition was diagnosed as systemic sarcoidosis presenting as sarcoidal infiltration of the tattooed areas.

Treatment with oral prednisone 20 mg daily and monthly intralesional injections of triamcinolone 12 ng/mL in the eyebrows and lips resulted in clinical improvement after 3 months (FIGURE 4).

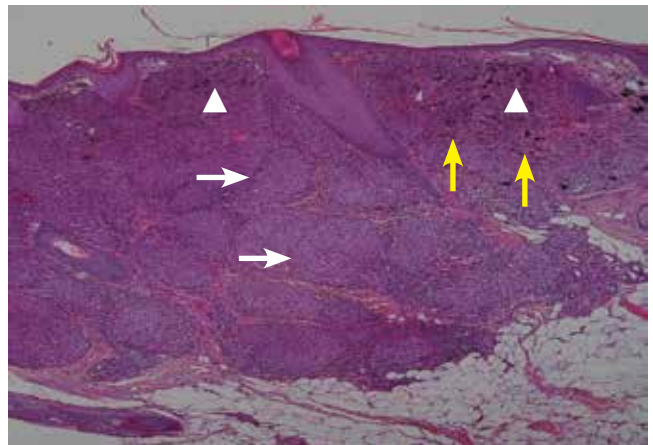
## CUTANEOUS SARCOIDOSIS

Sarcoidosis is a multisystemic granulomatous disease characterized by hyperactivity of the cellular immune system. It usually appears between ages 25 and 35 and is more severe in African Americans.<sup>1</sup> About one-third of patients with systemic sarcoidosis develop cutaneous lesions, and these may be the first sign of this disease.

Specific cutaneous lesions contain noncaseating granulomas. They manifest as reddish-brown papules,



**FIGURE 1.** The patient had reddish papules and nodules on the eyebrows as well as on the lips. These areas had undergone cosmetic tattooing 10 years earlier.

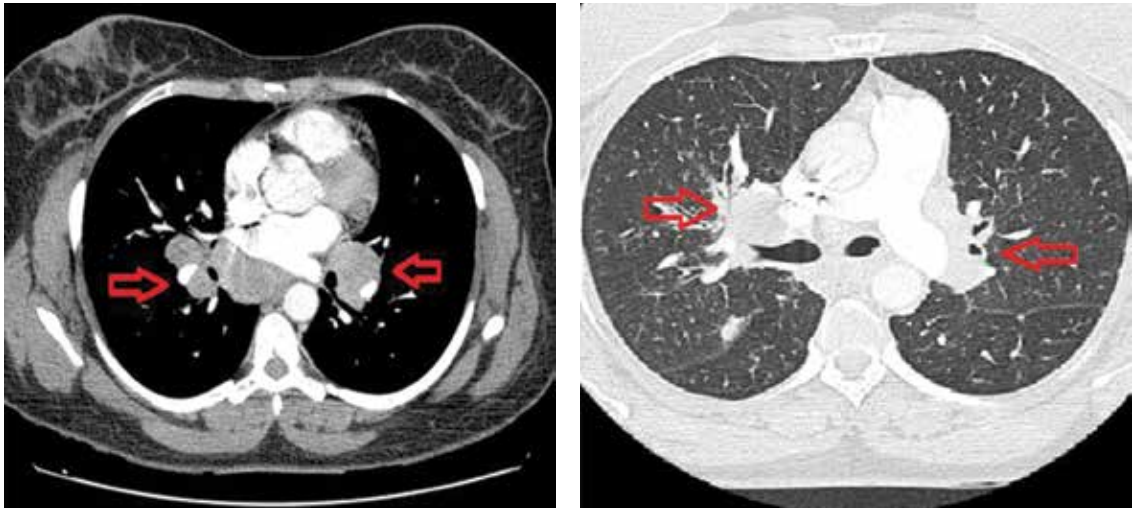


**FIGURE 2.** Dermal noncaseating granulomas of epithelioid cells were seen (white arrows), with polarizable foreign material (yellow arrows) and pigment granules (arrowheads) (hematoxylin and eosin, x 10).

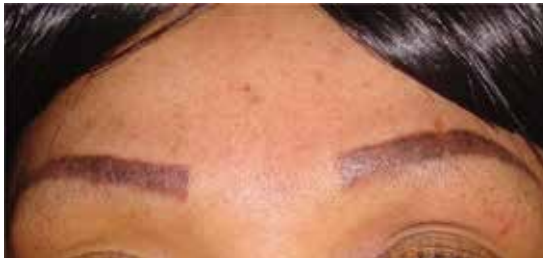plaques, and macules and may appear over scars and tattoos.<sup>2,3</sup> Other, nonspecific manifestations include erythema nodosum, erythema multiforme, nail clubbing, and Sweet syndrome.<sup>4</sup>

Diascopy and dermoscopy may be useful in diagnosing cutaneous sarcoidosis. The lesions typically have a characteristic yellowish-brown (“apple-jelly”) color.<sup>5</sup>

Sarcoidosis is a diagnosis of exclusion. It is suspected clinically, and histologic, radiologic, and analytical tests are indicated. Laboratory evaluation may show



**FIGURE 3.** Computed tomography without contrast (left) shows multiple areas of lymphadenopathy in the mediastinum and lung hila (red arrows). The “lung window” view (right) shows a perilymphatic micronodular interstitial pattern, with thickened and nodular bronchial walls; the red arrows indicate areas of hilar lymphadenopathy.



**FIGURE 4.** After treatment.

an elevated serum angiotensin-converting enzyme level, but this finding alone is not sensi-

tive enough to be useful for diagnosis.<sup>6</sup>

The treatment and prognosis of skin sarcoidosis depend on the degree of systemic involvement. Localized cutaneous lesions can respond to intralesional corticosteroid injections and tacrolimus 0.1% ointment.<sup>7</sup> However, if there is systemic involvement, low-dose prednisolone and weekly methotrexate should be started. This combination has few adverse effects.<sup>8</sup> Recently, improvement of cutaneous and systemic sarcoidosis has been observed with agents that block tumor necrosis factor alpha.<sup>4</sup> ■

**Corticosteroid treatment resulted in improvement in 3 months**

■ **REFERENCES**

1. English JC 3rd, Patel PJ, Greer KE. Sarcoidosis. *J Am Acad Dermatol* 2001; 44:725–743.
2. Antonovich DD, Callen JP. Development of sarcoidosis in cosmetic tattoos. *Arch Dermatol* 2005; 141:869–872.
3. Anolik R, Mandal R, Franks AG Jr. Sarcoidal tattoo granuloma. *Dermatol Online J* 2010; 16:19.
4. Su Ö, Onsun N, Topukçu B, Özçelik HK, Çakıter AU, Büyükpınarbaşı N. Disseminated scar sarcoidosis may predict pulmonary involvement in sarcoidosis. *Acta Dermatovenerol Alp Pannonica Adriat* 2013; 22:71–74.
5. Hunt RD, Gonzalez ME, Robinson M, Meehan SA, Franks AG Jr. Ulcerative sarcoidosis. *Dermatol Online J* 2012; 18:29.

6. Baughman RP, Culver DA, Judson MA. A concise review of pulmonary sarcoidosis. *Am J Respir Crit Care Med* 2011; 183:573–581.
7. Landers MC, Skokan M, Law S, Storrs FJ. Cutaneous and pulmonary sarcoidosis in association with tattoos. *Cutis* 2005; 75:44–48.
8. Nagai S, Yokomatsu T, Tanizawa K, et al. Treatment with methotrexate and low-dose corticosteroids in sarcoidosis patients with cardiac lesions. *Intern Med* 2014; 53:427–433.

**ADDRESS:** Laura Miguel-Gómez, MD, Department of Dermatology, Ramón y Cajal Hospital, Carretera de Colmenar Viejo km 9.1, 28034 Madrid, Spain; e-mail: lmg\_0007@hotmail.com