

Preface:

Sizing up the evolution of reconstructive pelvic surgery

Reconstructive pelvic surgery is undergoing an evolution from art to science. This evolution has been a gradual one, stemming from increasing knowledge about normal and altered anatomy as well as from technological advances in surgical materials and techniques. It also has been well timed, as the aging of our population has resulted in growing numbers of women presenting to gynecologists' offices with genital prolapse and urinary incontinence. This supplement aims to reflect this evolution in practical terms by updating readers on the currently prevailing concepts about pelvic floor anatomy and on new techniques for repair of the two most challenging areas of reconstructive surgery: the vaginal apex and the anterior vaginal wall.

Normal anatomic support of the pelvic floor structures is based on the delicate interrelationship between the bony skeleton, intact neuromuscular function, and adequate ligamentous and fibromuscular fascial support structures. It is on the two areas of the female pelvis most likely to be affected by weakness in support—the apex (due to torn support ligaments) and the anterior wall (due to deficient endopelvic fascia)—that this supplement will focus.

Anatomic dissections and radiologic imaging techniques have been invaluable in improving our understanding of the pathophysiology of prolapse. Surgical correction approaches have evolved through a series of steps beginning with traditional reparative techniques and progressing to the development of specific tools and minimally invasive techniques, the increased acceptance of synthetic and biologic grafts, and the subsequent development of surgical kits that are applicable to most patients with prolapse regardless of the site of support weakness (**Figure**).

This evolution of surgical approaches has been swift, owing primarily to technological advances in materials and techniques. As a result, new potential complications, such as graft-related healing difficul-

Evolution of reconstructive surgery

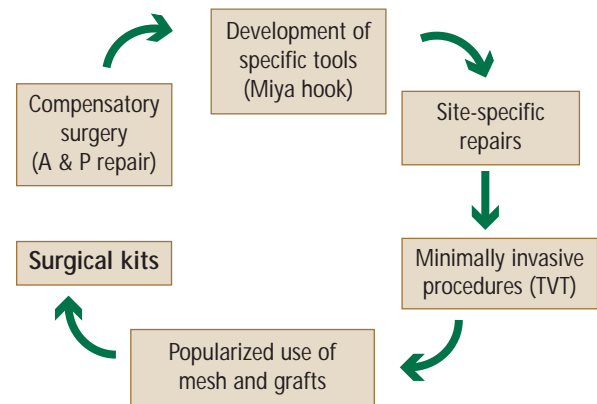


FIGURE. Schematic of the evolution of surgical techniques. A & P repair = anterior and posterior colporrhaphy; TVT = tension-free vaginal tape.

ties, have become apparent. Being prepared to address these complications is of great importance for the reconstructive surgeon in a referral practice. To that end, the final article in this supplement reviews accepted means of optimizing surgical outcomes, from both prophylactic and therapeutic perspectives.

Future progress in this field can be expected to lead to further innovation, with its associated benefits and drawbacks. Reconstructive surgeons should familiarize themselves with new techniques as they become available, and evaluate the utility of each with a critical, yet open, mind.

G. WILLY DAVILA, MD
Head, Section of Urogynecology
and Reconstructive Pelvic Surgery
Chairman, Department of Gynecology
Cleveland Clinic Florida
Weston, FL