

> **THE PATIENT**
33-year-old woman

> **SIGNS & SYMPTOMS**

- 6-day history of fever
- Groin pain and swelling
- Recent hiking trip in Colorado

Katherine Lazet, DO;
Stephanie Rutterbush,
MD

St. Vincent Ascension Health, Evansville, Ind (Dr. Lazet); Munson Healthcare Ostego Memorial Hospital, Lewiston, Mich (Dr. Rutterbush)

lazetkat@gmail.com

The authors reported no potential conflict of interest relevant to this article.

> THE CASE

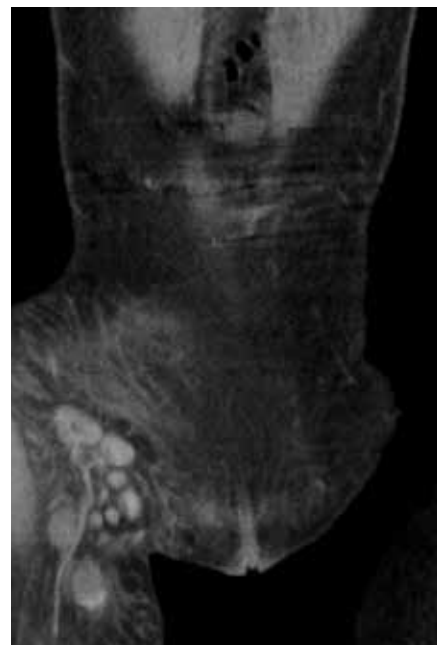A 33-year-old Caucasian woman presented to the emergency department with a 6-day history of fever (103°-104°F) and right groin pain and swelling. Associated symptoms included headache, diarrhea, malaise, weakness, nausea, cough, and anorexia. Upon presentation, she admitted to a recent hike on a bubonic plague–endemic trail in Colorado.

Her vital signs were unremarkable, and the physical examination demonstrated normal findings except for tender, erythematous, nonfluctuant right inguinal lymphadenopathy. The patient was admitted for intractable pain and fever and started on intravenous cefoxitin 2 g IV every 8 hours and oral doxycycline 100 mg every 12 hours for pelvic inflammatory disease vs tick- or flea-borne illness. Due to the patient's recent trip to a plague-infested area, our suspicion for *Yersinia pestis* infection was high.

The patient's work-up included a negative pregnancy test and urinalysis. A complete blood count demonstrated a white blood cell count of $8.6 (4.3-10.5) \times 10^3/\text{UL}$ with a 3+ left shift and a platelet count of $112 (180-500) \times 10^3/\text{UL}$. A complete metabolic panel showed hypokalemia and hyponatremia (potassium 2.8 [3.5-5.1] mmol/L and sodium 134 [137-145] mmol/L). Blood cultures were negative for any bacterial or fungal growth after 48 hours; stool cultures were negative for *Salmonella*, *Shigella*, *Campylobacter*, *Giardia*, generalized *Yersinia*, and *Escherichia coli* O157:H7. Swabs for *Gardnerella vaginalis*, *Trichomonas vaginalis*, *Candida*, *Chlamydia trachomatis*, and *Neisseria gonorrhoea* also were negative. Lyme, *Bartonella henselae*, and heterophile antibodies were also negative. *Francisella tularensis* was not cultured due to low suspicion.

■ **Imaging** included a normal chest x-ray and a computed tomography scan of the abdomen and pelvis that showed enlarged right inguinal lymph nodes with fatty stranding, a thicker distal right iliopsoas, hepatosplenomegaly, and an enlarged right adnexa (FIGURE 1). Initial ultrasound of the bubo

FIGURE 1
CT scan from admission was revealing



The patient's computed tomography scan showed enlarged right inguinal lymph nodes with fatty stranding.

IMAGES COURTESY OF: UP HEALTH SYSTEM MARQUETTE IMAGING DEPARTMENT

showed 2 enlarged suprapubic lymph nodes, the largest measuring $3.5 \times 1.4 \times 2.4 \text{ cm}^3$ (FIGURE 2), and 8 enlarged inguinal nodes.

The patient continued to have a low-grade fever, diarrhea, and inguinal lymphadenopathy throughout her first 2 hospitalized days. The cefoxitin was discontinued by Day 3, and the consulting infectious disease physician started oral metronidazole 500 mg every 12 hours due to the patient's failure to improve. Later that night, the patient experienced increasing erythema and pain in her right inguinal region. A repeat ultrasound showed increased inguinal lymphadenopathy with the largest nodes measuring $2.9 \times 1.5 \times 2.5 \text{ cm}^3$ and $2.7 \times 1.3 \times 2 \text{ cm}^3$ (FIGURE 3).

Although doxycycline is considered an acceptable regimen for *Y pestis* infection, the infectious disease physician added oral ciprofloxacin 750 mg every 12 hours the following morning, as the patient had not improved.

THE DIAGNOSIS

Although the initial gram stain was negative for *Yersinia*, clinical suspicion pointed to a diagnosis of bubonic plague. Serology was considered; however, it was not available through the hospital. A definitive diagnosis required bubo aspiration and culture, which was performed but required 48 hours before results would be available.

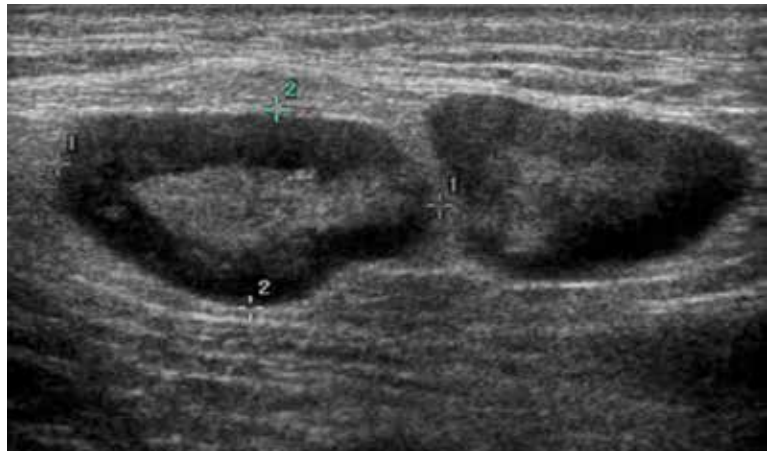
By Day 5, the patient was clinically improved and deemed safe for discharge on empiric treatment with ciprofloxacin 750 mg twice daily and doxycycline 100 mg twice daily to complete a 14-day course of antibiotic therapy for bubonic plague. The bubo culture subsequently grew *Y pestis*, confirming the diagnosis. The patient made a full recovery and was greatly improved when seen in the outpatient setting by the treating infectious disease physician. Outpatient ultrasound repeated 3 weeks after discharge showed borderline lymphadenopathy, no greater than 1 cm.

DISCUSSION

Between 2000 and 2009, there were 57 cases of *Y pestis* in the United States; in early 2015, 11 cases were found in 6 Western states.¹ The

FIGURE 2

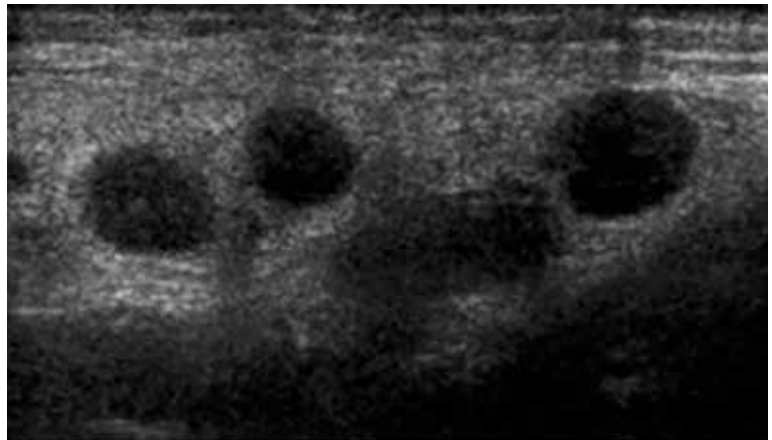
An ultrasound look at the lymph nodes



An initial ultrasound revealed 2 large suprapubic lymph nodes with the largest measuring $3.5 \times 1.4 \times 2.4 \text{ cm}^3$.

FIGURE 3

Repeat ultrasound showed an increasing number of enlarged inguinal lymph nodes



plague presents in the bubonic form 80% to 95% of the time, and it has never been reported in Michigan (where we treated this patient); however, there was a laboratory case in Illinois. Although rats were traditionally the host for *Y pestis*, the prairie dog, *Cynomys gunnisoni*, is a host in the United States.² Rodents are the most important hosts, but more than 200 mammalian species, including domestic pets, have had reported infections. Transmission is primarily via flea bites, but *Y pestis* also may be transmitted via respiratory

secretion, inhalation, or direct handling of contaminated animal tissues. Due to the risk of respiratory spread, the Centers for Disease Control and Prevention must be notified of a diagnosis.^{3,4}

Y pestis travels from the site of the flea bite to regional lymph nodes, where it reproduces, and the resultant inflammatory reaction creates buboes. The bacteria then circulate in the blood to other organs, although *Y pestis* bacteria are primarily removed by the liver and spleen. Patients often develop symptoms such as headache, fevers, chills, and gastrointestinal distress. Diagnosis is reached by bubo culture or rapid testing for the F1 antigen. Early intervention with antibiotics is crucial as untreated bubonic plague has a mortality rate of 50% to 90%.^{3,4}

■ **The differential diagnosis** for unilateral inguinal lymphadenopathy with associated constitutional symptoms was broad, in this case, and included pelvic inflammatory disease, bubonic plague, iliopsoas abscess, lymphogranuloma venereum, bartonellosis, infectious mononucleosis, and tick-borne diseases, such as ehrlichiosis, tularemia, Lyme disease, Rocky Mountain spotted fever, and Colorado tick fever.

■ **Treatment.** Food and Drug Administration-approved treatments include streptomycin (gentamicin 5 mg/kg/day IM or IV for 14 days is more widely utilized), doxycycline 200 mg PO once daily for 10 to 14 days, and fluoroquinolones (ciprofloxacin 500-750 mg every 12 hours for 10-14 days).

Trimethoprim-sulfamethoxazole may be used as an alternative, but limitations include potentially incomplete or slowed responses.

THE TAKEAWAY

This case points to the importance of a complete, systematic approach to each patient. While bubonic plague is not a diagnosis that would immediately come to mind in a patient visiting an emergency department in Michigan, a thorough history revealed a recent trip to a bubonic plague-endemic area. A thorough physical exam demonstrated unilateral painful inguinal adenopathy—which, when paired with the patient's history—was consistent with the uncommon diagnosis of bubonic plague.

JFP

ACKNOWLEDGEMENTS

The authors thank Brian Waite, MD, and James Addison, MD, for critically revising this report for important intellectual content.

CORRESPONDENCE

Katherine Lazet, DO, 3838 N First Avenue, Evansville, IN 47710; lazetkat@gmail.com

References

1. Kwit N, Nelson C, Kugeler K, et al. Human Plague - United States, 2015. *MMWR Morb Mortal Wkly Rep*. 2015;64:918-919.
2. Friggens MM, Parmenter RR, Boyden M, et al. Flea abundance, diversity, and plague in Gunnison's prairie dog (*Cynomys gunnisoni*) and their burrows in Montane grasslands in northern New Mexico. *J Wildl Dis*. 2010;46:356-367.
3. Mandell G, Bennett J, Dolin R. *Mandell, Douglas, and Bennett's Principles and Practice of Infectious Diseases*. 7th ed. Philadelphia, PA: Churchill Livingstone Elsevier; 2010:2943-2953.
4. Perry RD, Featherston JD. *Yersinia pestis* - etiologic agent of plague. *Clin Microbiol Rev*. 1997;10:35-66.

➤ Although the initial gram stain demonstrated no organisms, a subsequent bubo aspiration and culture grew *Y pestis*, confirming the diagnosis.

THE JOURNAL OF
FAMILY
PRACTICE

 Residents'
Rapid Review

Residents: Are you getting ready for your family medicine certification exam?

Then check out our monthly Residents' Rapid Review quizzes, featuring prep questions written by the faculty of the National Family Medicine Board Review course.

This month's questions can be found at www.mdedge.com/jfponline.