

CASE REPORT

> THE PATIENT

20-year-old male college basketball prospect

> SIGNS & SYMPTOMS

- Right wrist pain 4 days after falling on wrist while playing basketball
- Normal range of motion of wrist and hand
- Pain with active and passive wrist extension

Cole Bortz, BA; Morteza Khodaei, MD, MPH
Department of Molecular Biology and Biochemistry, Middlebury College, Vt (Mr. Bortz) and Division of Sports Medicine, Department of Family Medicine, University of Colorado School of Medicine, Denver (Dr. Khodaei)

Morteza.Khodaei@cuanschutz.edu

The authors reported no potential conflict of interest relevant to this article.

> THE CASE

A 20-year-old man presented to our family medicine clinic with right wrist pain 4 days after falling on his wrist and hand while playing basketball. He denied any other previous injury or trauma. The pain was unchanged since the injury occurred.

Examination demonstrated mild edema over the palmar and ulnar aspect of the patient's right wrist with no apparent ecchymosis. He had normal range of motion of his right wrist and hand. However, he experienced pain with active and passive wrist extension and ulnar deviation. There was significant tenderness in the palmar and ulnar aspects of his right wrist just distal to the ulnar styloid process.

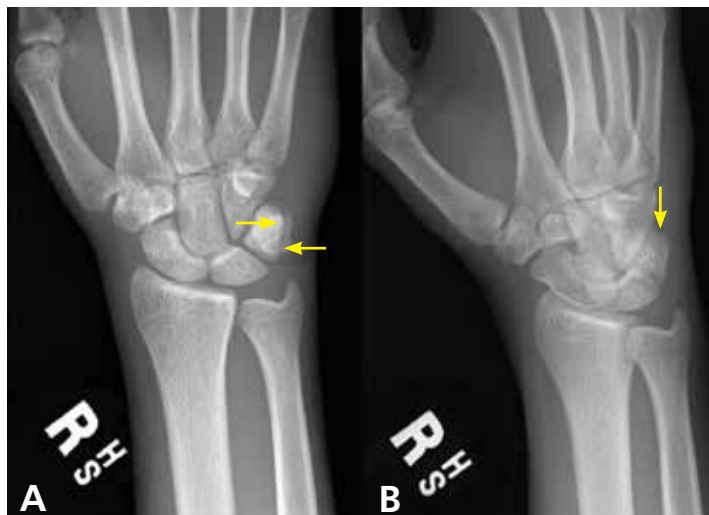THE DIAGNOSIS

Standard plain x-rays of the right wrist revealed an isolated fracture of the body of the triquetrum (FIGURE 1). Since the patient refused to have a cast placed, his wrist was immobilized with a wrist brace. By Day 16 post injury, the pain and edema had improved significantly. After talking with the patient about the potential risks and benefits of continuing to play basketball—and despite our recommendation that he not play—he decided to continue playing since he was a college basketball prospect.

At 4 weeks post injury, x-rays demonstrated mild interval healing (FIGURE 2). At the 8-week visit, the patient had only very mild pain and tenderness, and x-ray images showed improvement (FIGURE 3). Within a few months,

FIGURE 1

Isolated triquetrum body fracture



Anteroposterior (A) and oblique (B) x-ray views of the wrist on Day 4 after injury demonstrate a linear nondisplaced fracture of the triquetrum (arrows) with associated soft-tissue edema.

IMAGES COURTESY OF UNIVERSITY OF COLORADO, DENVER.

his symptoms resolved completely. No further imaging was performed.

DISCUSSION

In general, carpal fractures are uncommon.¹ The triquetrum is the second most commonly injured carpal bone, involved in up to 18% of all carpal fractures.^{2,3} Triquetrum fractures most commonly occur as isolated injuries and are typically classified in 2 general categories: avulsion fractures (dorsal cortex or volar cortex) and fractures of the triquetrum body.⁴⁻⁸ Isolated avulsion fractures of the triquetral dorsal cortex are relatively common, occurring in about 95% of triquetrum injuries.⁴⁻⁹ Isolated fractures of the triquetrum body are less common, occurring in about 4% of triquetrum injuries, and can go unnoticed on conventional x-rays.⁴⁻⁹

■ **Basketball presents a unique risk for hand or wrist fracture** due to its high-impact nature, hard playing surfaces, and frequent use of the hands for dribbling, shooting, rebounding, and passing the ball.

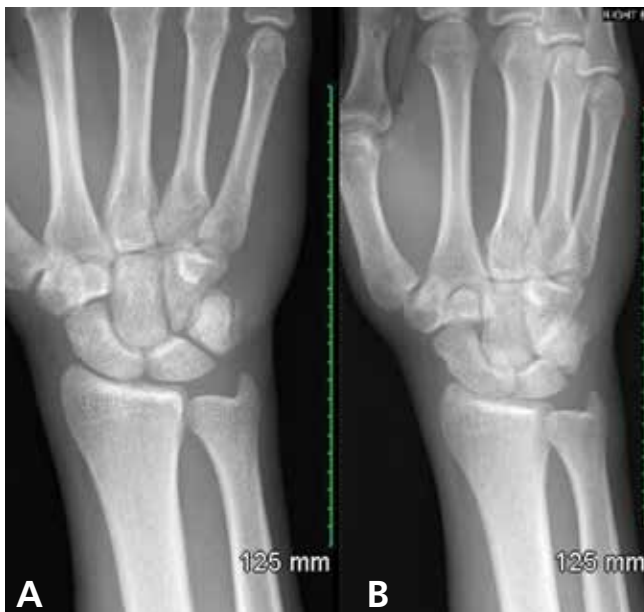In a retrospective study of sports-related fractures conducted at the Royal Infirmary of Edinburgh, basketball had the highest incidence of carpal injuries compared with other sports, including football, rugby, skiing, snowboarding, and ice-skating.⁴ Similarly, a retrospective study conducted at the University of California, Los Angeles, found that of all Division 1 collegiate athletes at the school, basketball players had the highest incidence of primary fractures, and the most common fracture location was the hand.¹⁰

An injury that's easy to miss

Because the incidence of hand and wrist injuries is high among basketball players, it is imperative that triquetrum body fractures are not missed or misdiagnosed as more common hand and wrist injuries, such as triquetral dorsal avulsion fractures.

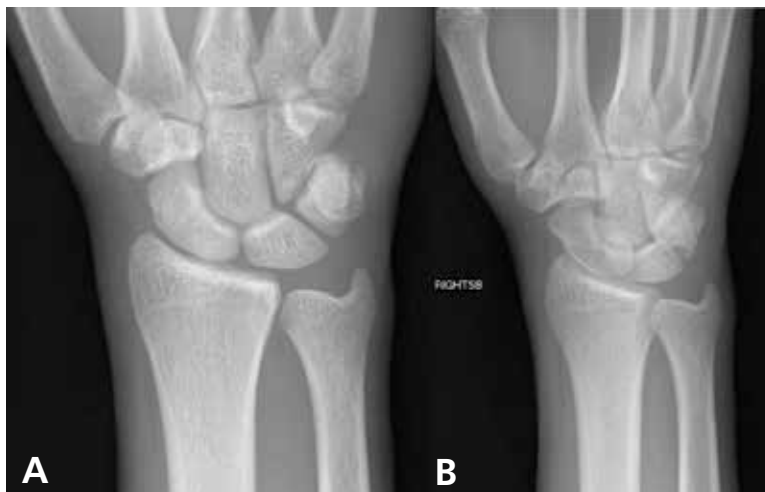■ **Our patient**, who had an isolated triquetrum body fracture, presented with focal tenderness on the palmar and ulnar aspects of his wrist and pain with ulnar deviation. Since triquetral body fractures often have a clinical presentation quite similar to that of

FIGURE 2
Healing at 4 weeks



Anteroposterior (A) and oblique (B) x-ray views of the wrist at Week 4 after injury demonstrate minimal interval healing of the longitudinal nondisplaced fracture of the triquetrum and resolution of the soft-tissue edema.

FIGURE 3
Continued healing at 8 weeks



Anteroposterior (A) and oblique (B) x-ray views of the wrist at Week 8 after injury demonstrate continued osseous healing of the longitudinal ulnar aspect of triquetral fracture. Fragments are in unchanged alignment.

triquetral dorsal avulsion fractures, patients presenting with symptoms of wrist tenderness and pain should be treated with a high degree of clinical suspicion.

CONTINUED

With our patient, anteroposterior and lateral x-rays were sufficient to demonstrate an isolated triquetrum body fracture; however, triquetral fractures can be missed in up to 20% of x-rays.⁴ Both magnetic resonance imaging and computerized tomography are useful in diagnosing occult triquetrum fractures and should be used to confirm clinical suspicion when traditional x-rays are inconclusive.^{11,12}

Management varies

Management of isolated triquetrum body fractures varies depending on the fracture pattern and the status of bone consolidation. Triquetral body fractures typically heal well; it's very rare that there is a nonunion. As our patient's fracture was nondisplaced and stable, brace immobilization for 4 weeks was sufficient to facilitate healing and restore long-term hand and wrist functionality. This course of treatment is consistent with other cases of nondisplaced triquetrum body fractures reported in the literature.¹³

■ **Long-term outcomes.** The literature is sparse regarding the long-term functional outcome of nonsurgical treatment for nondisplaced triquetrum body fractures. Multiple carpal fractures, displaced triquetrum body fractures, and persistent pain for multiple months after nonsurgical management all indicate the need for referral to orthopedic surgery. In instances of fracture displacement or nonunion, management tends to be surgical, with open reduction and internal fixation (ORIF) used in multiple cases of nonunion for isolated triquetrum body fractures.^{3,14} Any diagnostic imaging that reveals displacement, malunion, or nonunion of the fracture is an indication for referral to an orthopedic surgeon.

■ **Return to play.** There is no evidence-based return-to-play recommendation for patients with a triquetrum fracture. However, our patient continued to play basketball through the early stages of injury management because he was a collegiate prospect. While medical, social, and economic factors should be considered when discussing treatment options with athletes, injuries should be managed so that there is no long-term loss of

function or risk of injury exacerbation. When discussing early return from injury with athletes who have outside pressure to return to play, it's important to make them aware of the associated long- and short-term risks.¹⁵

THE TAKEAWAY

Management of an isolated triquetrum body fracture is typically straightforward; however, if the fracture is displaced, refer the patient to an orthopedic surgeon as ORIF may be required. For this reason, it's important to be able to promptly identify isolated triquetrum body fractures and to avoid confusing them with triquetrum dorsal avulsion fractures.

Depending on the sport played and the severity of the injury, athletes with conservatively managed nondisplaced triquetral body fractures may be candidates for early return to play. Nonetheless, athletes should understand both the short- and the long-term risks of playing with an injury, and they should never be advised to continue playing with an injury if it jeopardizes their well-being or the long-term functionality of the affected body part. **JFP**

CORRESPONDENCE

Morteza Khodaei, MD, MPH, University of Colorado School of Medicine, AFW Clinic, 3055 Roslyn Street, Denver, CO 80238; Morteza.Khodaei@cuanschutz.edu

REFERENCES

1. Suh N, Ek ET, Wolfe SW. Carpal fractures. *J Hand Surg Am.* 2014; 39:785-791.
2. Hey HW, Chong AK, Murphy D. Prevalence of carpal fracture in Singapore. *J Hand Surg Am.* 2011;36:278-283.
3. Al Rashid M, Rasoli S, Khan WS. Non-union of isolated displaced triquetral body fracture—a case report. *Ortop Traumatol Rehabil.* 2012;14:71-74.
4. Becce F, Theumann N, Bollmann C, et al. Dorsal fractures of the triquetrum: MRI findings with an emphasis on dorsal carpal ligament injuries. *AJR Am J Roentgenol.* 2013;200:608-617.
5. Court-Brown CM, Wood AM, Aitken S. The epidemiology of acute sports-related fractures in adults. *Injury.* 2008;39:1365-1372.
6. Urch EY, Lee SK. Carpal fractures other than scaphoid. *Clin Sports Med.* 2015;34:51-67.
7. deWeber K. Triquetrum fractures. UpToDate. 2016. www.uptodate.com/contents/triquetrum-fractures. Accessed September 3, 2019.
8. Höcker K, Menschik A. Chip fractures of the triquetrum. Mechanism, classification and results. *J Hand Surg Br.* 1994;19:584-588.
9. Jarraya M, Hayashi D, Roemer FW, et al. Radiographically occult and subtle fractures: a pictorial review. *Radiol Res Pract.* 2013;2013:370169.
10. Hame SL, LaFemina JM, McAllister DR, et al. Fractures in the collegiate athlete. *Am J Sports Med.* 2004;32:446-451.
11. Hindman BW, Kulik WJ, Lee G, et al. Occult fractures of the

CONTINUED ON PAGE 467

➤
Triquetral fractures can be missed in up to 20% of x-rays.

- George AK, Anil S. Acute herpetic gingivostomatitis associated with herpes simplex virus 2: report of a case. *J Int Oral Health*. 2014;6:99-102.
- Akintoye SO, Greenburg MS. Recurrent aphthous stomatitis. *Dent Clin N Am*. 2014;58:281-297.
- Scott LA, Stone MS. Viral exanthems. *Dermatol Online J*. 2003;9:4.
- Feller L, Wood NH, Khammissa RA, et al. Review: allergic contact stomatitis. *Oral Surg Oral Med Oral Pathol Oral Radiol*. 2017;123:559-565.

- Bascones-Martinez A, Munoz-Corcuera M, Bascones-Ilundain C, et al. Oral manifestations of pemphigus vulgaris: clinical presentation, differential diagnosis and management. *J Clin Exp Dermatol Res*. 2010;1:112.
- LeGoff J, Péré H, Bélec L. Diagnosis of genital herpes simplex virus infection in the clinical laboratory. *Viol J*. 2014;11:83.
- Centers for Disease Control and Prevention. Genital HSV infections. www.cdc.gov/std/tg2015/herpes.htm. Updated June 4, 2015. Accessed September 26, 2019.

CASE REPORT

CONTINUED FROM PAGE 464

carpals and metacarpals: demonstration by CT. *AJR Am J Roentgenol*. 1989;153:529-532.

- Pierre-Jerome C, Moncayo V, Albastaki U, et al. Multiple occult wrist bone injuries and joint effusions: prevalence and distribution on MRI. *Emerg Radiol*. 2010;17:179-184.
- Yildirim C, Akmaz I, Keklikçi K, et al. An unusual combined

fracture pattern of the triquetrum. *J Hand Surg Eur Vol*. 2008;33:385-386.

- Rasoli S, Ricks M, Packer G. Isolated displaced non-union of a triquetral body fracture: a case report. *J Med Case Rep*. 2012;6:54.
- Strickland JW. Considerations for the treatment of the injured athlete. *Clin Sports Med*. 1998;17:397-400.

LETTERS

Dismantling the opioid crisis

Dr. John Hickner's editorial, "Doing our part to dismantle the opioid crisis" (*J Fam Pract* 2019;68:308) had important inaccuracies.

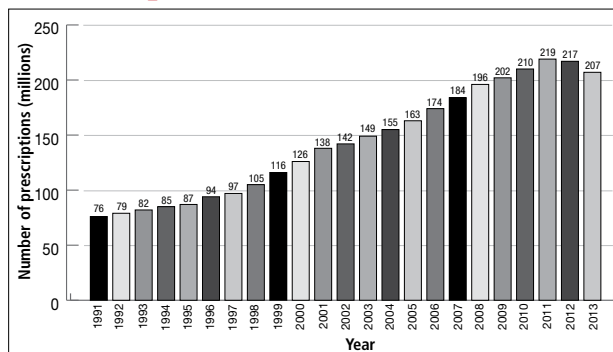
The Joint Commission, for which I serve as an executive vice president, did not "dub pain assessment the 'fifth vital sign.'" The concept of the fifth vital sign was developed by the American Pain Society in the 1990s.¹ It gained national attention through a Veterans Health Administration initiative in 1999.² And in 2001, the Joint Commission (then the Joint Commission on Accreditation of Healthcare Organizations or JCAHO) issued its Pain Standards.

Dr. Hickner wrote that the push to assess for pain as the fifth vital sign was a central cause of the opioid epidemic; however, this is contrary to published data on the epidemic. Total opioid prescriptions had been steadily increasing in the United States for at least a decade before the Pain Standards went into effect in 2001 (FIGURE).³ Between 1991 and 1997, the number of prescriptions increased from 76 million to 97 million. The rate of increase from 1997 to 2011 appears to have been more rapid, which is likely due to the 1995 approval of the new sustained-release opioid OxyContin and the associated aggressive marketing campaigns to physicians.

Your readers should know that we, at the Joint Commission, are also "doing our part to dismantle the opioid crisis." In 2016, we completely revised our Pain Standards, adding new criteria to help address the epidemic. Some

FIGURE

Opioid prescriptions dispensed by US retail pharmacies, 1991-2013³



adjustments include: requiring improved availability of nonpharmacologic therapy, encouraging engagement of patients in pain management plans, enhancing accessibility of Physician Drug Monitoring Program tools, and monitoring opioid prescribing.

David W. Baker, MD, FACP, executive vice president
The Joint Commission, Oakbrook Terrace, IL

References

- American Pain Society. *Principles of Analgesic Use in the Treatment of Acute Pain and Chronic Cancer Pain*. 2nd ed. Skokie, Illinois: American Pain Society; 1989.
- Department of Veteran's Affairs. Pain: the fifth vital sign. www.va.gov/PAINMANAGEMENT/docs/Pain_As_the_5th_Vital_Sign_Toolkit.pdf. Published October 2000. Accessed September 30, 2019.
- National Institute on Drug Abuse. America's addiction to opioids: heroin and prescription drug abuse. <https://archives.drugabuse.gov/testimonies/2014/americas-addiction-to-opioids-heroin-prescription-drug-abuse>. Published May 14, 2014. Accessed September 30, 2019.