



Infant with bilious emesis

Clinical findings and imaging studies revealed an additional cause for concern.

A 4-WEEK-OLD TERM BOY presented to the emergency department (ED) with recurrent bilious emesis. He had a history of neonatal abstinence syndrome, related to his mother's use of Subutex (a form of suboxone that is considered safer during pregnancy) for her opioid addiction, and a Ladd procedure at Day 7 of life for intestinal malrotation with volvulus. He had been discharged from the hospital 4 days earlier, after recovery from surgery.

He had been doing well until the prior evening, when he developed "yellow-green" emesis and appeared to have intermittent abdominal pain. His parents said that he was refusing to take formula and he'd had frequent bilious emesis. They also noted he'd had 1 wet diaper in the past 12 hours and appeared "sleepier" than usual.

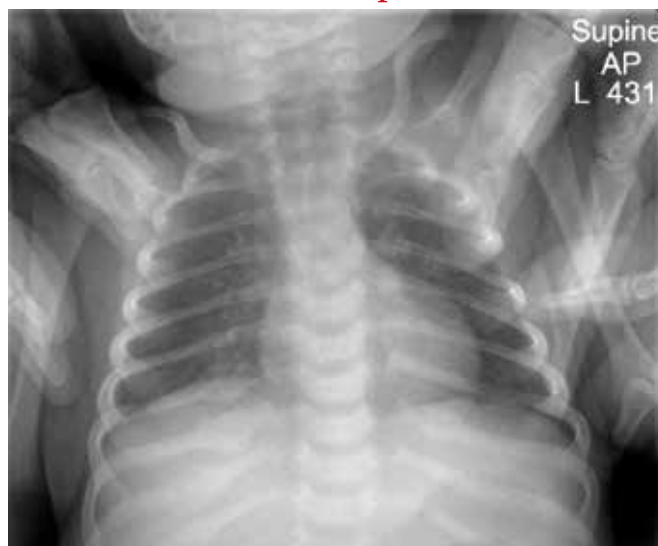In the ED, the patient was listless, with thin and tremulous extremities. His fontanelle was flat, and his pupils were equal, round, and reactive. His mucous membranes were dry, skin was mottled, and capillary refill was delayed. His cardiopulmonary exam was normal. His abdomen was soft, mildly distended, and diffusely tender to palpation, with well-healing laparotomy scars. His reflexes were normal, with slightly increased tone. No bruising was noted.

An acute abdominal series, including an AP view chest x-ray (FIGURE 1), was obtained to rule out recurrent volvulus, free air, or small bowel obstruction.

- WHAT IS YOUR DIAGNOSIS?
- HOW WOULD YOU TREAT THIS PATIENT?

FIGURE 1

AP chest x-ray of 4-week-old with bilious emesis and abdominal pain



Anne Huyler, MD; Anne Runkle, MD; Casey Z. MacVane, MD, MPH; Tania D. Strout, PhD, RN, MS
Maine Medical Center,
Portland, ME

ahuyler@mmc.org

DEPARTMENT EDITOR

Richard P. Usatine, MD
University of Texas Health
at San Antonio

The authors reported no potential conflict of interest relevant to this article.

Diagnosis: Nonaccidental trauma

The chest x-ray (FIGURE 1) showed multiple bilateral posterior rib fractures concerning for nonaccidental trauma (NAT). The remaining acute abdominal series films (not shown) revealed the reason for his bilious emesis: a partial bowel obstruction related to his surgical procedure. Review of x-rays obtained for peripherally inserted central catheter line confirmation during his previous admission (FIGURE 2) revealed that the rib fractures had been present at that time but had been overlooked.

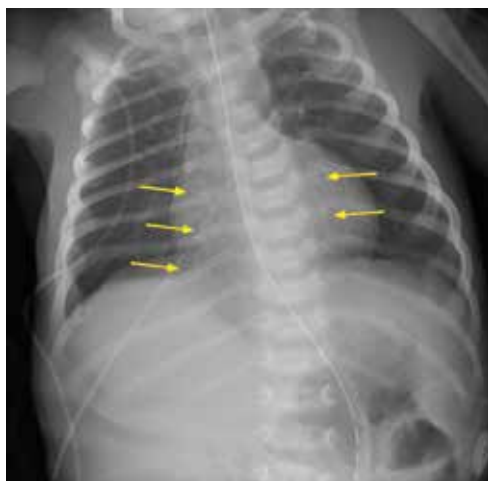
■ **This case illustrates the importance** of considering NAT in the differential diagnosis of any sick infant. There are an estimated 700,000 cases of child abuse and neglect and 600 fatalities per year in the United States.^{1,2} The differential diagnosis for fracture or bruising in infants includes accidental trauma, bony abnormalities (eg, osteogenesis imperfecta), bleeding disorders, and trauma from medical procedures such as CPR or surgery.¹

Ask these questions, look beyond that single bruise

When evaluating for NAT, the history and physical exam are crucial. It is essential to ask

FIGURE 2

Evidence that nonaccidental trauma had been overlooked



Review of x-rays obtained for peripherally inserted central catheter line placement during the patient's prior admission revealed that rib fractures had been present at that time, but had been overlooked.

if there were any witnesses, establish who was caring for the child, and investigate any delays in seeking medical evaluation.¹ During the exam, undress the child and examine every inch of skin, looking for bruising or abrasions, especially on the face, ear, neck, and oral cavity.

■ **Any bruising in a nonambulatory infant** should raise suspicion for NAT. One study showed that more than half of infants with a single bruise had additional injuries identified upon further work-up.³ Fundoscopic exam with photographs should be completed to evaluate for retinal hemorrhage.

Additional work-up should include a skeletal survey for all children younger than 24 months² in addition to computed tomography (CT) or magnetic resonance imaging of the head, complete blood count, and a coagulation panel. If there is concern for abdominal trauma, a complete metabolic panel and lipase test may be useful.⁴ If liver function tests show elevated liver enzymes (> 80 IU/L), abdominal CT with contrast is indicated.⁴

Research has underscored the importance of screening siblings and other contacts of abused children. In particular, the twin of an abused child has a much higher risk for abuse.⁵ A skeletal survey should be obtained in contacts (< 24 months) of abused children—regardless of their physical exam findings.⁵

Management depends on injury type

The management of children with NAT depends on the injuries. Once these injuries are addressed, the next step is to determine the safest place for the infant/child to be discharged. The involvement of local social workers and Child Protective Services (CPS) is pivotal for this determination.²

■ **Our patient.** To treat the partial small bowel obstruction noted on an abdominal CT, the patient received intravenous fluids and nasogastric tube decompression. However, due to ongoing distension and high nasogastric tube output, the patient was taken to the operating room for an exploratory laparotomy. An adhesive band in the right lower quadrant was found to be causing the obstruction and was lysed.

We consulted CPS and social workers about the rib fractures identified on x-ray. We considered osteogenesis imperfecta as a pos-

➤ One study showed that more than half of infants with a single bruise had additional injuries identified upon further work-up.

sible cause, but genetic testing was negative. The ophthalmology exam was negative for retinal hemorrhages. A bone scan confirmed posterior rib fractures with no other injuries. CPS was unable to confirm that the fractures had not been sustained while the child was an inpatient, so it was ultimately determined that the patient should be discharged home with his parents with supervision. **JFP**

CORRESPONDENCE

Anne Huyler, MD, Maine Medical Center, 22 Bramhall Street, Portland, ME 04102; ahuyler@mmc.org

References

1. Berkowitz CD. Physical abuse of children. *N Engl J Med.* 2017;376:1659-1666.
2. Lindberg DM, Berger RP, Reynolds MS, et al. Yield of skeletal survey by age in children referred to abuse specialists. *J Pediatr.* 2014;164:1268-1273.e1.
3. Harper NS, Feldman KW, Sugar NF, et al. Additional injuries in young infants with concern for abuse and apparently isolated bruises. *J Pediatr.* 2014;165:383-388.e1.
4. Lindberg DM, Shapiro RA, Blood EA, et al. Utility of hepatic transaminases in children with concern for abuse. *Pediatrics.* 2013;131:268-275.
5. Lindberg DM, Shapiro RA, Laskey AL, et al. Prevalence of abusive injuries in siblings and household contacts of physically abused children. *Pediatrics.* 2012;130:193-201.

Join the official job board of
THE JOURNAL OF
**FAMILY
PRACTICE**

 **MEDJOBNETWORK.com**
Physician • NP/PA Career Center

Search 1000s of Jobs and Apply in 1 Click
And get FREE benefits including...

- Access to 30+ medical web sites
- Medical news and clinical advice
- E-Alert and Newsletters on your smart phone
- Online CME and MD-IQ Quizzes
- Coverage of over 200 meetings
- And much more!

Julian Knight
Digital Sales Director, Classifieds
Phone: 973-206-2317
jknight@frontlinemedcom.com
www.medjobnetwork.com