

Deborah Paul, MD;
Art Papier, MD
University of Rochester
Dermatology Department,
NY

art_papier@urmc.
rochester.edu

Dr. Papier disclosed that he is the CEO and a shareholder of VisualDx. Dr. Paul reported no potential conflict of interest relevant to this article.

Scabies: Refine your exam, avoid these diagnostic pitfalls

Nearly half of all infections are missed when first examined. Attentiveness to specific details, particularly in 3 common scenarios, can help ensure an accurate Dx.

PRACTICE RECOMMENDATIONS

- › Consider scabies with any severe pruritic eruption. Conduct a thorough physical exam, preferably with a dermatoscope, for burrows in the webs and sides of fingers, proximal palm, and wrists. **(A)**
- › Consider scabies in all patients—especially the immunocompromised—who have distal white or yellow thick, scaly, or crusted plaques. **(C)**
- › Include scabies in the differential when patients present with smooth nodules of the genitals or pruritic smooth papules and plaques in other locations. **(A)**

Strength of recommendation (SOR)

- (A)** Good-quality patient-oriented evidence
- (B)** Inconsistent or limited-quality patient-oriented evidence
- (C)** Consensus, usual practice, opinion, disease-oriented evidence, case series

It is estimated that up to 45% of cases of scabies are misdiagnosed as another condition.¹ This can occur when common clinical features are overlooked, a skin exam is rushed (and the rash is chalked up to dermatitis), or the wrong part of the pruritic lesion is scraped (the papule, rather than the burrow). There are also atypical presentations of scabies, which can confound even the most astute clinician.¹ Misdiagnosis can increase health care costs due to repeat office visits or multiple referrals. In this article, we review the typical and atypical presentations of scabies and provide recommendations to aid physicians in its early recognition and correct diagnosis.

The scope of scabies infection, and its clinical stages

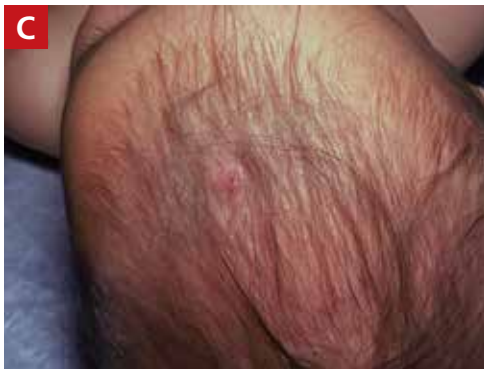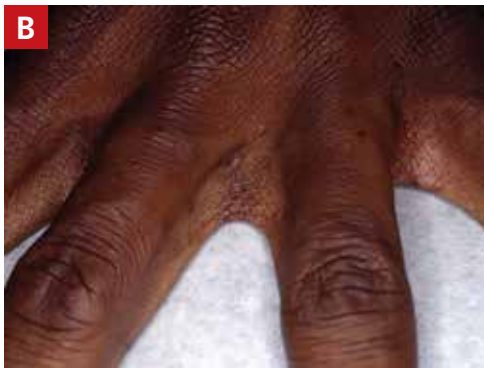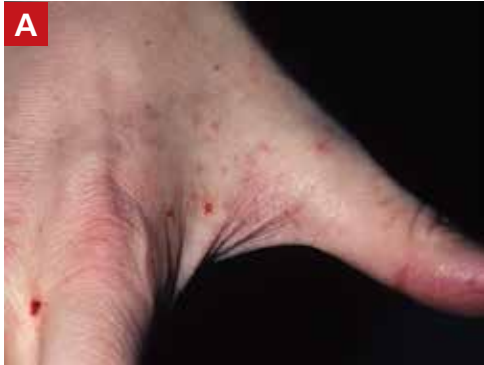The prevalence of scabies, a common skin infection caused by the mite *Sarcoptes scabiei*, is estimated at 300 million cases worldwide annually, with the greatest incidence occurring in children and adolescents.¹ In the developing world, its clinical burden is highest among the homeless, those of lower socioeconomic status, and those with poor hygiene. In the developed world, the clinical burden is highest among hospitalized patients and residents of long-term living facilities.

The *S scabiei* mite is an obligate parasite that elicits an adaptive immune response in susceptible hosts. The female mite lays 60 to 90 eggs that mature into adult mites after completing the mite life cycle in human hosts. In immunocompetent patients, roughly 10 to 15 surviving mites can be found at any given point in the disease process.² In crusted or disseminated scabies, which often occur in immunocompromised patients, thousands of mites may be found at any given point in the disease process.²

Scabies infection has 2 stages: the latent primary infection and the symptomatic secondary infection.

FIGURE 1

Classic scabies lesions on finger web space (A), dark skin (B), and infant's scalp (C)

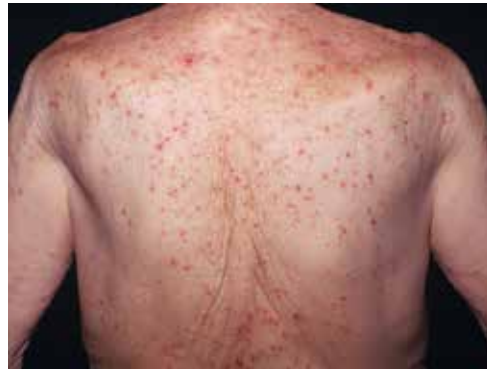

ALL IMAGES COURTESY OF VISUALDX.COM, FIGURE 8 COURTESY OF ROMAN BRONFENBRENER, MD

■ **The primary infection** starts with the initial mite invasion, typically with the transfer of impregnated females during person-to-person contact. Females deposit eggs as they burrow into the epidermis at the level of the stratum corneum with the use of proteolytic enzymes (creating the mite burrow). Surviving eggs hatch into larvae that then mature into nymphs and adult mites. After these adult mites mate, the impregnated fe-

FIGURE 2

Scabies lesions on a patient's back, which is usually spared



males create new burrows and lay additional eggs.³ Patients may be asymptomatic during this initial stage and the infection may be transmitted from person to person through direct skin contact.

■ **The second stage of infection** is when patients experience severe pruritus with inflammatory papules seen on exam. The pruritus associated with scabies results from a delayed type IV hypersensitivity reaction to mite infestation. This requires host sensitization to the scabies mite. Clinically, there is a delayed onset (weeks) of numerous erythematous papules and, later, excoriated papules.

Conditions that scabies can mimic

The differential of typical scabies includes diagnoses manifesting with moderate to severe pruritus. In the immunocompetent adult, conditions to consider are atopic dermatitis, tinea corporis, papular urticaria, seborrheic dermatitis, poison ivy and other causes of contact dermatitis, drug eruptions, and irritant dermatitis. In immunocompetent infants, think of seborrheic dermatitis, atopic dermatitis, acropustulosis, and viral exanthems.

Nodular scabies variants can masquerade as pseudolymphoma, lymphoma, or leukemia cutis. In immunocompromised and elderly individuals, crusted scabies is often mistaken for psoriasis, atopic dermatitis, keratoderma, and lichen planus.^{2,4,5}



In children with scabies, vesicles, pustules, and nodular pruritic lesions may coexist with eczema and impetigo.

CONTINUED

FIGURE 3
Nodular scabies in underarm

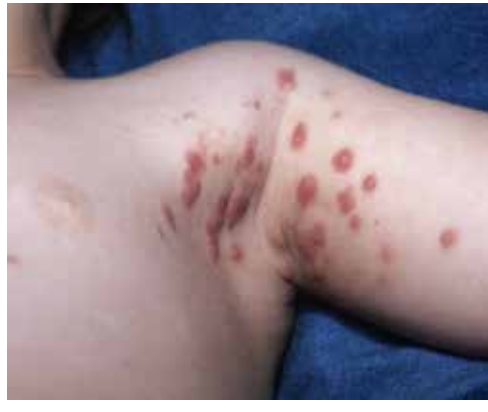
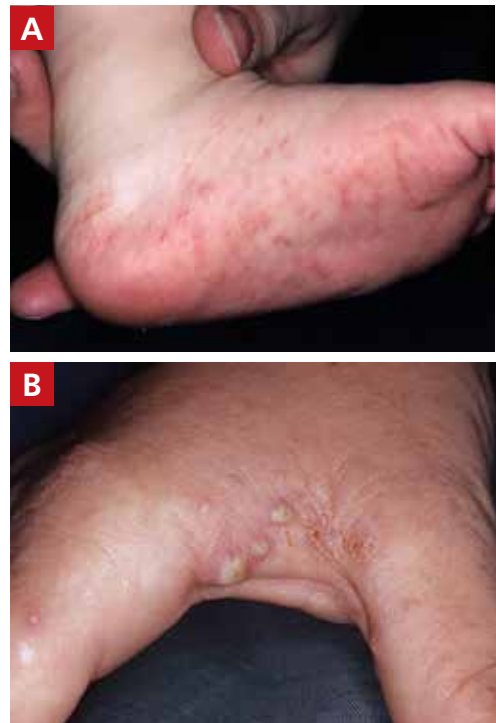
FIGURE 4
Scabies pustules on foot (infant; A) and in web space (adult; B)



➤
Mites are not found near pruritic papules. Scrape the mite burrows, which are small, linear, serpiginous lines, to discover the mature scabies mite.

Scabies' classic presentation

Typically, scabies causes intensely pruritic erythematous papules. Areas commonly affected are the webs and sides of fingers (FIGURE 1A AND 1B), proximal palm and wrist flexors, extensor aspects of the arms and legs, axillary folds, periumbilical areas, the peri-areolar region in women, buttocks and thigh creases, and, in males, the genitals. The head may also be affected in children (FIGURE 1C), but seldom in adults. Interestingly, the back is usually spared across all age groups, though not always (FIGURE 2).

The classic presentation also varies across age groups and populations.² In children, vesicles, pustules, and nodular pruritic lesions may coexist with eczema and impetigo. Among homeless individuals, coinfection with impetigo and eczema is common. Elderly patients are more likely to exhibit atypical lesions.⁶ Immunocompromised patients present with atypical papular scabies, crusted scabies, or scabies that may be only mildly pruritic or nonpruritic. In underdeveloped countries, indigenous populations are more susceptible to endemic scabies, with a high risk of scabies superinfection with *Streptococcus*.⁶

Scabies subtypes with varying presentations

Clinical manifestations of scabies subtypes may make it difficult to diagnose the disease. These subtypes include nodular, pustular, vesiculobullous, and crusted scabies (Norwe-

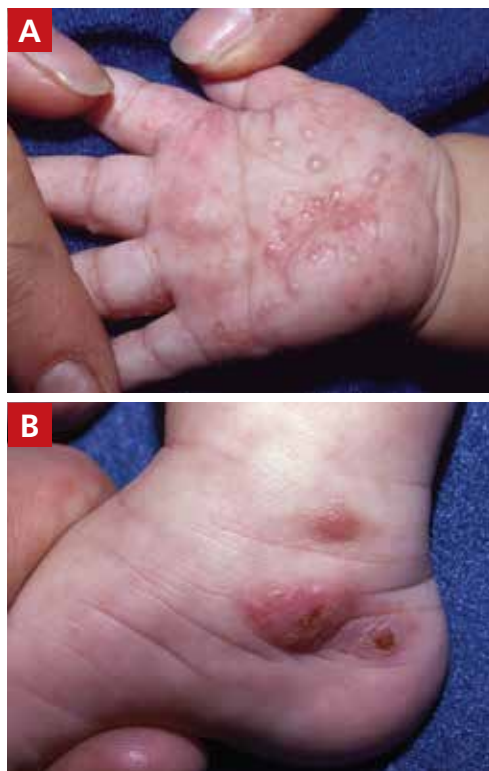gian scabies). Although rare, these subtypes merit acknowledgement, as atypical cases contribute to the high rate of misdiagnosis.

■ **Nodular scabies** is a clinical variant that accounts for about 7% of scabies cases.⁷ It can resist traditional scabies treatment (permethrin cream, ivermectin—which we'll discuss in a bit) and often requires topical or intralesional corticosteroid management. Nodular scabies most commonly affects male genitalia. Patients may have multiple excoriated skin-colored erythematous papules and nodules in areas involving the classic distribution of scabies (web spaces of fingers, flexural areas [FIGURE 3], scrotum, and groin).⁸

■ **Pustular scabies** is commonly seen in children and adolescents but can occur in all age groups. Patients may present with vesicular pustular lesions (FIGURE 4A AND 4B).⁷ In some cases, topical corticosteroids have modified the classic clinical presentation into a pustular variant. However, scabies alone can cause pustular lesions.

FIGURE 5

Scabies vesicles on an infant's palm and grouped on foot



■ **Vesiculobullous scabies** (FIGURE 5A AND 5B) is a clinical subtype that may be mistaken for pemphigus vulgaris⁹ or bullous pemphigoid¹⁰ because of its strikingly similar clinical presentation to those disorders.

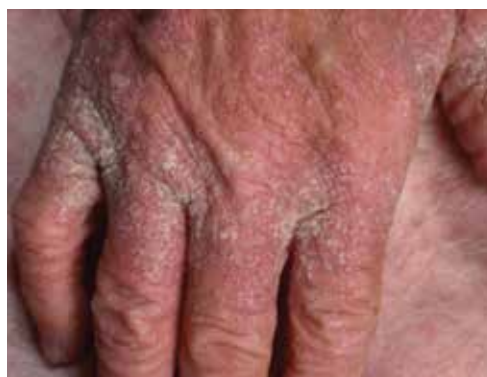■ **Crusted scabies** (Norwegian scabies) is a severe, disseminated form of scabies that commonly affects immunocompromised patients, although cases are also seen in immunocompetent hosts. Afflicted immunocompetent patients often have a history of diabetes mellitus, liver cirrhosis, malnutrition, or alcohol abuse.¹¹ Patients present with a thick powdery or crusted white or yellow scale involving the feet or hands (FIGURE 6) that sometimes extends onto the limbs. Severe cases can involve wide body surfaces. One unusual presentation also included a desquamating rash without pruritus.¹²

Highly atypical cases

Atypical presentations include lesions that

FIGURE 6

Crusted scabies



appear outside of the classic distribution areas of scabies, lesions with uncharacteristic morphology, cases with coinfections, and instances in which patients are immunocompromised.¹³ Examples include scabies of the scalp coexisting with seborrheic dermatitis or dermatomyositis,¹⁴ scabies mimicking mastocytoma,^{15,16} and scabies with coinfections of impetigo or eczema.¹⁷ These coinfections and clinical variations can be particularly challenging. Other reports of atypical scabies leading to misdiagnosis include a case of crusted scabies mimicking erythrodermic psoriasis¹⁸ and a case initially attributed to suppurative folliculitis and prurigo nodularis.¹⁹

Decisive diagnostic measures

Identifying the mite's burrow on clinical exam is essential to making the diagnosis of scabies. Microscopic examinations of burrow scrapings remain the diagnostic gold standard. Frequently, nondermatologists perform skin scrapings of the pruritic papules of scabies instead of the burrows. These papules are a hypersensitivity reaction to the mites, and no scabietic mites will be found there. Burrows appear on exam as small, linear, serpiginous lines (FIGURE 7A AND 7B).

Handheld illumination with a dermatoscope will allow visualization of the mite (FIGURE 8). (See "How fast do scabies mites move? Dermoscopy video answers that question" on page 15.) Dermatoscope findings consistent with scabies include a "delta glider," a dark triangular shape that is the

➤ **Distal white or yellow, thick, scaly, or crusted plaques can suggest psoriasis or dermatitis, but you should include scabies in the differential diagnosis.**

FIGURE 7

The serpiginous burrow of the scabies mite may be subtle (A) or readily visible (B)

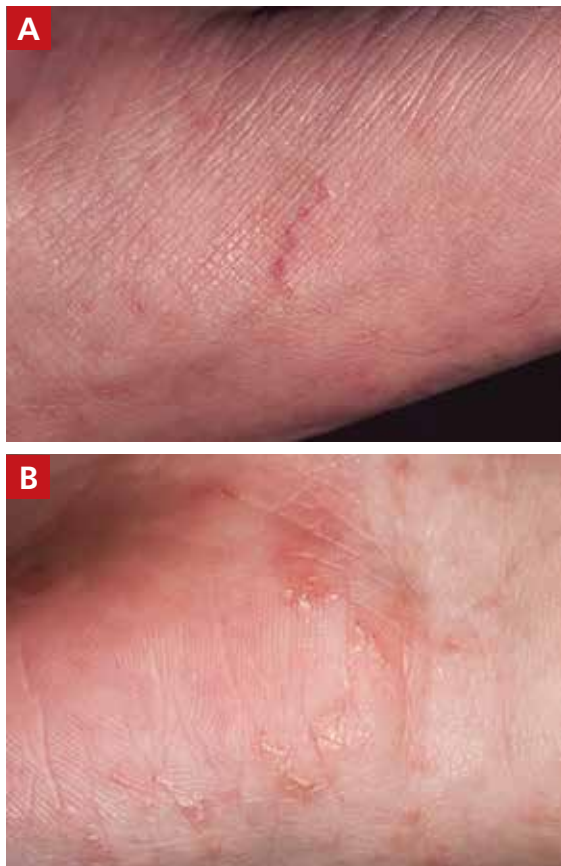

FIGURE 8

Dermatoscopic visualization of the scabies mite

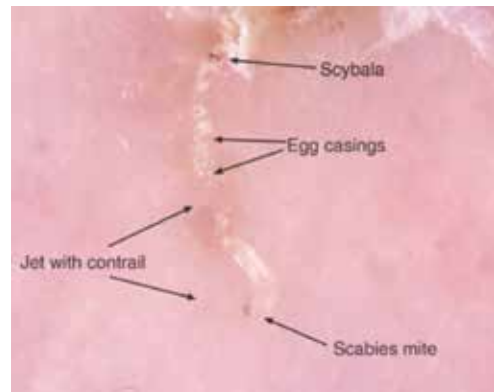
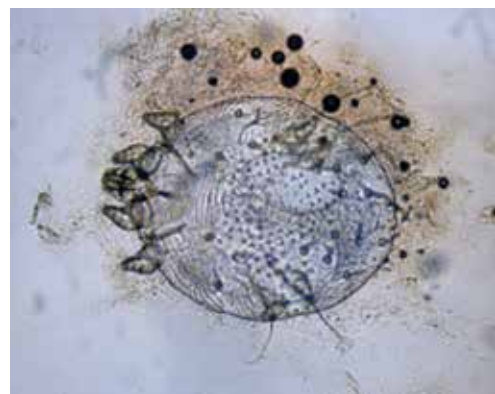


FIGURE 9

The scabies mite



mite's head hidden in the burrow,²⁰ or the classic "jet with contrail" (FIGURE 8).²¹ Scrape the burrow to discover the mature scabies mite (FIGURE 9) and confirm the diagnosis.

Microscopic examination of scrapings has a reported sensitivity and specificity of up to 90% and 100%, respectively, when collection of scrapings is performed accurately and contains ova, feces, or mites.^{14,20,22} Dermatologists increasingly use dermatoscopes to diagnose scabies. Dermoscopy's sensitivity is 91% and specificity is 85% to 86%,¹⁴ which is a reassuring frame of reference for physicians who do not routinely use dermatoscopes and instead rely on scrapings.

3 diagnostic missteps to avoid

Misdiagnosis is often due to an overreliance

on the clinical history without performing an adequate physical exam. In such cases, the physician often diagnoses a form of dermatitis as the cause of pruritic rash. (Admittedly, diagnostic error can result in either false-positive or false-negative findings, and many patients are diagnosed with scabies when they have dermatitis.)

A second misstep? Scabies may be overlooked in a patient whose lesions are nonpruritic, such as someone with an immunocompromising condition.

And finally, crusted scabies is frequently mistaken for psoriasis or chronic dermatitis.⁸

Diagnostic errors are exceedingly troublesome for patients and caregivers. It is not unusual for a hospital or long-term care facility to lose significant employee work hours

How fast do scabies mites move? Dermoscopy video answers that question

Richard Usatine, MD; Ashfaq Marghoob, MD

University of Texas Health San Antonio (Dr. Usatine); Memorial Sloan Kettering Skin Cancer Center, Hauppauge, NY (Dr. Marghoob).

Dr. Marghoob reported that he has received honoraria for speaking for 3GEN. Dr. Usatine reported no potential conflict of interest relevant to this article.

A 22-year-old man infected with human immunodeficiency virus presented to a clinic with a 6-month history of intense pruritus. Physical examination revealed scale crust on the hands and wrists (**FIGURE**) and in the pubic region.

Dermoscopic examination of the rash on the wrist revealed scabies mites actively crawling on the surface of the skin. A superficial skin scraping revealed the *Sarcoptes scabiei* mite, several eggs, and scybala under the microscope. The extensive infestation in this patient with crusted scabies was related to his immunocompromised state. (The patient was successfully treated with oral ivermectin and topical permethrin.)

■ **Unprecedented documentation of mite speed a clue to infectivity.** The 36-second **VIDEO** captured an adult mite travelling a distance of 3 mm, translating to a speed of 5 mm/min. Six younger adults/larvae were moving more rapidly with a maximum distance of 6 mm in 36 seconds (1 cm/min). The movement of a mite within the epidermis is slower, as the mite consumes keratin in creating burrows. The more rapid rate of movement on the skin surface may help to explain the contagious nature of scabies.

In this case, the mites and larvae were viewed on the screen of a smartphone to which a dermatoscope was attached magnetically. The mites were first visualized in the standard photo mode. Video mode was then used to capture the motion using the maximum zoom feature of the phone, to a magnification factor of 13.3x.

■ **Literature to date has been silent on mites' rate of motion.** A Medline search yielded only 3 papers that addressed the issue of in vivo movement of scabies mites. None viewed the mites other than in their burrows and none calculated a rate of motion.

- In one study using videodermoscopy, Micali stated that in most of the 16 cases identified, it was possible to observe the mites moving inside the burrows.¹ No video images were published, and there was no mention of speed or characterization of the movement.¹
- A second study used reflectance confocal microscopy (RCM) to examine a single patient with crusted scabies. The authors claim to have viewed the ectoparasite's motion within the human host but provided no details of that motion.²
- In the third study, videodermoscopy showed a slightly higher sensitivity for scabies detection than RCM (95% vs. 92%).³ The authors did not mention visualization of movement of mites in their work but did quote the Micali paper for its mention of movements of the mite.

■ **Applying digital dermoscopy in practice.** It appears that this is the first published video documenting the movement of scabies mites and larvae in vivo using dermoscopy. This should pave the way for additional observations of scabies movement on and below the skin using dermoscopy with video. We recommend using the maximum zoom capability of the device along with the dermatoscope to view this movement. What has been surmised before—that the mite must move above the skin to infect human contacts—has now been captured in vivo using the power of dermoscopy.

CORRESPONDENCE

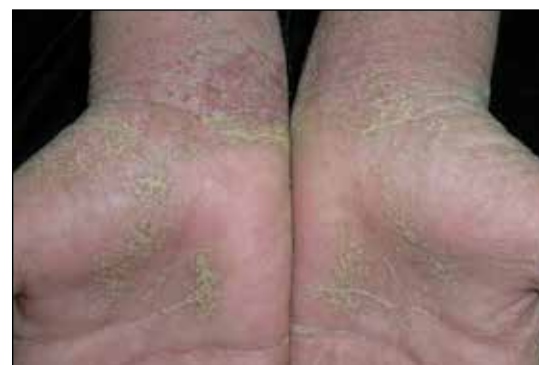Richard P. Usatine, MD, 903 West Martin Street, San Antonio, TX 78207; usatine@uthscsa.edu.

REFERENCES

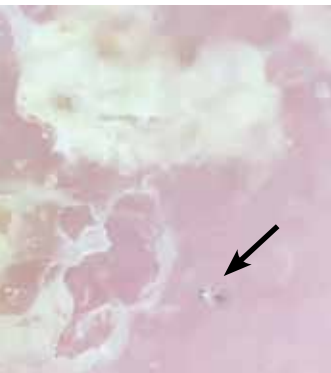1. Micali G, Lacarrubba F, Lo Guzzo G. Scraping versus videodermoscopy for the diagnosis of scabies: a comparative study. *Acta Derm Venereol.* 1999; 79:396.
2. Gürel MS, Turgut Erdemir AV, Tekin B. A case report of real-time in vivo demonstration of *Sarcoptes scabiei*. *Türkiye Parazitol Derg.* 2017; 41:229-232.
3. Cinotti E, Labeille B, Cambazard F, et al. Videodermoscopy compared to reflectance confocal microscopy for the diagnosis of scabies. *J Eur Acad Dermatol Venereol.* 2016; 30:1573-1577.

FIGURE

Scaly crust on an immunocompromised patient infected with scabies



© RICHARD USATINE, MD



Watch the video at mdedge.com/familymedicine of a scabies mite on the skin surface.

due to a scabies epidemic or fear of a scabies epidemic. In a 2003 outbreak of scabies in a Canadian long-term care facility, an estimated \$200,000 was needed to control disease spread.²³

A topical agent is a mainstay of treatment

Permethrin cream is usually the first-line treatment choice.²⁴ Ivermectin, topical (cream) or systemic (pill), is the commonly used alternative for patients who do not respond to, or cannot tolerate, permethrin cream. A recent meta-analysis examined the effectiveness of 5% permethrin cream, 1% ivermectin cream, and oral ivermectin (200 mcg/kg single or double dose).²⁴ Overall, findings suggested there was no difference in the efficacy or in adverse effects of permethrin cream compared with ivermectin (topical or systemic) among adults. One study reported that permethrin cream was slightly more effective than ivermectin (cream or oral) because of the more rapid treatment response (approximately 94% clearance within 2 weeks of treatment, compared with 90%).²⁵

Adjust treatment for special populations. Treatment of severe cases, such as crusted scabies, calls for combination therapy with oral ivermectin (200 mcg/kg) and 5% permethrin cream.²⁶

Five percent permethrin cream is the preferred treatment for children weighing < 15 kg and pregnant women; oral ivermectin has not been studied for efficacy and safety in these populations.²⁷

Effective response to treatment in these studies was measured by resolution of active scabies lesions and improvement in pruritus 1 to 2 weeks after treatment.

Anticipate these 3 clinical scenarios

The classic appearance of scabies usually triggers suspicion of its presence, leading to prompt identification of mite burrows and a correct diagnosis. Unfortunately, though, this is not always the case. And atypical presentations heighten the chance of diagnostic error, which overall occurs in nearly half of cases.¹ Keep in mind the following common scenarios, to help improve diagnosis.

1. When a patient presents with a severe pruritic eruption, the clinician may be tempted to settle early on a form of dermatitis and not consider the possibility of scabies. When the patient is later seen by an expert, the burrows are easily identified. Solution: Whenever a patient complains of severe pruritus, use a dermatoscope to carefully examine the digits, web spaces, proximal palms, wrists, and ankles for burrows.

2. A patient with distal white or yellow, thick, scaly, or crusted plaques is often thought to have psoriasis or dermatitis. But scabies should be included in the differential diagnosis. In particular, worsening thick, scaly plaques in an immunocompromised patient should prompt consideration of scabies.

3. Smooth nodules of the genitals in males, or pruritic smooth papules and plaques in other locations, should lead to the consideration of scabies. These presentations can be mistaken for lichen planus, folliculitis, papular urticaria, insect bites, or atopic dermatitis.

Due to the limited amount of mite burrows early in the disease process of scabies, and the gross similarities to a patient with dermatitis with skin excoriations, a thorough exam is needed—one that goes beyond the traditional web spaces and includes hidden/atypical locations such as margins of the feet and hands, the scalp, and neck creases. Careful and deliberate inspection for burrows is critical before ruling out the diagnosis. **JFP**

CORRESPONDENCE

Art Papier, MD, 400 Red Creek Drive, Suite 200, Rochester, NY 14623; art_papier@urmc.rochester.edu.

ACKNOWLEDGEMENT

We thank Angela Delacenserie, MA, for reviewing the manuscript and providing editing suggestions.

References

- Anderson KL, Strowd LC. Epidemiology, diagnosis, and treatment of scabies in a dermatology office. *J Am Board Fam Med.* 2017; 30:78-84.
- Chosidow O. Clinical practices. Scabies. *N Engl J Med.* 2006; 354:1718-1727.
- Arlian LG, Morgan MS. A review of *Sarcoptes scabiei*: past, present and future. *Parasit Vectors.* 2017; 10:297.
- Carr PC, Brodell RT. Images in clinical medicine: scabies. *N Engl J Med.* 2016; 374:e13.
- Berger TG, Shive M, Harper GM. Pruritus in the older patient: a clinical review. *JAMA.* 2013; 310:2443-2450.
- Hengge UR, Currie BJ, Jäger G, et al. Scabies: a ubiquitous neglected skin disease. *Lancet Infect Dis.* 2006; 6:769-779.



7. Reddy DR, Reddy PR. Nodular scabies: a classical case report in an adolescent boy. *J Parasit Dis*. 2015; 39:581-583.
8. Heukelbach J, Feldmeier H. Scabies. *Lancet*. 2006; 367:1767-1774.
9. Karaca Ş, Kelekçi KH, Er O, et al. Scabies incognito presenting as a subcorneal pustular dermatosis-like eruption. *Turkiye Parazit Derg*. 2015; 39:244-247.
10. Gutte RM. Bullous scabies in an adult: a case report with review of literature. *Indian Dermatol Online J*. 2013; 4:311-313.
11. Roberts LJ, Huffam SE, Walton SF, et al. Crusted scabies: clinical and immunological findings in seventy-eight patients and a review of the literature. *J Infect*. 2005; 50:375-381.
12. Ebrahim KC, Alves JB, Tomé LA, et al. Norwegian scabies—rare case of atypical manifestation. *An Bras Dermatol*. 2016; 91:826-828.
13. Walton SF, Currie BJ. Problems in diagnosing scabies, a global disease in human and animal populations. *Clin Microbiol Rev*. 2007; 20:268-279.
14. Dupuy E, Dehen L, Bourrat E, et al. Accuracy of standard dermoscopy for diagnosing scabies. *J Am Acad Dermatol*. 2007; 56:53-62.
15. Phan A, Dalle S, Balme B, et al. Scabies with clinical features and positive Darier sign mimicking mastocytosis. *Pediatr Dermatol*. 2009; 26:363-364.
16. Salces IG, Alfaro J, Sáenz DE, et al. Scabies presenting as solitary mastocytoma-like eruption in an infant. *Pediatr Dermatol*. 2009; 26:486-488.
17. Tasani M, Tong SY, Andrews RM, et al. The importance of scabies coinfection in the treatment considerations for impetigo. *Pediatr Infect Dis J*. 2016; 35:374-378.
18. Fonseca V, Price HN, Jeffries M, et al. Crusted scabies misdiagnosed as erythrodermic psoriasis in a 3-year-old girl with Down syndrome. *Pediatr Dermatol*. 2014; 31:753-754.
19. Carr PC, Brodell RT. Images in clinical medicine: scabies. *N Engl J Med*. 2016; 374:e13.
20. Park JH, Kim CW, Kim SS. The diagnostic accuracy of dermoscopy for scabies. *Ann Dermatol*. 2012; 24:194-199.
21. Lallas A, Apalla Z, Lazaridou E, et al. Scabies escaping detection until dermoscopy was applied. *Dermatol Pract Concept*. 2017; 7:49-50.
22. Micali G, Lacarrubba F, Verzi AE, et al. Scabies: advances in non-invasive diagnosis. *PLoS Negl Trop Dis*. 2016; 10:e0004691.
23. de Beer G, Miller MA, Tremblay L, et al. An outbreak of scabies in a long-term care facility: the role of misdiagnosis and the costs associated with control. *Infect Control Hosp Epidemiol*. 2006; 27:517-518.
24. Dhana A, Yen H, Okhovat JP, et al. Ivermectin versus permethrin in the treatment of scabies: a systematic review and meta-analysis of randomized controlled trials. *J Am Acad Dermatol*. 2018; 78:194-198.
25. Sharma R, Singal A. Topical permethrin and oral ivermectin in the management of scabies: a prospective, randomized, double blind, controlled study. *Indian J Dermatol Venereol Leprol*. 2011; 77:581-586.
26. Currie BJ, McCarthy JS. Permethrin and ivermectin for scabies. *N Engl J Med*. 2010; 362:717-725.
27. Salavastru CM, Chosidow O, Boffa MJ, et al. European guideline for the management of scabies. *J Eur Acad Dermatol Venereol*. 2017; 31:1248-1253.

WE WANT TO HEAR FROM YOU!

Have a comment on an article, editorial, or department? You can send it by:

1. **E-MAIL:** jfp.eic@gmail.com
2. **FAX:** 973-206-9251 or
3. **MAIL:** The Journal of Family Practice, 7 Century Drive, Suite 302, Parsippany, NJ 07054

LETTERS SHOULD BE 200 WORDS OR LESS. THEY WILL BE EDITED PRIOR TO PUBLICATION.



What do the new AGA guidelines recommend for opioid-induced constipation?

Doug Campos-Outcalt, MD, MPA



A quick guide to PrEP: Steps to take & insurance coverage changes to watch for

Doug Campos-Outcalt, MD, MPA

ONLINE EXCLUSIVES

- **APPLIED EVIDENCE**
How best to approach these acute hand infections
- Evidence-based tools for premenstrual disorders
- **CASE REPORT**
56-year-old woman • worsening pain in left upper arm • influenza vaccination in the arm a few days prior to pain onset • Dx?
- **CLINICAL INQUIRIES**
Do group visits improve HbA1c more than individual visits in patients with T2DM?

What is the best treatment for wrist ganglion cysts?
- **RESIDENTS' RAPID REVIEW**
A 5-question monthly quiz to help you prepare for the family medicine certification exam.
This month: Dermatology and recurrent headaches

PHOTO ROUNDS FRIDAY

Test your diagnostic skills at www.jfponline.com/articles/photo-rounds-friday.html

PLUS

Today's headlines in family medicine

GET UPDATES FROM US ON

FACEBOOK

www.facebook.com/MDedgeFMC

TWITTER

<https://twitter.com/MDedgeTweets>