



Dr. Arnold P. Advincula's

**VIDEO
CHANNEL**

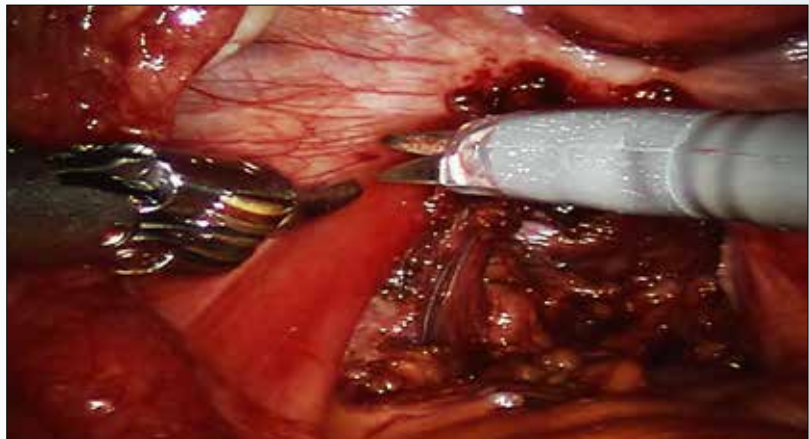

Robot-assisted laparoscopic excision of a rectovaginal endometriotic nodule

A review of key anatomy and a stepwise demonstration of technique

**Obianuju Sandra Madueke-Laveaux, MD, MPH;
Khara M. Simpson, MD; and Arnold P. Advincula, MD**

A rectovaginal endometriosis (RVE) is the most severe form of endometriosis. The gold standard for diagnosis is laparoscopy with histologic confirmation. A review of the literature suggests that surgery improves up to 70% of symptoms with generally favorable outcomes.

In this video, we provide a general introduction to endometriosis and a discussion of disease treatment options, ranging from hormonal suppression to radical



▲ To view the video

Visit Arnold Advincula's Surgical Techniques Video Channel, found in the MENU at obgmanagement.com or use the QR code at right >>>>



Dr. Madueke-Laveaux is Assistant Attending, Department of Obstetrics & Gynecology, Columbia University Medical Center, New York, New York.

Dr. Simpson is Assistant Professor, Minimally Invasive Gynecology, Johns Hopkins Hospital, Baltimore, Maryland.

Dr. Advincula is the Levine Family Professor of Women's Health and Vice Chair, Department of Obstetrics & Gynecology, Columbia University Medical Center and Chief of Gynecology, Sloane Hospital for Women at New York-Presbyterian Hospital/Columbia University. He serves on the OBG MANAGEMENT Board of Editors.

Dr. Advincula reports being a consultant to Intuitive Surgical and Titan Medical and having additional financial relationships with Applied Medical, ConMed, and CooperSurgical. The other authors report no financial relationships relevant to this video.

bowel resections. We also illustrate the steps in robot-assisted laparoscopic excision of an RVE nodule:

1. identify the borders of the rectosigmoid
2. dissect the pararectal spaces
3. release the rectosigmoid from its attachment to the RVE nodule
4. identify and isolate the ureter(s)
5. determine the margins of the nodule

6. ensure complete resection.

Excision of an RVE nodule is a technically challenging surgical procedure. Use of the robot for resection is safe and feasible when performed by a trained and experienced surgeon.

I am pleased to bring you this video, and I hope that it is helpful to your practice. 📌

>> **Arnold P. Advincula, MD**