

Foot and Ankle Injuries in American Football

Andrew R. Hsu, MD, and Robert B. Anderson, MD

Abstract

Physicians need to be aware of a variety of foot and ankle injuries that commonly occur in American football, including turf toe, Jones fractures, Lisfranc injuries, syndesmotic and deltoid disruption, and Achilles ruptures. These injuries are often complex and require early individual tailoring of treatment and rehabilitation protocols. Successful management and return to play requires early diagnosis, a thorough work-up, and prompt surgical intervention when warranted with meticulous attention to restoration of normal foot and ankle anatomy. Physicians should have a high suspicion for subtle injuries and variants that can occur via both contact and noncontact mechanisms.

Editor's Note: For additional Figures, view this article on amjorthopedics.com.

Foot and ankle injuries are common in American football, with injury rates significantly increasing over the past decade.¹⁻⁵ Epidemiologic studies of collegiate football players have shown an annual incidence of foot and ankle injuries ranging from 9% to 39%,^{3,6} with as many as 72% of all collegiate players presenting to the National Football League (NFL) Combine with a history of a foot or ankle injury and 13% undergoing surgical treatment.⁵ Player position influences the rate and type of foot and ankle injury. Offensive and "skill position" players, including linemen, running backs, and wide receivers, are particularly susceptible to foot and ankle injuries due to high levels of force and torque placed on the distal extremity during running, cutting, and tackling. Shoe wear changes, playing field conditions, increasing player

size and speed, and improved reporting of injuries are also contributing to increasing injury rates.

The interaction between player cleats and the playing surface is a central issue of foot and ankle injuries in football. Improved traction relates to performance, but increased subsequent torque on the lower extremity is associated with injury. While lateral ankle sprains are the most common foot and ankle injury experienced by football players,⁷ numerous other injuries can occur, including turf toe, Jones fractures, Lisfranc injuries, syndesmotic disruption, deltoid complex avulsion, and Achilles ruptures. It is important for physicians to be able to recognize, diagnose, and appropriately treat these injuries in players in order to expedite recovery, restore function, and help prevent future injury and long-term sequelae. This review focuses on updated treatment principles, surgical advances, and rehabilitation protocols for common football foot and ankle injuries.

Turf Toe

The term "turf toe" was first used in 1976 to refer to hyperextension injuries and plantar capsule-ligament sprains of the hallux metatarsophalangeal (MTP) joint that can lead to progressive cock-up deformity.⁸ While these injuries can occur on any surface and disrupt soft tissue balance with functional implications, predisposing factors include increasing playing surface hardness and decreasing shoe stiffness. In a classic scenario, the foot is fixed in equinus as an axial load is placed on the back of the heel, resulting in forced dorsiflexion of the hallux MTP joint.⁹ As the proximal phalanx extends, the sesamoids are drawn distally and the more dorsal portion of the metatarsal head articular surface bears the majority of the load, causing partial or complete tearing of the plantar plate with or without hallux MTP dislocation. Osteochondral lesions of the MTP joint and subchondral edema of the metatarsal head can occur concurrently as the proximal phalanx impacts or shears across the metatarsal head articular surface.

Authors' Disclosure Statement: Dr. Hsu reports that he is a paid speaker/presenter for Arthrex. Dr. Anderson reports that he receives royalties from Arthrex, DJ Orthopaedics, and Wright Medical Technology; is a paid consultant for Amniox, Wright Medical Technology, and Arthrex; and receives research support from Wright Medical Technology.

Clinical examination should focus on hallux swelling, alignment, and flexor hallucis longus (FHL) function along with vertical instability of the hallux MTP joint using a Lachman test. Radiographs should be evaluated for proximal migration of the sesamoids or diastasis (see **Figures W1A-W1C** on amjorthopedics.com). Forced hallux MTP dorsiflexion lateral view can help assess the distance from the distal sesamoid to the base of the phalanx. A small fleck of bone pulled off of the proximal phalanx or distal sesamoid may indicate a capsular avulsion or disruption. Live fluoroscopy can be very helpful in diagnosing turf toe, as the physician can assess the trailing motion of the sesamoids with increasing dorsiflexion and evaluate instability in all planes. Magnetic resonance imaging (MRI) is useful for subtle capsular injuries and can also identify osseous and articular damage that may occur and FHL disruption (see **Figures W2A, W2B** on amjorthopedics.com). Nonoperative intervention focuses on rest, ice, compression, and elevation (RICE) and nonsteroidal anti-inflammatory drugs (NSAIDs). The hallux is temporarily immobilized in a plantarflexed position using a short leg cast or walking boot with toe spica or turf toe plate with tape for 2 to 3 weeks.

Indications for surgical intervention include loss of push-off strength, gross MTP instability, proximal migration of the sesamoids, and progressive hallux malalignment or clawing after immobilization. Cases can involve one or a combination of the following: (1) large capsular avulsion with unstable MTP joint; (2) diastasis of bipartite sesamoid; (3) diastasis of sesamoid fracture; (4) retraction of sesamoid; (5) traumatic hallux valgus deformity; (6) vertical instability (positive Lachman test); (7) loose body in MTP joint; or (8) chondral injury in MTP joint. The goal of surgery is the restoration of anatomy in order to restore normal function of the hallux MTP joint.

We have found that using dual medial and plantar incisions places less traction on the plantar medial cutaneous nerve, improves lateral exposure, and provides better wound healing. The medial capsulotomy extends from the metatarsal neck to the mid-phalanx to provide complete visualization of the sesamoid complex (**Figures 1A-1F**). The collateral ligaments are often torn away from the metatarsal head during the initial dissection and the plantar plate tear is distal to the sesamoid complex. The soft tissue defect in the plantar complex must be closed distal to the sesamoids followed by advancement of the

plantar plate to the proximal phalanx in a distal to proximal fashion and advancement of the medial capsule. The plantar incision is made along the lateral border of hallux MTP-sesamoid complex just lateral to the weight-bearing surface of the hallux and the plantar lateral cutaneous nerve is carefully dissected and retracted out of the way. Sutures are placed in a figure-of-eight fashion through the plantar capsule and plantar plate starting lateral to medial to reduce injury to the nerve. If the tear cannot be primarily repaired due to inadequate healthy tissue, a plantar plate advancement can be performed directly onto the base of the proximal phalanx using drill holes or suture anchors. Proper alignment and motion of the sesamoids should be verified with fluoroscopy and compared to the contralateral hallux (see **Figures W3A, W3B** on amjorthopedics.com).

It is important to recognize that not all turf toe injuries involve pure hyperextension on artificial playing surfaces. In recent years, we have found an increasing rate of medial variant turf toe injuries in which a forceful valgus stress on the hallux leads to rupture of the medial collateral ligament, medial or plantar-medial capsule, and/or abductor hallucis. Medial variant turf toe can lead to progressive hallux valgus and a traumatic bunion with a significant loss of push-off strength and difficulty with cutting maneuvers. Surgical treatment requires a modified McBride bunionectomy with adductor tenotomy and direct repair of the medial soft tissue defect.

Postoperative management is just as important as proper surgical technique for these injuries and involves a delicate balance between protecting the repair and starting early range of motion (ROM). Patients are immobilized non-weight-bearing (NWB) for 5 to 7 days maximum followed immediately with the initiation of passive hallux plantarflexion to keep the sesamoids moving. Active hallux plantarflexion is started at 4 weeks after surgery with active dorsiflexion from 6 to 8 weeks. Patients are transitioned to an accommodative shoe with stiff hallux insert 8 weeks postoperative with continued therapy focusing on hallux ROM. Running is initiated at 12 weeks and return to play (RTP) is typically allowed 4 months after surgery.

Jones Fractures

Jones fractures are fractures of the 5th metatarsal at the metaphyseal-diaphyseal junction, where



there is a watershed area of decreased vascularity between the intramedullary nutrient and metaphyseal arteries. Current thought is that the rising rate of Jones fractures among football players is partially caused by the use of flexible, narrow cleats that do not provide enough stiffness and lateral support for the 5th metatarsal during running and cutting. Additionally, lateral overload from a baseline cavovarus foot posture with or without metatarsus adductus and/or skewfoot is thought to contribute to Jones fractures.¹⁰ Preoperative radiographs should be evaluated for fracture location, orientation, amount of cortical thickening, and overall geometry of the foot and 5th metatarsal. In elite athletes, the threshold for surgical intervention is decreasing in order to expedite healing and recovery and decrease re-fracture risk. This rationale is based on delayed union rates of 25% to 66%, nonunion

rates of 7% to 28%,¹¹ and re-fracture rates of up to 33% associated with nonoperative treatment.¹² Nonoperative management is usually not feasible in the competitive athlete, as it typically involves a period of protected weight-bearing in a tall controlled ankle motion (CAM) boot for 6 to 8 weeks with serial radiographs to evaluate healing.

Our preference for surgical intervention involves percutaneous screw fixation with a “high and inside” starting point on fluoroscopy (**Figures 2A-2D**). The guidewire is inserted percutaneously through the skin 2 cm proximal to the base of the 5th metatarsal. Incorrect starting point can lead to a prominent screw head laterally or perforation of the medial cortex. A 1-cm incision is made around the guidewire entry point and intramedullary cannulated drilling enters the proximal third of the metatarsal, removing any thickened lateral cortex.

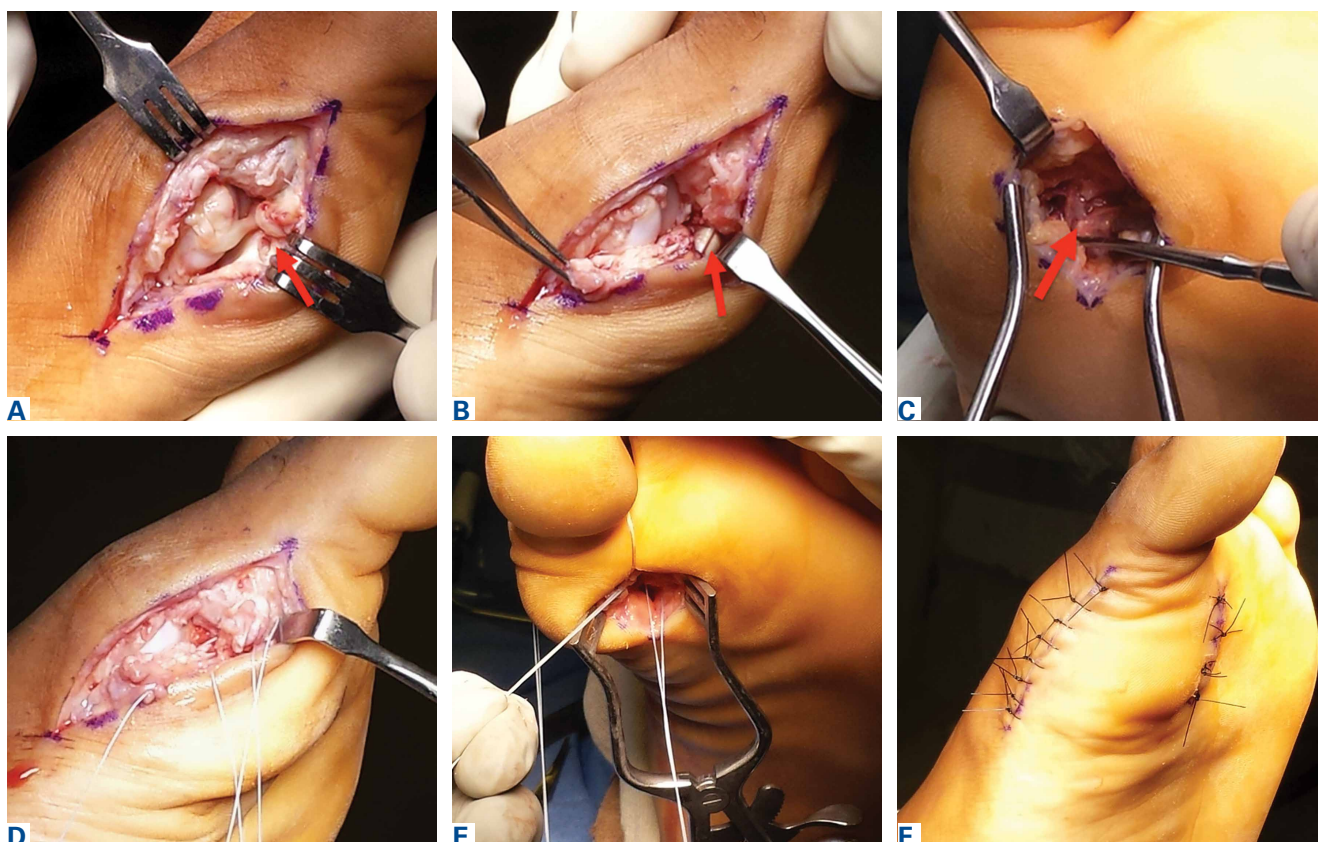


Figure 1. (A) A medial longitudinal incision is made just plantar to midline extending from the metatarsal neck to the flexion crease at the base of the hallux. A capsulotomy is performed from the metatarsal neck to the mid-phalanx to provide complete visualization of the sesamoid complex (red arrow indicates plantar plate rupture distal to medial sesamoid). Remaining collateral ligaments are dissected off the metatarsal head and a rongeur is used to remove a small amount of bone from the medial aspect of the metatarsal head to create a bleeding bony surface for ligament-to-bone healing. (B) Remaining plantar plate tissue is taken off of the proximal phalanx with visualization of the flexor hallucis longus tendon (red arrow). (C) A plantar incision is then made along the lateral border of hallux metatarsophalangeal-sesamoid complex off of the weight-bearing surface of the hallux. The nerve is gently retracted laterally to get down to the plantar aspect of the sesamoid complex (red arrow). (D) Sutures are placed in a figure-of-eight fashion in the medial aspect of the sesamoid complex in distal and proximal aspects of the plantar plate along with (E) sutures in the plantar capsule lateral to medial. Sutures are tied with the hallux plantarflexed 10° to 15°. (F) After final repair, the hallux should be aligned straight and slightly plantarflexed with maintenance of alignment.

Due to the natural curve of the 5th metatarsal, cannulated drilling is not continued distally but can be safely completed with a 3.2-mm solid drill bit. Proper tap sizing should generate enough torque to begin to rotate the entire foot as the tap is advanced (see **Figures W4A-W4F** on amjorthopedics.com). The largest solid screw with a low-profile head that “comfortably” fits the intramedullary canal of the 5th metatarsal should be inserted (Carolina Jones Fracture System, Wright Medical Technology).¹³ In elite athletes, we will typically use a 5.5-mm or 6.5-mm screw that is 45 to 55 mm in length. Screw threads should pass just across the fracture site, avoiding “straightening” of the curved 5th metatarsal that will create a lateral gap and increase the rate of nonunion. We do not recommend headless tapered screws due to inconsistent compression and difficulty with later removal if re-fracture or nonunion occurs.

In career athletes, we augment the fracture site using a mixture of bone marrow aspirate concentrate (BMA) (Magellan, Arterocyte Medical Systems) and demineralized bone matrix (DBM) (Mini Ignite, Wright Medical Technology) injected percutaneously in and around the fracture site under fluoroscopic guidance. Using this technique in a cohort of 25 NFL players treated operatively for Jones fractures, we found that 100% of athletes were able to RTP in the NFL in an average of 9.5 weeks.¹⁴ Two patients (7.5%) suffered re-fractures requiring revision surgery with iliac crest bone graft and repeat screw placement with a RTP after 15 weeks. We did not find an association between RTP and re-fracture rate.

The appropriate rehabilitation protocol for Jones fractures after surgery remains controversial and dependent on individual needs and abilities.^{15,16} For athletes in-season, we recommend a brief period of NWB for 1 to 2 weeks followed by toe-touch weight-bearing in a tall CAM boot for 2 to 4 weeks. After 4 weeks, patients begin gentle exercises on a stationary bike and pool therapy to reduce impact on the fracture site. Low-intensity pulsed ultrasound bone stimulators (Exogen, Bioventus) are frequently used directly over fracture site throughout the postoperative protocol as an adjuvant therapy. If clinically nontender over the fracture site, patients are allowed to begin running in modified protective shoe wear 4 weeks after surgery with an average RTP of 6 to 8 weeks. RTP is determined clinically, as radiographic union may not be evident for 12 to 16 weeks. Useful custom orthoses include turf toe plates with a cushioned lateral column and lateral heel wedge if hindfoot varus is present preopera-

tively.¹⁰ The solid intramedullary screw is left in place permanently.

In our experience, we have found the average re-fracture and nonunion rate to be approximately 8% across all athletes. Our observation that union rates do not appear to be related to RTP times suggests that underlying biology such as Vitamin D deficiency may play a larger role in union rates than previously thought. We have found that most Jones re-fractures occur in the first year after the initial injury, but can occur up to 2.5 years afterwards as well.¹⁴ For the management of symptomatic re-fractures and nonunions, the previous screw must be first removed. This can be difficult if the screw is bent or broken, and may require a lateral corticotomy of the metatarsal.

After hardware removal, we advocate open bone grafting of the fracture site using bone from the iliac crest retrieved with a small, percutaneous trephine. Re-fixation should be achieved using a

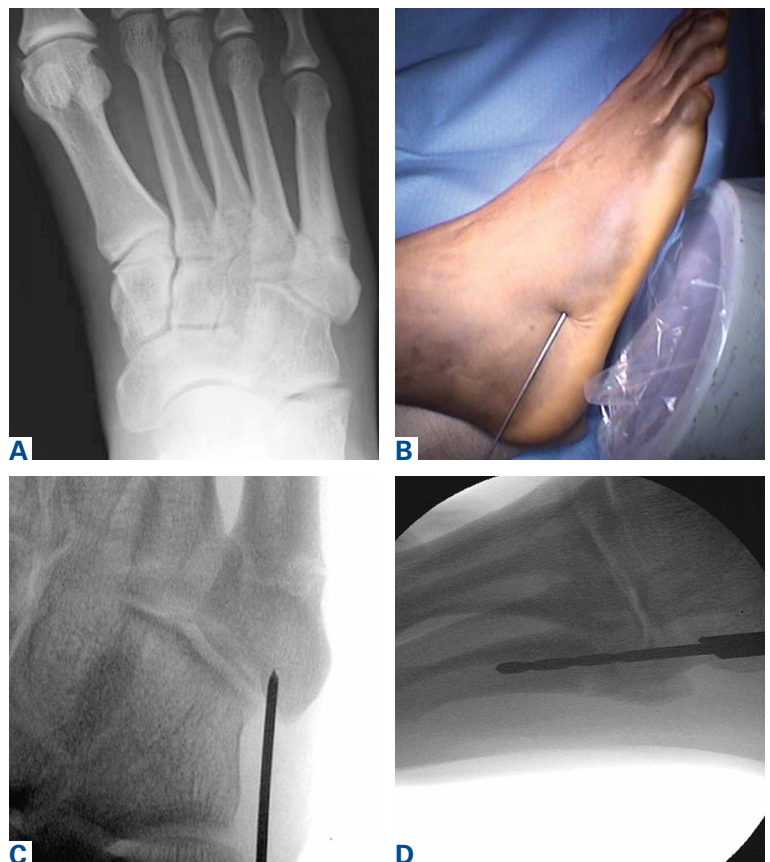

Figure 2. (A) Preoperative anteroposterior (AP) radiograph showing fracture of the 5th metatarsal metaphyseal-diaphyseal junction with lateral cortical thickening. (B) The guidewire is inserted 2 cm proximal to base of 5th metatarsal with (C) AP radiograph showing appropriate guidewire placement in line with the intramedullary canal of the 5th metatarsal (“inside”). (D) Lateral radiograph showing intramedullary drilling in “high” position to remove cortical thickenings that may cause tap and screw deflection.

larger, solid screw and postoperative adjuvants may include bone stimulators, Vitamin D and calcium supplementation, and possible teriparatide use (Forteo, Eli Lilly), depending on individual patient profile. In a cohort of 21 elite athletes treated for Jones fracture revision surgery with screw exchange and bone grafting, we found that 100% of patients had computed tomography (CT) evidence of union, with an average RTP of 12.3 weeks.¹⁷

Lisfranc Injuries

Lisfranc injuries include any bony or ligamentous damage that involves the tarsometatarsal (TMT) joints. While axial loading of a fixed, plantarflexed foot has traditionally been thought of as the most common mechanism of Lisfranc injury, we have found that noncontact twisting injuries leading to Lisfranc disruption are actually more common among NFL players. This mechanism is similar to noncontact turf toe and results in a purely ligamentous injury. We have found this to be particularly true in the case of defensive ends engaged with offensive linemen in which no axial loading or contact of the foot occurs. Clinically, patients often have painful weight-bearing, inability to perform a single limb heel rise, plantar ecchymosis, and swelling and point tenderness across the bases of the 1st and 2nd metatarsals.

It is critical to obtain comparison weight-bearing radiographs of both feet during initial work-up to look for evidence of instability. Subtle radiographic findings of Lisfranc injury include a bony "fleck" sign, compression fracture of the cuboid, and diastasis between the base of the 1st and 2nd metatarsals and/or medial and middle cuneiforms (**Figures 3A, 3B**). Stress testing involves pronation

and adduction of the foot under live fluoroscopy to evaluate for diastasis. MRI can be helpful in cases of vague pain with negative radiographs and subtle displacement. Nonoperative treatment for cases of no instability or displacement involved protected weight-bearing for 4 weeks followed by progressive increase in activities, with RTP 6 to 8 weeks after injury.

The goal of surgical intervention is to obtain and maintain anatomic reduction of all unstable joints in order to restore a normal foot posture. One of the difficulties with Lisfranc injuries is that there are no exact diastasis parameters and individuals should be treated based on symptoms, functional needs, and degree of instability. It has been shown that 5 mm of displacement can have good long-term clinical results in select cases without surgery.¹⁸ For surgery, we recommend open reduction to remove interposed soft tissue debris and directly assess the articular surfaces (**Figures 4A-4D**). A freer can be placed in the individual joints to assess for areas of instability. We prefer solid screw fixation (Charlotte Lisfranc Reconstruction System, Wright Medical Technology) to decrease the risk of later screw breakage. A homerun screw from the proximal aspect of the medial cuneiform to the distal-lateral aspect of the 2nd metatarsal base should be placed first. Bridge plates can be used over the 1st and 2nd TMT joints to avoid articular cartilage damage without a loss of rigidity.¹⁹

Proximal-medial column Lisfranc injury variants are increasingly common among football players.²⁰ In these injuries, the force of injury extends through the intercuneiform joint and exits out the naviculocuneiform joint, thus causing instability at multiple joints and an unstable 1st ray. Patients often have minimal clinical findings and normal radiographs and stress radiographs. MRI of the foot often reveals edema at the naviculocuneiform joint. Often patients fail to improve with nonoperative immobilization with continued inability to push off from the hallux. Unrecognized or untreated instability will lead to rapid deterioration of the naviculocuneiform joint. Surgical intervention requires a homerun screw and intercuneiform screw. We do not

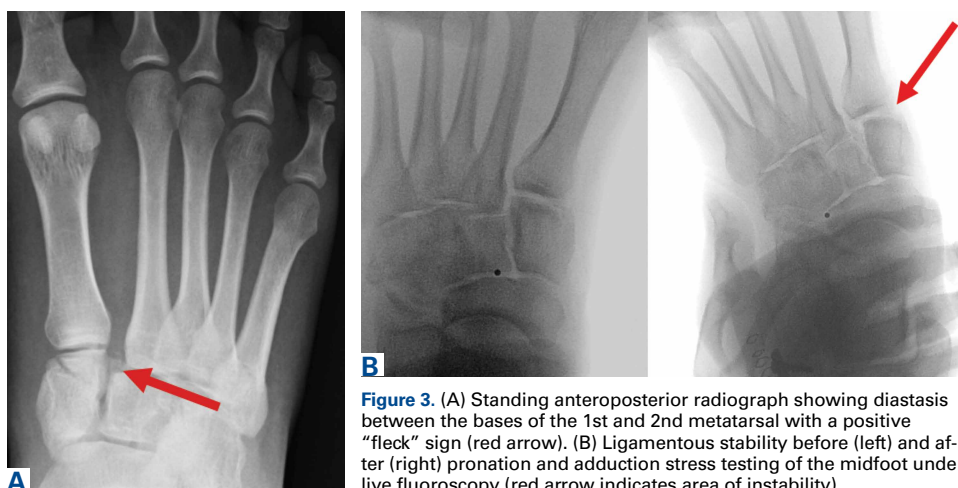

Figure 3. (A) Standing anteroposterior radiograph showing diastasis between the bases of the 1st and 2nd metatarsals with a positive "fleck" sign (red arrow). (B) Ligamentous stability before (left) and after (right) pronation and adduction stress testing of the midfoot under live fluoroscopy (red arrow indicates area of instability).

recommend primary arthrodesis in athletes due to significant risk of malunion and nonunion unless severe articular damage is present.

Patients are typically kept NWB in a splint for 2 weeks after surgery followed by NWB in a tall CAM from 3 to 4 weeks postoperative. Progressive weight-bearing and ROM exercises are initiated from 4 to 8 weeks, followed by return to accommodative shoe wear from 10 to 12 weeks. Hardware removal is performed 4 to 6 months after surgery, typically in the off-season to allow for 6 to 8 weeks or protected recovery afterwards. Premature hardware removal can lead to loss of reduction, particularly at the intercuneiform joints. All hardware crossing the TMT joints should be removed, while the homerun screw can be left in place in addition to the intercuneiform screw. RTP in football typically occurs 6 to 7 months after surgery. Final functional outcome is related to the adequacy of initial reduction and severity of the initial injury.²¹

Syndesmotic Disruption

Syndesmotic injuries comprise 1% to 18% of ankle sprains in the general population, but occur at much higher rates in football due to the increased rotation forces placed on the ankle during cutting and tackling. RTP after syndesmotic injury often takes twice as long when compared to isolated lateral ankle ligamentous injury.²² Missed injuries are common and if not treated properly can lead to chronic ankle instability and posttraumatic ankle arthritis.²³ Syndesmotic injury can occur in isolation or with concomitant adjacent bony, cartilaginous, or ligamentous injuries. Therefore, clinical examination and imaging work-up are critical to successful management.

Syndesmotic injuries often result from an external rotation force applied to a hyperdorsiflexed ankle while the foot is planted. This mechanism causes the fibula to externally rotate while translating posteriorly and laterally, resulting in rupture of the anterior inferior tibiofibular ligament (AITFL) first, followed by the deep deltoid ligament, interosseous ligament (IOL), and lastly posterior talofibular ligament.²⁴ Most syndesmotic injuries involve rupture of only the AITFL and IOL.²⁵ Multiple clinical stress tests have been designed to assess syndesmotic stability, including the squeeze test, external rotation stress test, crossed-leg test, and fibula-translation test.²⁶⁻²⁹ However, no physical examination maneuver has been shown to reliably predict the presence or degree of syndesmotic injury and therefore imaging studies are necessary.³⁰

Initial imaging should include standing radio-

graphs of the affected ankle. An increase in the medial clear space between the medial malleolus and talus can occur with a combined syndesmotic and deltoid disruption. In the case of subtle syndesmotic injuries, contralateral comparison weight-bearing radiographs are recommended. CT and MRI can provide additional information, but these static imaging tests cannot identify instability. Fluoroscopic stress evaluation is beneficial but has a high false-negative rate in low-grade injuries and may not detect partial rupture of the AITFL and IOL.³¹ It has been shown that malrotation of as much as 30° of external rotation can occur if relying on intraoperative fluoroscopy alone.³² It has been our practice to recommend surgical reduction and stabilization for any syndesmotic injury with documented diastasis or instability seen on imaging and/or arthroscopy.

Nonoperative treatment is indicated for truly stable grade I syndesmotic injuries. This involves rest and immobilization followed by a progressive

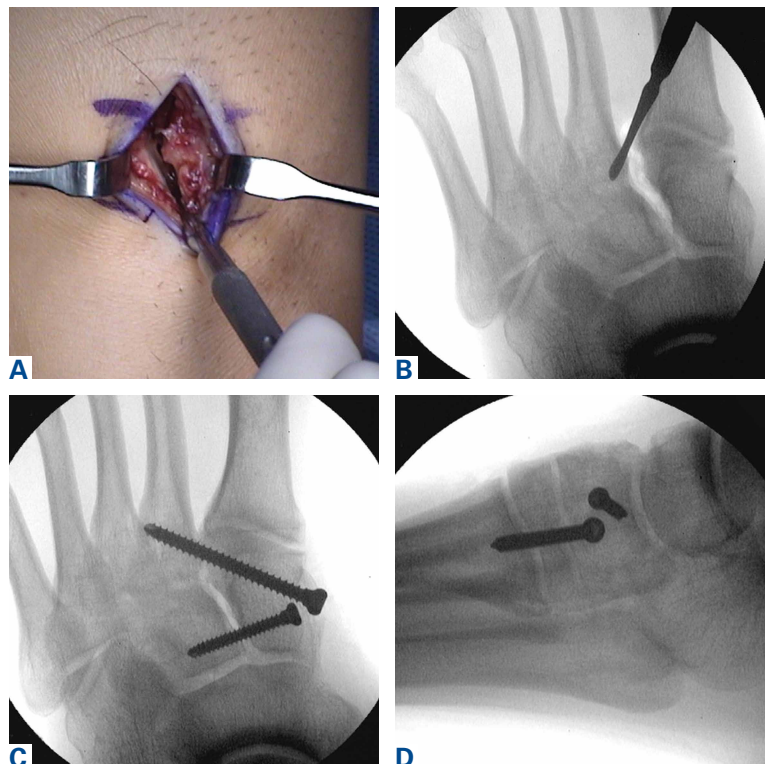


Figure 4. (A) A small longitudinal incision is made over the Lisfranc joint using fluoroscopic guidance and interposed soft tissue debris is removed followed by direct inspection of any instability within the Lisfranc joint and intercuneiform joint using a freer with manual manipulation. (B) Fluoroscopy is also used to evaluate joint instability. (C) The Lisfranc joint is reduced followed by insertion of a solid homerun screw from the proximal aspect of the medial cuneiform to the distal-lateral aspect of the 2nd metatarsal base. A solid intercuneiform screw is added if a proximal-medial column Lisfranc injury variant is present. (D) Lateral radiograph confirms proper screw trajectory within the center of bone.

rehabilitation program consisting of stretching, strengthening, and proprioceptive exercises.³³ After 1 week of protected weight-bearing in a cast or tall CAM boot, progression to full weight-bearing should occur over the following week. Active-assisted ankle ROM exercises and light proprioceptive training should then be initiated followed by sport-specific exercises 2 to 3 weeks after injury.

Arthroscopy can be a valuable diagnostic tool in the setting of subtle syndesmotom injury with negative radiographs, positive MRI for edema, and a protracted recovery course with vague pain (see **Figures W5A-W5E** on amjorthopedics.com). In these situations, an examination under anesthesia is performed, the syndesmosis is probed under direct arthroscopic visualization, and distal tibiofibular instability is evaluated while performing an external rotation stress test. For surgical intervention of these subtle varieties or any athlete with documented instability, we prefer the use of dynamic stabilization with a knotless suture-button construct (TightRope, Arthrex) or hybrid fixation with screws (3.5/4.5 mm) and suture-buttons. Advantages of a knotless suture-button construct include more physiologic motion at the syndesmosis and decreased hardware irritation and implant removal.

Implants are placed above the true syndesmotom joint (at least 15 mm above the tibial plafond) angled 30° posterior to anterior to follow the normal relationship of the fibula to the distal tibia in the incisura. Typically 2 suture-buttons are used, with the devices placed in a divergent fashion. We highly recommend the use of a fibular buttress plate with button placement in individuals returning to contact activity. This construct increases surface area distribution while preventing stress risers and the risk of fibula fractures. In a cadaver model with deliberate syndesmotom malreduction, suture-button stabilization resulted in decreased postoperative displacement as opposed to conventional screw fixation.³⁴ Therefore, dynamic syndesmotom fixation may help to decrease the negative sequelae of iatrogenic clamp malreduction. Postoperative rehabilitation involves NWB in a cast or tall CAM boot for 4 weeks followed by ankle ROM exercises and progressive weight-bearing and physical therapy. Patients are transitioned to a lace-up ankle brace and athletic shoe from 6 to 12 weeks postoperative with increasing activity. Running and jumping is permitted 4 months after surgery with RTP typically at 6 to 7 months. Athletes who have had surgical stabilization for documented instability

without any diastasis may engage in a more rapid recovery and RTP as symptoms and function allow.

Deltoid Complex Avulsion

Missed or neglected deltoid ligament injuries can lead to progressive chondral injury and joint degeneration. These injuries are often subtle and difficult to diagnose. An inability to perform a single limb heel rise, persistent pain with activity, and lack of normal functional improvement despite appropriate care are indicators of subtle ligament instability. These injuries often require an examination under anesthesia with combined ankle arthroscopy. Valgus stress testing of the ankle while directly visualizing the deltoid ligament from the anterolateral portal can reveal medial laxity in addition to potential osteochondral lesions along the anterolateral talar dome.

In American football players, we have observed that infolding and retraction of an avulsed superficial deltoid ligament complex after an ankle fracture, Maisonneuve injury, or severe high ankle sprain can be a source of persistent increased medial clear space, malreduction, and postoperative pain and medial instability. We have found that there is often complete avulsion of the superficial deltoid complex off the proximal aspect of the medial malleolus during high-energy ankle fractures in football players that is amenable to direct repair to bone (see **Figures W6A-W6E** on amjorthopedics.com). In a cohort of 14 NFL players who underwent ankle fracture fixation with ankle arthroscopy and debridement, fibula fixation with plate and screws, syndesmotom fixation with suture-button devices, and open deltoid complex repair with suture anchors, all athletes were able to return to running and cutting maneuvers by 6 months after surgery.³⁵ There were no intraoperative or postoperative complications noted, and no players had clinical evidence of medial pain or instability at final follow-up with radiographic maintenance of anatomic mortise alignment.

During surgical repair, an incision is made along the anterior aspect of the medial malleolus and the superficial deltoid ligament complex can often be found flipped and interposed in the medial gutter. A rongeur is used to create a bleeding cancellous bone surface for soft-tissue healing and 1 to 2 suture anchors are used to repair and imbricate the deltoid ligament complex back to the medial malleolus. The goal of these sutures is to repair the tibionavicular and tibial spring ligaments back to the medial malleolus. We believe that superficial deltoid

complex avulsion during high-energy ankle fractures is a distinct injury pattern that should be recognized and may benefit from primary open repair.

We currently open explore every deltoid ligament complex in athletes with unstable syndesmotic injuries, as we believe that deltoid avulsion injuries are underrecognized and do not heal in an anatomic fashion if left alone. Postoperative recovery follows the same immobilization, progressive weight-bearing, and physical therapy protocol as that for syndesmotic disruption.

Achilles Ruptures

Acute midsubstance Achilles tendon ruptures are an increasingly common injury in patients 30 to 50 years of age, with more than 50% of all injuries occurring during basketball.^{36,37} Among NFL players, we have found that Achilles ruptures tend to occur at a higher rate during training camp, when athletes are deconditioned and quickly returning to explosive push-off activities. Physical examination should include a Thompson test, palpation of a gap within the tendon, and evaluation of resting ankle dorsiflexion in the affected extremity in the prone position with the knees bent. Lateral radiographs should be analyzed for the presence of a bony avulsion fragment indicative of an insertional avulsion injury or midsubstance calcium deposition reflecting chronic Achilles tendinosis, as both of these conditions will change surgical management. MRI is not recommended with acute midsubstance ruptures but may be helpful in the case of chronic ruptures or more proximal tears of the musculotendinous junction.

The management of acute midsubstance Achilles tendon ruptures is controversial, with no general consensus in the literature regarding non-operative treatment, surgical repair, and ideal repair technique.^{36,38-42} American Academy of Orthopaedic Surgeons clinical practice guidelines report moderate evidence that nonoperative treatment of Achilles tendon ruptures has lower wound healing complications but higher rates of re-rupture.^{38,39} Additionally, limited incision approaches have been found to have fewer overall complications compared with traditional open repair. In an effort to reduce the incidence of postoperative wound complications while improving functional recovery, modern repair techniques focus on a limited incision repair using percutaneous suture insertion and management (PARS Achilles Jig System, Arthrex).³⁶ The limited incision technique utilizes a 2-cm transverse incision and non-disposable jig

with divergent needle passes and locking suture fixation options to secure and fixate both tendon ends with minimal dissection of skin, subcutaneous tissue, and paratenon. Limited incision repair is ideally performed within 2 weeks of the injury to ensure that both tendon ends are easy to identify, mobilize, and repair. An open repair is generally recommended for midsubstance ruptures more than 4 weeks old and cases of insertional rupture and Achilles tendinopathy.

In a cohort of 9 NFL players treated for midsubstance Achilles ruptures using the PARS technique, we found no re-ruptures, no wound complications, and no sural nerve issues after surgery.⁴³ A comparative review of 270 cases of operatively treated Achilles tendon ruptures (101 PARS, 169 traditional open repair) showed that the PARS group had significantly shorter operative times and a higher number of patients able to return to baseline physical activities by 5 months compared to open repair.³⁶ Although not statistically significant, the overall PARS complication rate was 5% while the open complication rate was 11%. The PARS group had no cases of sural neuritis or deep infection requiring reoperation. We currently use a limited incision technique for all acute midsubstance Achilles ruptures in athletes regardless of sport, patient size, or position played.

During surgery, a 2-cm transverse incision is made over the gap in the Achilles tendon and dissection is carried down to the rupture site with minimal manipulation of the skin (**Figures 5A-5F**). A transverse incision is made through the paratenon and typically a hematoma is expressed. An Allis clamp is inserted and the proximal tendon stump is grabbed securely and pulled through the wound approximately 1 to 2 cm. The PARS jig is inserted around the proximal tendon and centered so that the needle and sutures will pass through tendon. Needles and sutures are passed in a stepwise fashion and then the entire jig is removed from the wound. Sutures are passed to create 2 non-locking and 1 locking suture. The jig and suture passing process is repeated for the distal tendon stump. Then, each pair of sutures is tied together with the ankle in maximum plantarflexion to obtain a secure end-to-end repair. The knots are cut short and tucked into tendon so that they do not protrude and cause subcutaneous tissue irritation. Absorbable sutures are used to close the paratenon, followed by closure of subcutaneous tissues and skin followed by placement of a short leg posterior mold NWB splint with the ankle in resting plantar flexion.

A key aspect of postoperative recovery is avoiding excessive ankle dorsiflexion while the tendon is healing during the first 4 weeks after surgery, as this can lead to an elongated tendon with loss of push-off strength. Patients are kept in a plantarflexion splint NWB for 2 weeks after surgery. If the incision is healed at 2 weeks, sutures are removed and patients are transitioned into a NWB tall CAM boot for 2 weeks with gentle ankle ROM exercises. If there is any concern regarding wound healing status, sutures are maintained for an additional 1 to 2 weeks.

From 4 to 8 weeks after surgery, progressive weight-bearing with continued ankle ROM exercises is initiated with peel-away heel lifts (~2 cm thick total, 3 layers). Each layer of the heel lift is gradually removed as pain allows every 2 to 3 days with the goal of being full weight-bearing with the foot flat at 6 weeks postoperative. Physical therapy focusing on ankle ROM and gentle Achilles stretch-

ing and strengthening is also started 6 weeks after surgery. From 8 to 12 weeks postoperative, patients are transitioned out of the tall CAM boot into normal, accommodative shoe wear with full weight-bearing. We avoid ankle dorsiflexion past neutral until 12 weeks after surgery, as overlengthening of the Achilles complex and the subsequent loss of push-off power can be devastating to running athletes. Activity levels are increased as tolerated, with no running or jumping from 12 to 16 weeks with full release to all activities after 16 weeks. RTP often takes 5 to 6 months after surgery, depending on the position played.

Dr. Hsu is Assistant Clinical Professor of Orthopaedic Surgery, Division of Foot and Ankle Surgery, University of California-Irvine Department of Orthopaedic Surgery, Orange, California. Dr. Anderson is Chief of Foot and Ankle Surgery, Team Physician, Carolina Panthers, OrthoCarolina Foot & Ankle Institute, Charlotte, North Carolina.

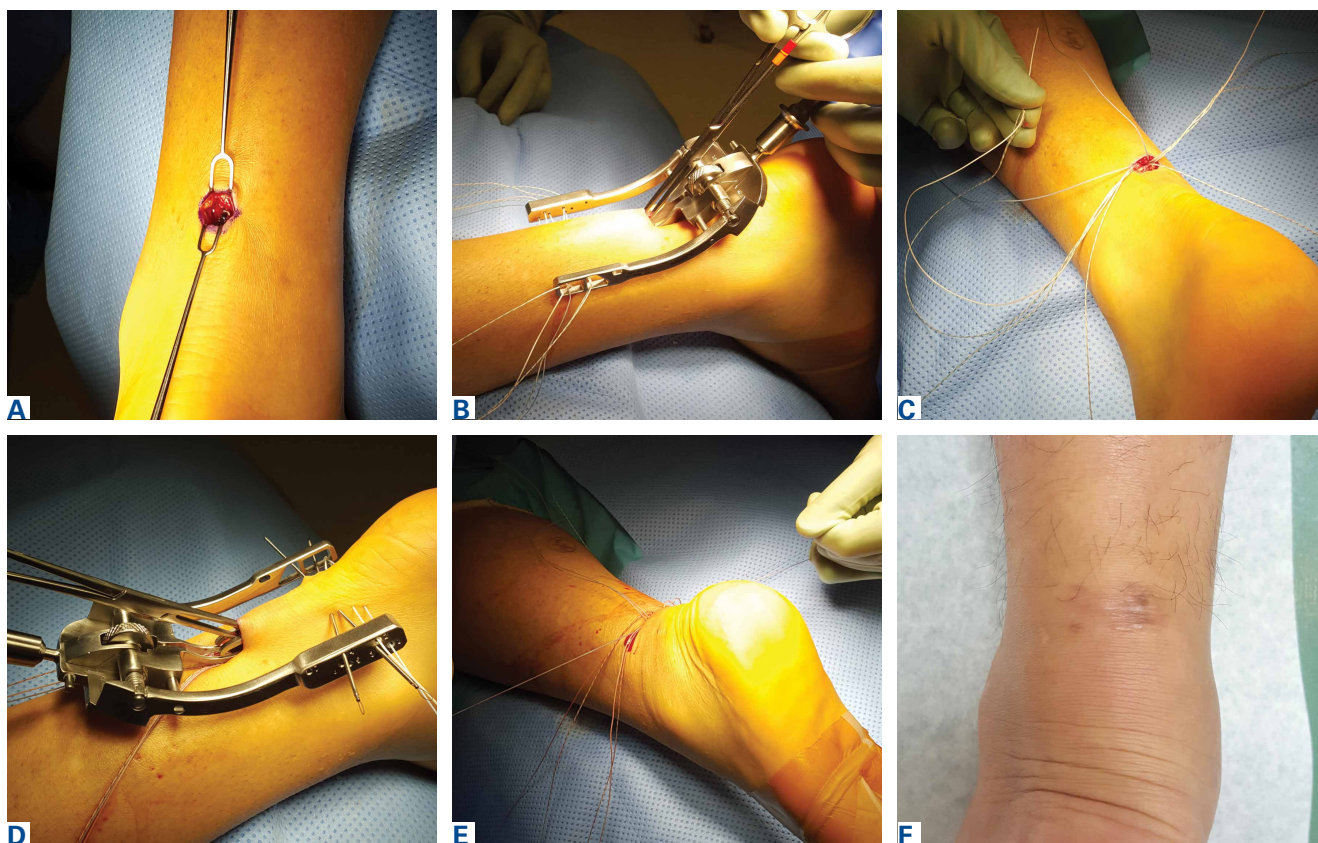


Figure 5. (A) The defect within the midsubstance of the Achilles is palpated followed by a 2-cm transverse skin incision in the center of the tendon. Dissection is carried down to paratenon that is then incised with visualization of hematoma from the rupture site. (B) The PARS (Arthrex) jig is inserted and advanced along the sides of the Achilles and the tendon is palpated and checked to be centered within the prongs of the jig. FiberWire (Arthrex) sutures are passed until all 5 standard sutures are passed through the jig. (C) The jig is removed and sutures are passed to create non-locking and locking sutures. (D) The above steps are repeated for the distal Achilles tendon stump. (E) Each pair of sutures is tied with the ankle in maximum plantarflexion. Paratenon, subcutaneous tissues, and skin are closed followed by placement of a non-weight-bearing splint in resting ankle plantarflexion. (F) Typical appearance of a healed incision 3 months after surgery as patients are transitioned back into regular athletic shoes with full weight-bearing.



Address correspondence to: Andrew R. Hsu, MD, Department of Orthopaedic Surgery, University of California-Irvine, 101 The City Drive South, Pavilion 3, Building 29A, Orange, CA 92868 (tel, 650-906-8923; fax, 714-456-7547; email, hsuar@uci.edu).

Am J Orthop. 2016;45(6):358-367. Copyright Frontline Medical Communications Inc. 2016. All rights reserved.

References

- Canale ST, Cantler ED Jr, Sisk TD, Freeman BL 3rd. A chronicle of injuries of an American intercollegiate football team. *Am J Sports Med.* 1981;9(6):384-389.
- Robey JM, Blyth CS, Mueller FO. Athletic injuries. Application of epidemiologic methods. *JAMA.* 1971;217(2):184-189.
- Saal JA. Common American football injuries. *Sports Med.* 1991;12(2):132-147.
- Thompson N, Halpern B, Curl WW, et al. High school football injuries: evaluation. *Am J Sports Med.* 1987;15(2):117-124.
- Kaplan LD, Jost PW, Honkamp N, Norwig J, West R, Bradley JP. Incidence and variance of foot and ankle injuries in elite college football players. *Am J Orthop.* 2011;40(1):40-44.
- DeLee JC, Farney WC. Incidence of injury in Texas high school football. *Am J Sports Med.* 1992;20(5):575-580.
- Brophy RH, Barnes R, Rodeo SA, Warren RF. Prevalence of musculoskeletal disorders at the NFL Combine—trends from 1987 to 2000. *Med Sci Sports Exerc.* 2007;39(1):22-27.
- Bowers KD Jr, Martin RB. Turf-toe: a shoe-surface related football injury. *Med Sci Sports.* 1976;8(2):81-83.
- McCormick JJ, Anderson RB. Turf toe: anatomy, diagnosis, and treatment. *Sports Health.* 2010;2(6):487-494.
- Raikin SM, Slenker N, Ratigan B. The association of a varus hindfoot and fracture of the fifth metatarsal metaphyseal-diaphyseal junction: the Jones fracture. *Am J Sports Med.* 2008;36(7):1367-1372.
- Title CI, Katchis SD. Traumatic foot and ankle injuries in the athlete. *Orthop Clin North Am.* 2002;33(3):587-598.
- Quill GE Jr. Fractures of the proximal fifth metatarsal. *Orthop Clin North Am.* 1995;26(2):353-361.
- Nunley JA, Glisson RR. A new option for intramedullary fixation of Jones fractures: the Charlotte Carolina Jones Fracture System. *Foot Ankle Int.* 2008;29(12):1216-1221.
- Lareau CR, Hsu AR, Anderson RB. Return to play in National Football League players after operative Jones fracture treatment. *Foot Ankle Int.* 2016;37(1):8-16.
- Larson CM, Almekinders LC, Taft TN, Garrett WE. Intramedullary screw fixation of Jones fractures. Analysis of failure. *Am J Sports Med.* 2002;30(1):55-60.
- Portland G, Kelikian A, Kodros S. Acute surgical management of Jones' fractures. *Foot Ankle Int.* 2003;24(11):829-833.
- Hunt KJ, Anderson RB. Treatment of Jones fracture nonunions and refractures in the elite athlete: outcomes of intramedullary screw fixation with bone grafting. *Am J Sports Med.* 2011;39(9):1948-1954.
- Nunley JA, Vertullo CJ. Classification, investigation, and management of midfoot sprains: Lisfranc injuries in the athlete. *Am J Sports Med.* 2002;30(6):871-878.
- Alberta FG, Aronow MS, Barrero M, Diaz-Doran V, Sullivan RJ, Adams DJ. Ligamentous Lisfranc joint injuries: a biomechanical comparison of dorsal plate and transarticular screw fixation. *Foot Ankle Int.* 2005;26(6):462-473.
- Ardoin GT, Anderson RB. Subtle Lisfranc injury. *Tech Foot Ankle Surg.* 2010;9(3):100-106.
- Kuo RS, Tejwani NC, Digiovanni CW, et al. Outcome after open reduction and internal fixation of Lisfranc joint injuries. *J Bone Joint Surg Am.* 2000;82-A(11):1609-1618.
- Wright RW, Barile RJ, Surprenant DA, Matava MJ. Ankle syndesmosis sprains in national hockey league players. *Am J Sports Med.* 2004;32(8):1941-1945.
- Williams GN, Jones MH, Amendola A. Syndesmotank sprains in athletes. *Am J Sports Med.* 2007;35(7):1197-1207.
- Beumer A, Valstar ER, Garling EH, et al. Effects of ligament sectioning on the kinematics of the distal tibiofibular syndesmosis: a radiostereometric study of 10 cadaveric specimens based on presumed trauma mechanisms with suggestions for treatment. *Acta Orthop.* 2006;77(3):531-540.
- McCollum GA, van den Bekerom MP, Kerkhoffs GM, Calder JD, van Dijk CN. Syndesmosis and deltoid ligament injuries in the athlete. *Knee Surg Sports Traumatol Arthrosc.* 2013;21(6):1328-1337.
- Boytime MJ, Fischer DA, Neumann L. Syndesmotank ankle sprains. *Am J Sports Med.* 1991;19(3):294-298.
- Nussbaum ED, Hosea TM, Sieler SD, Incremona BR, Kessler DE. Prospective evaluation of syndesmotank ankle sprains without diastasis. *Am J Sports Med.* 2001;29(1):31-35.
- Kiter E, Bozkurt M. The crossed-leg test for examination of ankle syndesmosis injuries. *Foot Ankle Int.* 2005;26(2):187-188.
- Beumer A, van Hemert WL, Swierstra BA, Jasper LE, Belkoff SM. A biomechanical evaluation of clinical stress tests for syndesmotank ankle instability. *Foot Ankle Int.* 2003;24(4):358-363.
- Amendola A, Williams G, Foster D. Evidence-based approach to treatment of acute traumatic syndesmosis (high ankle) sprains. *Sports Med Arthrosc.* 2006;14(4):232-236.
- Beumer A, Valstar ER, Garling EH, et al. External rotation stress imaging in syndesmotank injuries of the ankle: comparison of lateral radiography and radiostereometry in a cadaveric model. *Acta Orthop Scand.* 2003;74(2):201-205.
- Marmor M, Hansen E, Han HK, Buckley J, Matiyahu A. Limitations of standard fluoroscopy in detecting rotational malreduction of the syndesmosis in an ankle fracture model. *Foot Ankle Int.* 2011;32(6):616-622.
- Williams GN, Allen EJ. Rehabilitation of syndesmotank (high) ankle sprains. *Sports Health.* 2010;2(6):460-470.
- Westermann RW, Rungprai C, Goetz JE, Femino J, Amendola A, Phisitkul P. The effect of suture-button fixation on simulated syndesmotank malreduction: a cadaveric study. *J Bone Joint Surg Am.* 2014;96(20):1732-1738.
- Hsu AR, Lareau CR, Anderson RB. Repair of acute superficial deltoid complex avulsion during ankle fracture fixation in National Football League players. *Foot Ankle Int.* 2015;36(11):1272-1278.
- Hsu AR, Jones CP, Cohen BE, Davis WH, Ellington JK, Anderson RB. Clinical outcomes and complications of percutaneous Achilles repair system versus open technique for acute achilles tendon ruptures. *Foot Ankle Int.* 2015;36(11):1279-1286.
- Raikin SM, Garras DN, Krapchev PV. Achilles tendon injuries in a United States population. *Foot Ankle Int.* 2013;34(4):475-480.
- Chiodo CP, Glazebrook M, Bluman EM, et al. American Academy of Orthopaedic Surgeons clinical practice guideline on treatment of achilles tendon rupture. *J Bone Joint Surg Am.* 2010;92(14):2466-2468.
- Chiodo CP, Glazebrook M, Bluman EM, et al. Diagnosis and treatment of acute achilles tendon rupture. *J Am Acad Orthop Surg.* 2010;18(8):503-510.
- Khan RJ, Fick D, Keogh A, Crawford J, Brammar T, Parker M. Treatment of acute achilles tendon ruptures. A meta-analysis of randomized, controlled trials. *J Bone Joint Surg Am.* 2005;87(10):2202-2210.
- Renninger CH, Kuhn K, Fellars T, Youngblood S, Bellamy J. Operative and nonoperative management of achilles tendon ruptures in active duty military population. *Foot Ankle Int.* 2016;37(3):269-273.
- Khan RJ, Carey Smith RL. Surgical interventions for treating acute achilles tendon ruptures. *Cochrane Database Syst Rev.* 2010;(9):CD003674.
- McCullough KA, Shaw CM, Anderson RB. Mini-open repair of achilles rupture in the national football league. *J Surg Orthop Adv.* 2014;23(4):179-183.

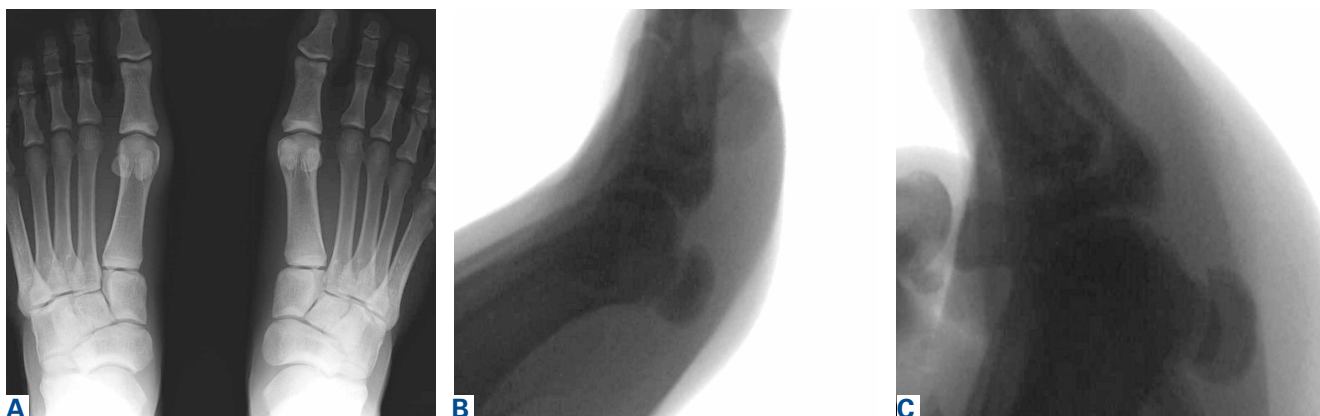

Figure W1. (A) Standing anteroposterior radiograph of bilateral feet showing left hallux turf toe with proximal sesamoid retraction compared with normal sesamoid position on the right hallux. (B) Lateral live fluoroscopic image of the sesamoids under the metatarsal head at rest and (C) after forced hallux metatarsophalangeal dorsiflexion showing failure of the sesamoids to track distally, thus indicating rupture of the capsule ligamentous complex.

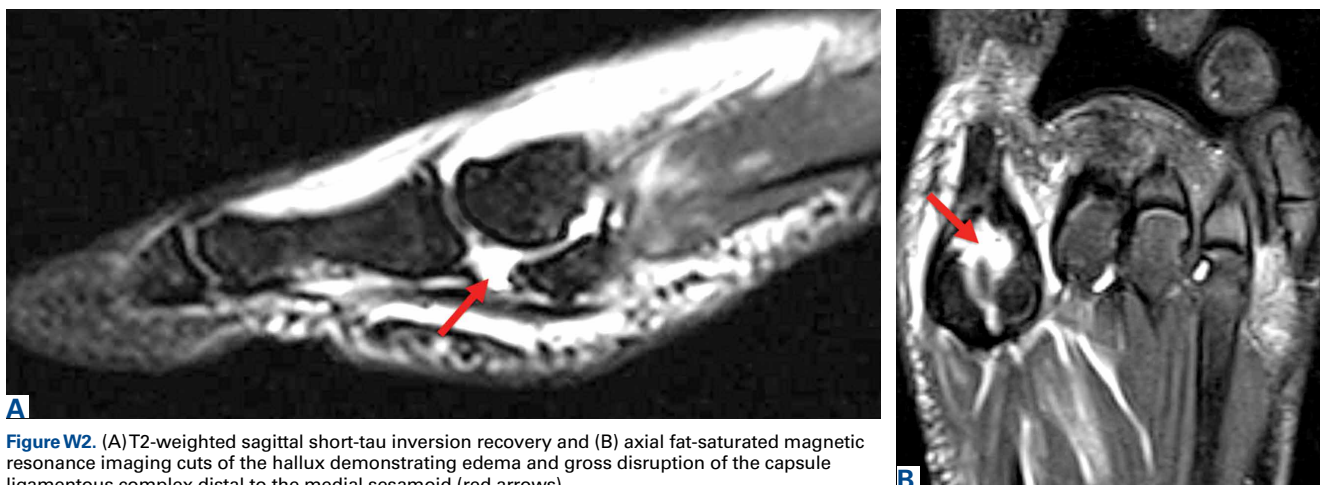


Figure W2. (A) T2-weighted sagittal short-tau inversion recovery and (B) axial fat-saturated magnetic resonance imaging cuts of the hallux demonstrating edema and gross disruption of the capsule ligamentous complex distal to the medial sesamoid (red arrows).

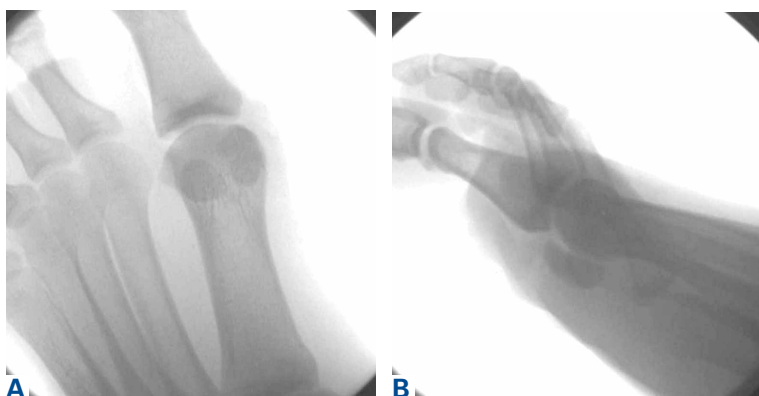

Figure W3. (A) Intraoperative anteroposterior and (B) lateral fluoroscopy after turf toe repair should demonstrate anatomic reduction of the sesamoids relative to the metatarsophalangeal joint and a location more distal than before surgery.

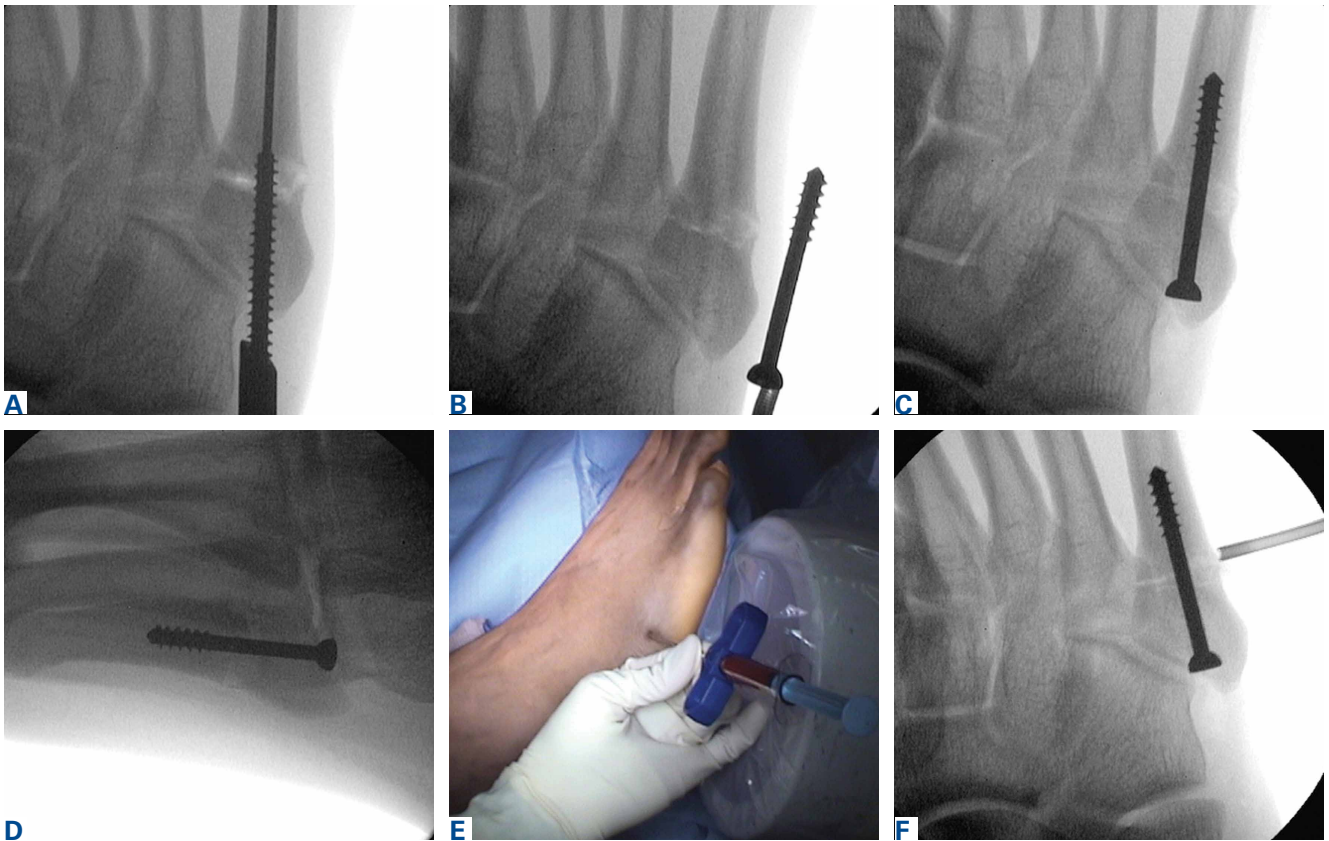


Figure W4. (A) Anteroposterior radiograph of 5.5-mm tap over guidewire across the fracture site. The entire length of the final screw must be tapped to ensure proper distal fit. (B) Solid-core stainless steel screw is held next to skin to estimate final screw length and placement, making sure that screw threads are just beyond the fracture site to maximize compression. (C) Screw is inserted into the canal securely with low-profile head flush with bone to avoid cuboid impingement. (D) Lateral radiograph is taken to confirm proper screw alignment. (E) In elite athletes and revision cases, bone marrow aspirate is spun down into bone marrow concentrate and mixed with demineralized bone matrix and injected in and around the fracture site with (F) fluoroscopic confirmation of trochar placement.

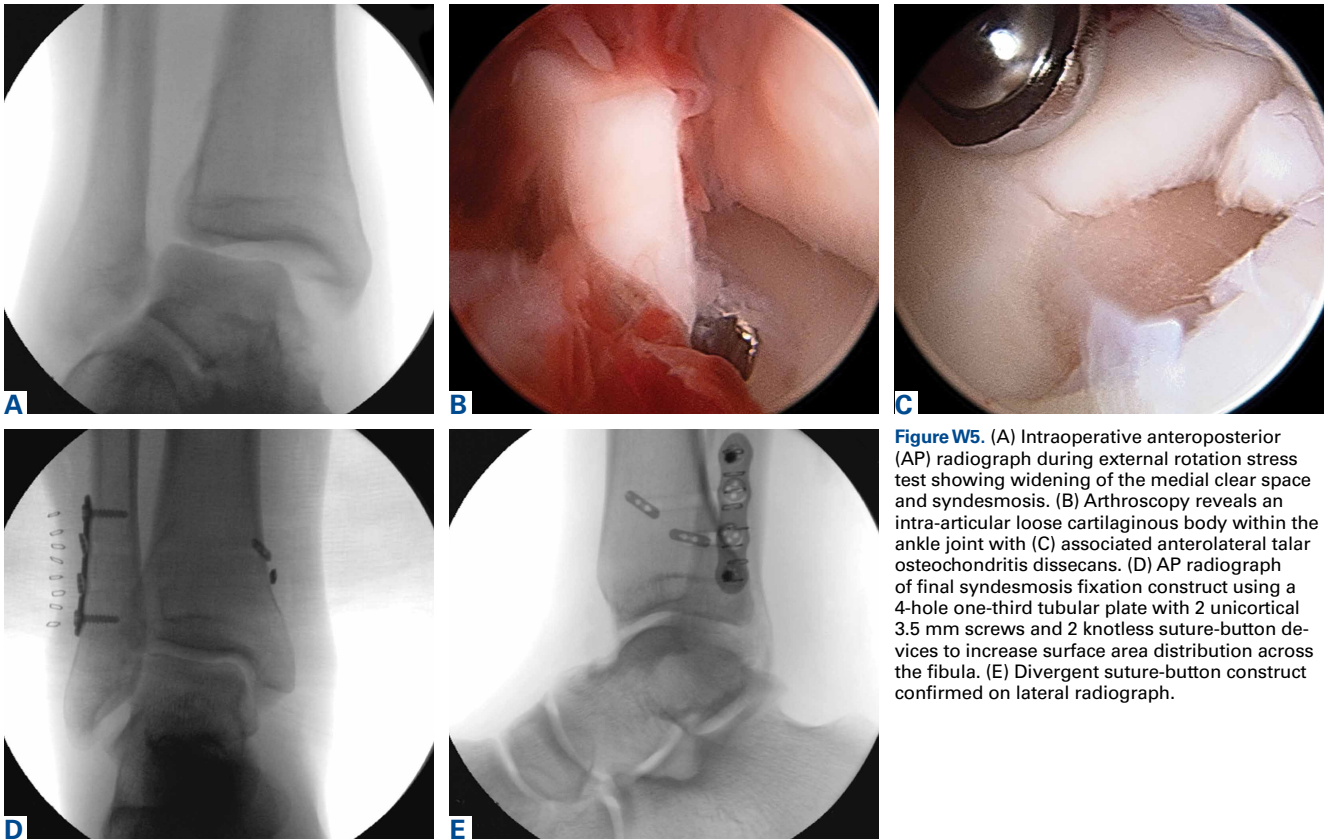


Figure W5. (A) Intraoperative anteroposterior (AP) radiograph during external rotation stress test showing widening of the medial clear space and syndesmosis. (B) Arthroscopy reveals an intra-articular loose cartilaginous body within the ankle joint with (C) associated anterolateral talar osteochondritis dissecans. (D) AP radiograph of final syndesmosis fixation construct using a 4-hole one-third tubular plate with 2 unicortical 3.5 mm screws and 2 knotless suture-button devices to increase surface area distribution across the fibula. (E) Divergent suture-button construct confirmed on lateral radiograph.

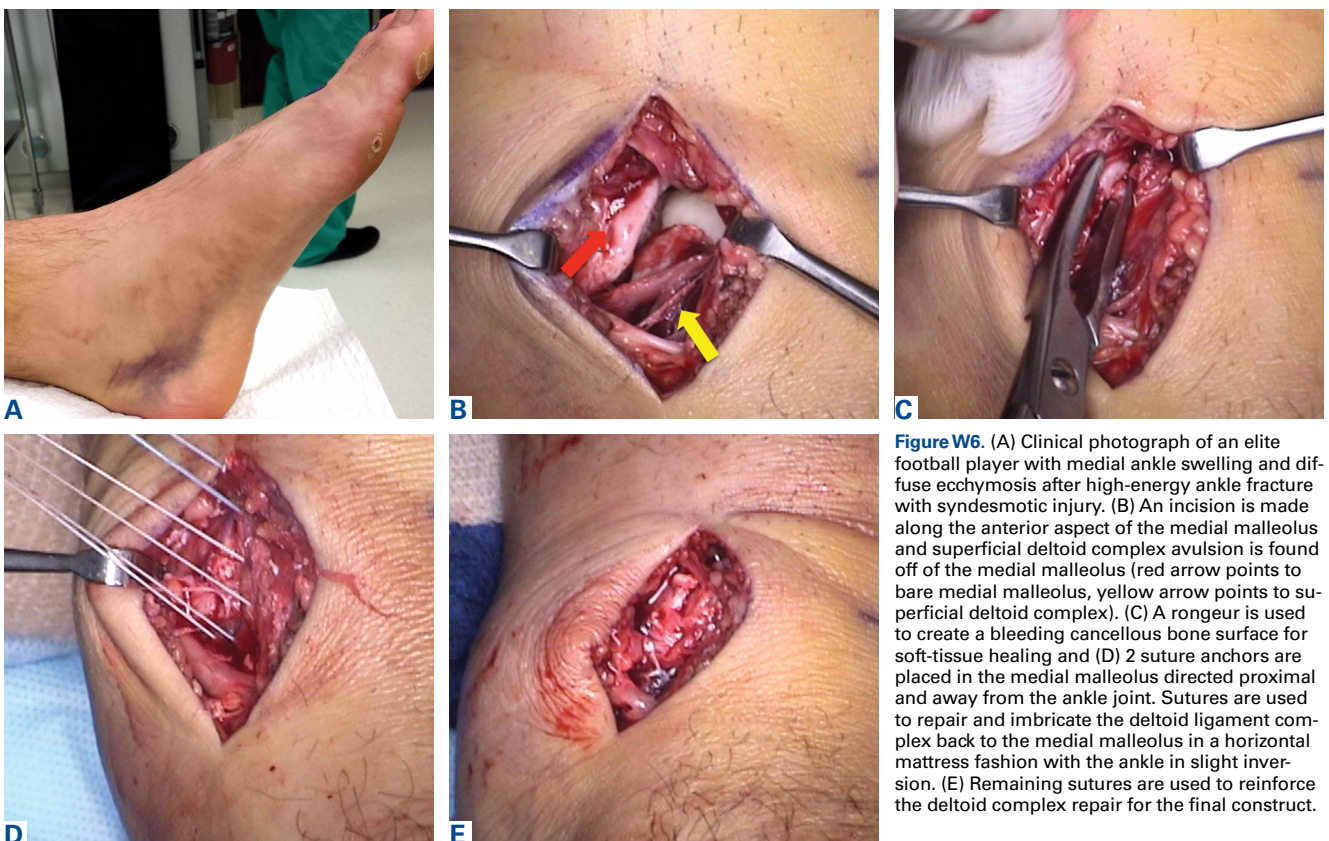


Figure W6. (A) Clinical photograph of an elite football player with medial ankle swelling and diffuse ecchymosis after high-energy ankle fracture with syndesmotic injury. (B) An incision is made along the anterior aspect of the medial malleolus and superficial deltoid complex avulsion is found off of the medial malleolus (red arrow points to bare medial malleolus, yellow arrow points to superficial deltoid complex). (C) A rongeur is used to create a bleeding cancellous bone surface for soft-tissue healing and (D) 2 suture anchors are placed in the medial malleolus directed proximal and away from the ankle joint. Sutures are used to repair and imbricate the deltoid ligament complex back to the medial malleolus in a horizontal mattress fashion with the ankle in slight inversion. (E) Remaining sutures are used to reinforce the deltoid complex repair for the final construct.