

Surgical Pearls in Total Knee Arthroplasty: A Lifetime of Lessons Learned

Richard D. Scott, MD

Abstract

Total knee arthroplasty (TKA) has evolved into a very successful procedure to relieve pain and improve function in the patient with advanced arthritis. Both short- and long-term outcomes are dependent on optimal surgical technique. In this article, I share a few of the many lessons learned over more than 40 years of experience performing TKA regarding exposure, alignment, bone preparation, correction of deformity, and prosthetic implantation.

After over 4 decades of experience with total knee arthroplasty (TKA), I have learned many lessons regarding surgical technique. These include exposure issues, align-

ment methods, bone preparation, correction of deformity, and implantation techniques. Most of these lessons have been self-taught, but some have been suggested by or modified from colleague and student interaction. Attribution is given when possible.

The Incision

The skin incision should be marked in flexion rather than extension because the skin moves approximately 1 cm laterally from extension to flexion.¹ This occurs because the tibia internally rotates beneath the skin as the knee is flexed and externally rotates as full extension is achieved. This lateral movement of the skin could bring an incision marked in extension on top of the tibial tubercle when the knee is flexed and may result in pain and dysfunction when the patient attempts to kneel. A review of kneeling ability after TKA showed that most patients are hesitant to kneel initially after their arthroplasty, but gain confidence and improved comfort and ability as their scar matures.²

Exposure

Patellar eversion can be difficult in a markedly obese or ankylosed knee, especially when the patella is difficult to grasp. This is facilitated by the use of a standard patellar clamp that is normally used to compress the patella during component cementation (**Figure 1**).³ When using this technique, remember to protect the patellar tendon from avulsion by using the techniques described below.

Exposing the Ankylosed Knee and Protecting the Patellar Tendon From Avulsion

A tibial tubercle osteotomy is often recommended in the ankylosed knee but can be avoided by making a short inverted "V" incision in the proximal quadriceps tendon (**Figure 2**).⁴ This

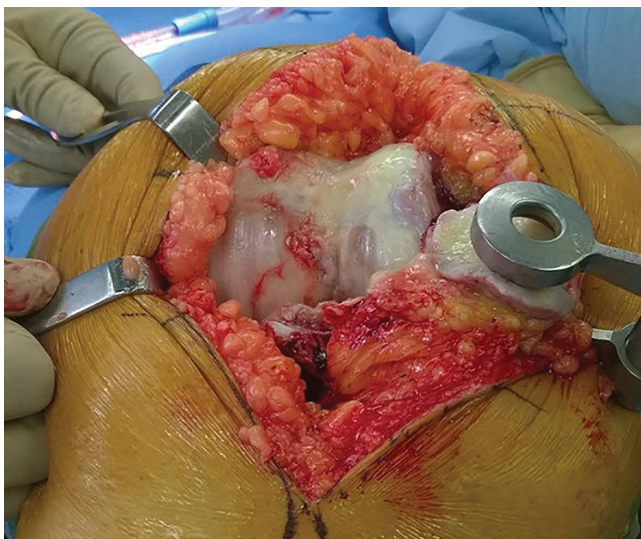


Figure 1. A clamp normally used to compress the patella during cementing is used to grasp the native patella and facilitate eversion in a morbidly obese patient.

Author's Disclosure Statement: Dr. Scott reports that he is a paid consultant for Medtronic, Inc.

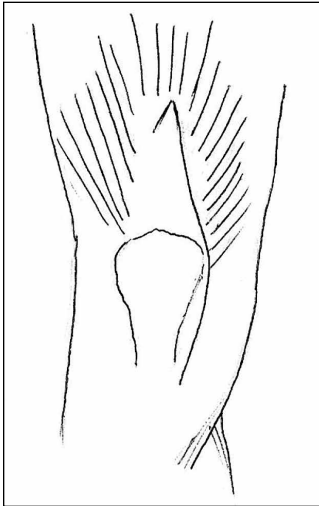


Figure 2. A short inverted “V” incision in the proximal quadriceps tendon facilitates patellar eversion in the ankylosed knee, or in revision cases, allows access to lateral parapatellar scar tissue and relieves tension on the patellar tendon insertion.

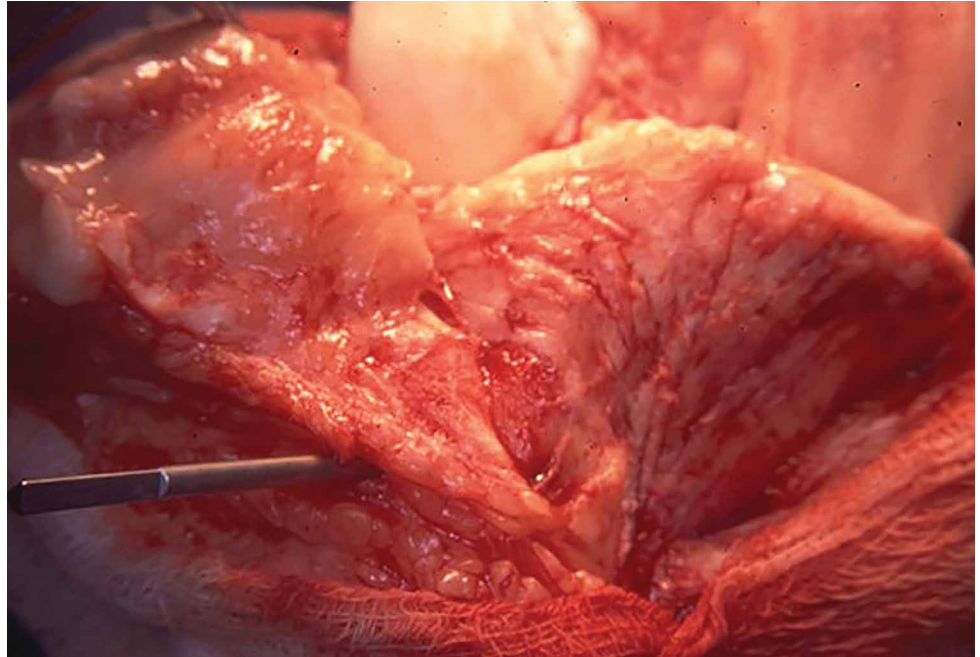


Figure 3. A smooth 1/8-inch pin further protects the patellar tendon insertion.

maneuver, along with a smooth 1/8-inch pin in the tibial tubercle, also protects the patellar tendon from avulsing (**Figure 3**). The patella can be easily everted and access to the lateral parapatellar scar tissue allows a lateral release to be performed from inside out to further mobilize the knee and enhance exposure. The inverted “V” incision can be closed anatomically, and no modifications of the postoperative physical therapy program are necessary.

Protecting the Soft Tissues During Surgery

Moist wound towels sewn into the joint capsule protect the underlying soft tissues from debris and desiccation during the procedure and will intuitively lower the chance of wound infection from contamination and tissue injury (**Figures 4A, 4B**). Since I have done this routinely in both hip and knee arthroplasty over the last 7000 consecutive primary arthroplasties, I have had no operative deep infections. This experience is without the use of antibiotics in the bone cement.

Locating and Coagulating the Lateral Inferior Genicular Vessels

The lateral inferior genicular artery and vein can be easily located and coagulated just outside the posterior rim of the lateral meniscus near

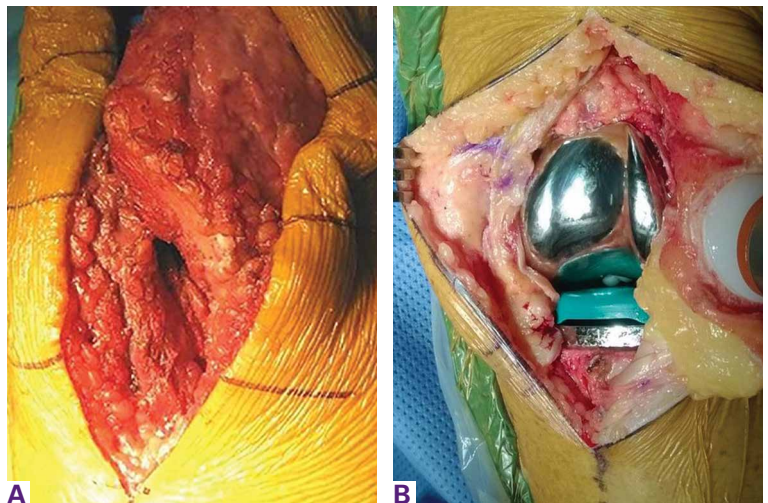


Figure 4. (A) Wounds that are unprotected with moist towels during surgery allow desiccation of the tissues to occur and are intuitively more prone to infection in the presence of any contamination. (B) The soft tissues that are protected by moist wound towels during surgery are intuitively less vulnerable to contamination.

the popliteus hiatus. This will minimize both intraoperative and postoperative blood loss.

Determining the Entry Point in the Distal Femur for Intramedullary Alignment Devices

Templating the femoral entry point for insertion of an intramedullary alignment device on a preoperative radiograph will help avoid inadver-

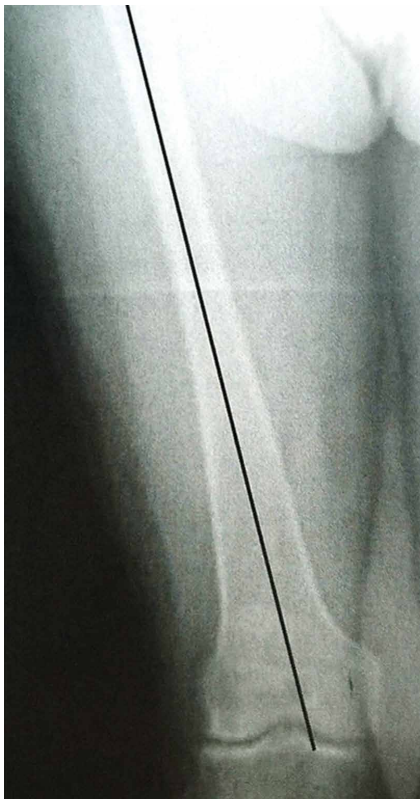

Figure 5. The entry hole for intramedullary alignment devices should be templated on a preoperative roentgenogram. Its placement will affect the valgus angle chosen to reproduce the desired distal femoral resection angle.

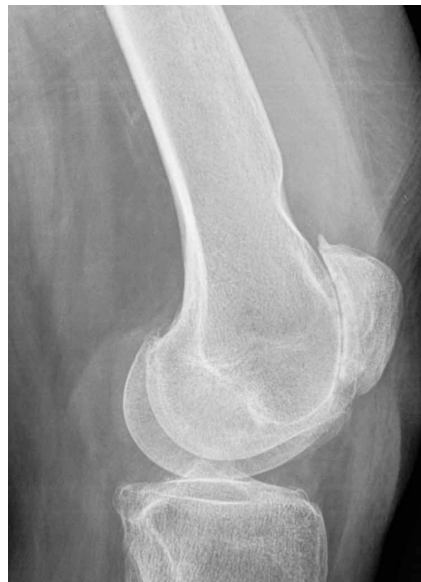

Figure 6. In knees with a dysplastic shallow trochlea, the distal femoral resection is best made in a few degrees of flexion to avoid notching the anterior femoral cortex.

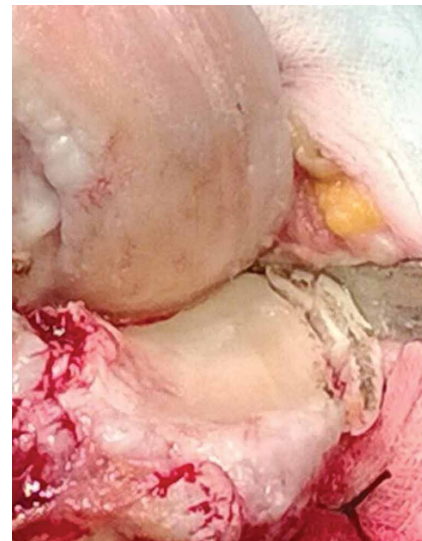

Figure 7. Resection of a variable amount of the peripheral rim of the medial tibial cortex (depending on the extent of the deformity) will accomplish a medial release by shortening the distance between the origin and insertion of the medial collateral ligament.

tent excessive distal femoral valgus resection. This is especially important in valgus knees that have a valgus metaphyseal bow (**Figure 5**). In these cases, the entry point must be moved medially and/or the valgus angle chosen must be diminished.

Avoiding Notching of the Anterior Femoral Cortex

Notching the anterior femoral cortex when in-between femoral sizes or when there is a preexisting dysplastic or shallow trochlea (**Figure 6**) can be avoided by making the distal femoral resection in an extra 3° of flexion. In most TKA systems, the prosthetic trochlear flange diverges 3° or 4° away from the posterior femoral condyles. If the distal femoral resection is made in an extra 3° of flexion, the femoral component utilized can be anatomically sized off the patient's posterior femoral condyles and the diverging trochlear flange will avoid notching the anterior femoral cortex while providing increased surface contact with the trochlear bone, enhanc-

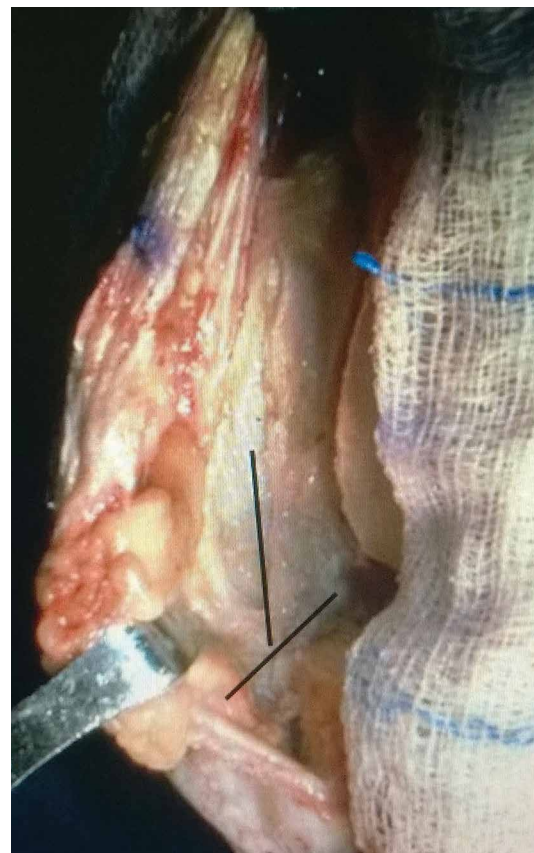


Figure 8. An inverted cruciform release of the lateral retinaculum accomplishes an effective lateral release in the valgus knee and usually avoids the need to release the lateral collateral ligament.

ing prosthetic fixation. The only potential adverse effects of increased femoral component flexion would occur in a system that does not allow hyperextension of the femoral/tibial articulation without loss of articular contact or in a posterior-stabilized articulation where there could be post impingement in hyperextension. Total knee systems vary in the amount of hyperextension that can be tolerated.

Obtaining a Medial Release by Removing Peripheral Medial Tibial Bone

Varus deformities can be corrected without performing a formal medial collateral ligament (MCL) release by a so-called reduction tibial osteotomy.^{5,6} In mild varus deformity, sufficient medial release can be achieved by removing medial femoral and tibial peripheral osteophytes that tent up the MCL and medial capsule. When this is insufficient, removal of additional peripheral tibial bone further shortens the distance between the origin and insertion of the MCL, effectively lengthening the ligament (**Figure 7**).

An Inverted Cruciform Lateral Retinacular Release to Correct Severe Valgus Deformity

An inverted cruciform lateral retinacular release effectively corrects a severe valgus deformity and avoids the need for a lateral collateral ligament (LCL) release.⁷ The release is best done after bone resection but without trial components in place, because this facilitates exposure to the lateral retinaculum (**Figure 8**). The lateral superior genicular vessels should be identified and preserved. The vertical part of the release begins distal to the vessels and ends at the tibial resection. The horizontal limbs extend posteriorly short of the LCL and anteriorly short of the patellar tendon. If the extent of this release does not sufficiently balance the knee, it can be propagated by placing trial components with an insert thickness that stabilizes the medial side. Under this circumstance, the tight lateral side will now prohibit full passive extension. With gentle manipulation of the knee into extension, the lateral release will be propagated to its appropriate length. Postoperative perineal nerve palsies are rare with this technique. Immediate postoperative assessment, however, should always be done and the patient's dressing loosened and their knee placed in flexion if there

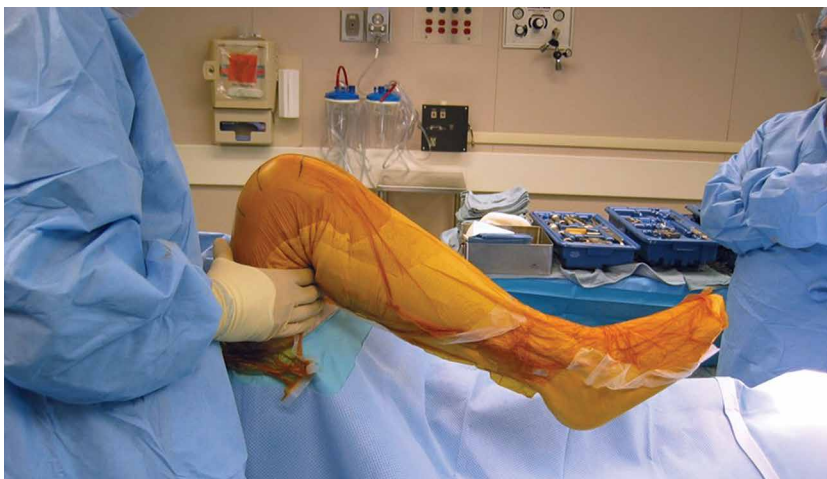

Figure 9. Flexion against gravity after capsular closure should be measured and recorded. This (not preoperative flexion) is the best indicator of a patient's potential flexion after full recovery.

is any concern. Almost all of these rare palsies make a complete recovery.

Relieving Posterior Femoral Impingement

Uncapped posterior condylar bone or retained posterior osteophytes can limit both flexion and extension and cause impingement. Trimming the posterior femoral condyles and removing posterior osteophytes is best accomplished using a trial femoral component as a template.⁴ A curved osteotome is passed tangential to the metallic condyles to define the bone requiring resection. After removal of the trial, the outlined bone can be easily and accurately resected.

Minimizing Postoperative Posterior Condylar Bone-Cement Radiolucencies

Zone 4 femoral bone-cement radiolucencies⁸ can be minimized using the "smear" technique.⁴ These radiolucencies are common because most prosthetic femoral components have posterior condyles that are parallel to the femoral fixation lugs and do not allow for compression of this interface during implantation. Most surgeons put no cement on the posterior condylar bone but place it on the inside of the prosthetic condyle instead. The lack of compression upon insertion leads to a poor interface and the resultant lucencies. In the long term, these lucencies could allow access of wear debris to the posterior condylar bone, with the potential for osteolysis and loosening. To improve this interface, cement can be smeared or packed into the posterior condyles and also placed on the posterior condyles of the prosthesis. This could lead to posterior extrusion of some cement

during polymerization, so a removable trial insert should be utilized to allow access posteriorly after polymerization is complete.

Predicting Potential Postoperative Flexion

The best indicator of potential postoperative flexion for any individual patient is not pre-operative flexion but is intraoperative flexion against gravity measured after capsular closure.⁹ Surgeons should measure and record this value for reference if a patient has difficulty regaining flexion during their recovery (**Figure 9**). If a patient had 120° of flexion against gravity after capsular closure but achieves only 80° at 2 months, a knee manipulation is probably indicated. If their flexion after closure was only 80°, a manipulation is unlikely to lead to any improvement.

Summary

The short- and long-term success of TKA is highly dependent on surgical technique that allows proper and safe exposure under all circumstances, correction of deformity, and accurate component implantation while minimizing intraoperative and postoperative complications. The surgical pearls shared above will hopefully aid in achieving these goals.

Dr. Scott is a Professor of Orthopedic Surgery, Emeritus, Harvard Medical School, Boston, Massachusetts.

Address correspondence to: Richard D. Scott, MD (email, rdscottmd@gmail.com).

Am J Orthop. 2016;45(6):384-388. Copyright Frontline Medical Communications Inc. 2016. All rights reserved.

References

1. Yacoubian SV, Scott RD. Skin incision translation in total knee arthroplasty: the difference between flexion and extension. *J Arthroplasty.* 2007;22(3):353-355.
2. Schai PA, Gibbon AJ, Scott RD. Kneeling ability after total knee arthroplasty. Perception and reality. *Clin Orthop Relat Res.* 1999;367:195-200.
3. Springorum HP, Scott RD. A technique to facilitate everting the patella in stiff or obese knees in total knee arthroplasty. *Am J Orthop.* 2009;38(10):507-508.
4. Scott RD. *Total Knee Arthroplasty.* 2nd ed. Philadelphia, PA: Elsevier; 2014.
5. Dixon MC, Parsch D, Brown RR, Scott RD. The correction of severe varus deformity in total knee arthroplasty by tibial component downsizing and resection of uncapped proximal medial bone. *J Arthroplasty.* 2004;19(1):19-22.
6. Mullaji AB, Padmanabhan V, Jindal G. Total knee arthroplasty for profound varus deformity: technique and radiological results in 173 knees with varus of more than 20 degrees. *J Arthroplasty.* 2005;20(5):550-561.
7. Politi J, Scott RD. Balancing severe valgus deformity in total knee arthroplasty using a lateral cruciform retinacular release. *J Arthroplasty.* 2004;19(5):553-557.
8. Huddleston JI, Wiley JW, Scott RD. Zone 4 femoral radiolucent lines in hybrid versus cemented total knee arthroplasties: are they clinically significant? *Clin Orthop Relat Res.* 2005;441:334-339.
9. Lee DC, Kim DH, Scott RD, Suthers K. Intraoperative flexion against gravity as an indication of ultimate range of motion in individual cases after total knee arthroplasty. *J Arthroplasty.* 1998;13(5):500-503.