

A Modified Levering Technique for Removing a Broken Solid Intramedullary Tibial Nail: A Technical Tip

W. Michael Pullen, MD, Nicholas J. Erdle, MD, Colin Crickard, MD, and Christopher S. Smith, MD

Abstract

Intramedullary tibial fixation is a commonly used and highly successful treatment in acute fractures, nonunion settings, and correctional procedures. In the setting of a nonunion, removal of a failed implant can add to operative time and surgeon frustration while further compromising bone in an area already at risk for failure. Here we present a technique, using readily accessible equipment, for removing a distal solid tibial nail fragment in a manner that preserves bone.

In both elective and revision surgery, removal of retained hardware can be unpredictable. Broken hardware, whether identified before or during

surgery, presents a significant challenge. Cases often require enlisting a large variety of equipment and techniques that often result in larger dissection and potential for wider soft-tissue or bony destruction. Broken intramedullary devices, located entirely within the cortices of bone, pose unique challenges.^{1,2} Various techniques have been used to remove broken cannulated nails.¹⁻⁹ There is, however, a paucity of techniques for removing broken solid nails from within the tibia.^{1,2} Moreover, many of these techniques require significant metaphyseal and cortical bone destruction that may compromise the integrity of the long bone.^{1,3,9} In this article, we describe a modified technique for removal of a broken solid nail, with minimal cortical bone destruction, in the setting of a tibial nonunion.

Technique

A 23-year-old man presented with a symptomatic valgus nonunion of the tibia, which had been treated with a solid intramedullary 9-mm nail (Orthofix). The patient was taken to the operative theater for nonunion takedown and exchanged reamed intramedullary nailing. The proximal fragment of the anterograde intramedullary nail was removed in standard fashion using the Winqvist Universal Extraction Set (Shukla Medical). When threading the extractor into the proximal aspect of the nail, we found it helpful to leave one of the cross-locks in place to prevent nail rotation.¹⁰ Inspection of the removed nail revealed a fracture of the device at the more proximal of 2 distal cross-locks (Figures 1A, 1B, 2). The nonunion was then approached and taken down in standard fashion.

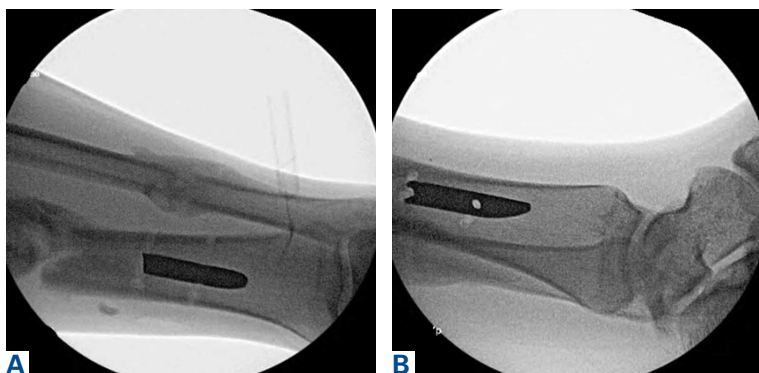


Figure 1. (A) Anteroposterior and (B) lateral fluoroscopic images of distal tibia and fibula show retained distal component of broken solid tibial nail.

Authors' Disclosure Statement: The authors report no actual or potential conflict of interest in relation to this article. The views expressed in this article are those of the author(s) and do not necessarily reflect the official policy or position of the Department of the Navy, Department of Defense or the United States Government. The authors are military service members. This work was prepared as part of Dr. Pullen's official duties. Title 17 U.S.C. 105 provides that 'Copyright protection under this title is not available for any work of the United States Government.' Title 17 U.S.C. 101 defines a United States Government work as a work prepared by a military service member or employee of the United States Government as part of that person's official duties.

Malalignment was corrected, and a guide wire was passed to the level of the broken distal fragment of the nail. Reamers were then passed through the intramedullary canal to the level of the broken implant, with the final reamer measuring 12.5 mm. We therefore reamed 3.5 mm larger than the diameter of the original nail to ultimately place the nail 2 mm larger in diameter than the broken one. A cross-lock was again left in place, this time to prevent further impaction of the distal fragment into the canal.

To remove the distal fragment of the nail, we used a 5.0-mm smooth Steinmann pin. After cross-lock removal, the pin was placed unicortically through the distal medial cortex at the tip of the retained implant. The distal nail fragment was pushed proximally using the pin as a lever with the interposed cortical bone serving as a fulcrum (**Figures 3A, 3B**). Additional fulcrum points were then selected proximally using the existing cortical defects from the previously placed cross-locking screws, minimizing destruction of cortical bone. The retained nail was then pushed proximally toward the nonunion site with windows spaced at intervals of about 1 cm. Thus, with the window we created distally, and the 2 cortical windows previously occupied by cross-locking screws, we were able to move the nail fragment about 3 cm proximally, where it could be reached and removed with Kocher forceps. Figure 2 shows the removed fragment.

Discussion

Removal of broken solid intramedullary tibial nails presents orthopedic surgeons with a unique challenge. We have described a technique that modifies and incorporates previously described techniques while exploiting available surgical windows to facilitate hardware removal. This technique obviates the need for further bony and soft-tissue dissection, potentially mitigating surgical morbidity.

Other techniques for removing broken solid intramedullary devices have been reported. Krettek and colleagues⁷ described a technique in which the short distal fragment of a broken solid femoral intramedullary nail was removed with use of retrograde levering through a cortical window just proximal to the articular surface. The same window was then used for anterograde nail removal with a small Hohmann retractor serving as a guide. This technique is limited by the need for a large bony window, which potentially creates a stress riser within the distal segment. In addition, a short,

distal nail fragment is required in order to facilitate manipulation through the metaphyseal bone. This technique is more readily used within the distal femur, given the large metaphyseal volume, in contrast with the distal tibial metaphysis. Giannoudis and colleagues¹ described a method (for both tibia and femur) in which the intramedullary canal was



Figure 2. Intraoperative photograph of removed portions of solid nail, which had broken at proximal distal cross-lock.

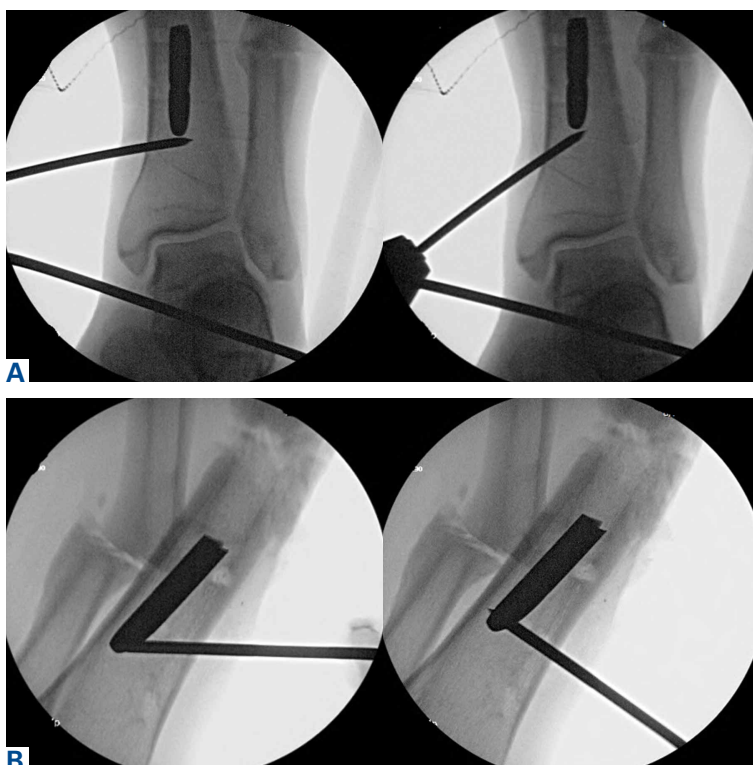

Figure 3. (A) Anteroposterior and (B) lateral radiographs show levering technique with medial cortex used as fulcrum. Nail being pushed by smooth pin can be visualized moving proximally.

proximally reamed to permit retrograde removal of an anterograde nail. The authors described reaming the canal to 4 mm larger than the nail to create access for a cleaning trephine and then a ratcheting extractor. This technique can be easily applied to the tibia or femur but requires special equipment that may not be readily available. Other retrograde techniques for the femur⁹ are not as suitable for the tibia, as they would cause significant chondral damage to the tibiotalar joint.

In developing our technique, which includes modifications of other methods, we used cortical windows, levering, and anterograde reaming to permit removal of a broken solid fragment through a nonunion site and with minimal additional destruction of bone. Although an existing cortical window was used, the newly created cortical window was significantly smaller than windows used in other techniques, and it avoids the articular surface. This technique can be performed with common, readily accessible equipment, which may be helpful in situations in which broken nails are encountered unexpectedly. In summary, this simple, safe, and effective technique uses standard equipment to preserve bone, decrease operative time, and alleviate surgeon frustration in complicated hardware removal surgeries.

LT Pullen, MC, USN, is an Orthopaedic Surgeon, United States Naval Hospital, Yokosuka, Japan. Dr. Pullen was an Orthopaedic Surgery resident at the time the article was written. LT Erdle, MC, USN, is an Orthopaedic Surgery Resident, Department of Orthopaedic Surgery; CDR Crickard, MC, USN, is Division of Trauma Surgery,

Division of Orthopaedic Surgery, and LCDR Smith, MC, USN, is Chief, Division of Trauma Surgery, Department of Orthopaedic Surgery, Naval Medical Center Portsmouth, Portsmouth, Virginia.

Address correspondence to: Christopher S. Smith, MD, Department of Orthopaedic Surgery, Naval Medical Center Portsmouth, 620 John Paul Jones Cir, Portsmouth, VA 23708 (tel, 757-953-1814; fax, 757-953-1908; email, chriss199@yahoo.com).

Am J Orthop. 2016;45(6):E352-E354. Copyright Frontline Medical Communications Inc. 2016. All rights reserved.

References

1. Giannoudis PV, Matthews SJ, Smith RM. Removal of the retained fragment of broken solid nails by the intra-medullary route. *Injury.* 2001;32(5):407-410.
2. Hak DJ, McElvany M. Removal of broken hardware. *J Am Acad Orthop Surg.* 2008;16(2):113-120.
3. Abdelgawad AA, Kanlic E. Removal of a broken cannulated intramedullary nail: review of the literature and a case report of a new technique. *Case Rep Orthop.* 2013;2013:461703.
4. Dawson GR Jr, Stader RO. Extractor for removing broken stuck intramedullary nail. *Am J Orthop Surg.* 1968;10(6):150-151.
5. Gosling T, Allami M, Koenemann B, Hankemeier S, Krettek C. Minimally invasive exchange tibial nailing for a broken solid nail: case report and description of a new technique. *J Orthop Trauma.* 2005;19(10):744-747.
6. Hellemond FJ, Haeff MJ. Removal of a broken solid intramedullary interlocking nail. A technical note. *Acta Orthop Scand.* 1996;67(5):512.
7. Krettek C, Schandelmaier P, Tscherne H. Removal of a broken solid femoral nail: a simple push-out technique. A case report. *J Bone Joint Surg Am.* 1997;79(2):247-251.
8. Milia MJ, Vincent AB, Bosse MJ. Retrograde removal of an incarcerated solid titanium femoral nail after subtrochanteric fracture. *J Orthop Trauma.* 2003;17(7):521-524.
9. Whalley H, Thomas G, Hull P, Porter K. Surgeon versus metalwork—tips to remove a retained intramedullary nail fragment. *Injury.* 2009;40(7):783-789.
10. Smith G, Khan A, Marsh A. A novel way to remove a broken intramedullary nail. *Ann R Coll Surg Engl.* 2012;94(8):605.

This paper will be judged for the Resident Writer's Award.