

# Malignant Transformation of an Aneurysmal Bone Cyst to Fibroblastic Osteosarcoma

Akash P. Kansagra, MD, MS, Jennifer J. Wan, MD, Kavi K. Devulapalli, MD, Andrew E. Horvai, MD, PhD, Richard J. O'Donnell, MD, and Thomas M. Link, MD, PhD

## Abstract

Aneurysmal bone cysts are uncommon primary bone tumors typically regarded as histologically and clinically benign. Malignant transformation of these lesions occurs almost exclusively in the context of prior radiation exposure. However, 4 cases of an osteosarcoma developing without prior radiation exposure have been reported.

In this article, we report a fifth case of degeneration of an aneurysmal bone cyst to a fibroblastic osteosarcoma. In addition to reviewing the earlier cases, we describe the radiologic, pathologic, and immunohistochemical basis of this diagnosis.

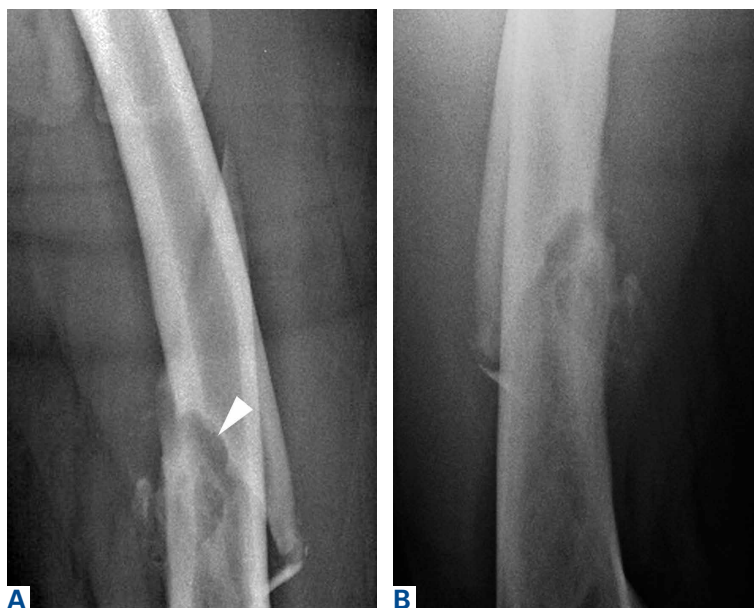**A**neurysmal bone cysts (ABC) are expansile, hemorrhagic, non-neoplastic lesions that can be locally destructive<sup>1</sup> and that can arise either de novo or secondary to another benign or malignant lesion.<sup>2</sup> Although primary and secondary ABCs typically are benign, there are cases of malignant degeneration of primary ABCs, though the transformation arises almost exclusively in the context of prior radiation exposure.<sup>3-5</sup> Malignant change without history of irradiation is rare; only 6 such cases have been reported.<sup>5-10</sup> In 4 of these cases, the transformation was to osteosarcoma.<sup>5,8-10</sup>

Here we report on an ABC that degenerated into a fibroblastic osteosarcoma—the fifth such case in the medical literature. In addition to reviewing the earlier cases, we describe the radiologic and histologic underpinnings of this diagnosis and the insight that they provide into the pathogenesis

of this rare process. Although the prevailing view is that ABCs are benign, it is important to know these lesions have the potential to undergo malignant transformation, even in the absence of prior radiation exposure. The patient provided written informed consent for print and electronic publication of this case report.

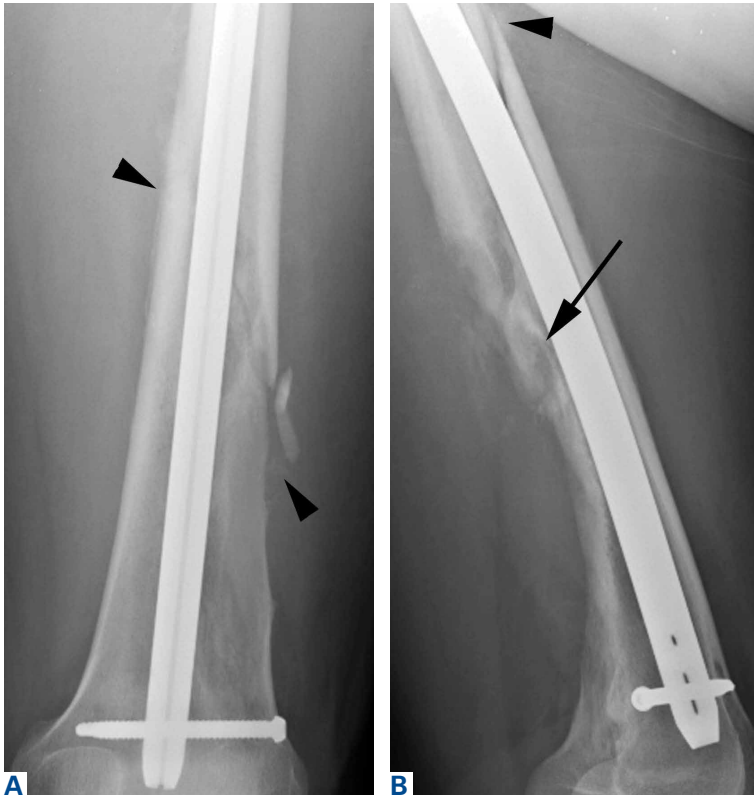
## Case Report

A healthy and previously asymptomatic 37-year-old man presented with thigh pain after a minor fall onto a couch. Radiographs showed a diaphyseal femoral pathologic fracture adjacent to a small but benign-appearing cystic lesion (**Figures 1A, 1B**). At another institution, the patient underwent incisional biopsy through a lateral transvastus approach

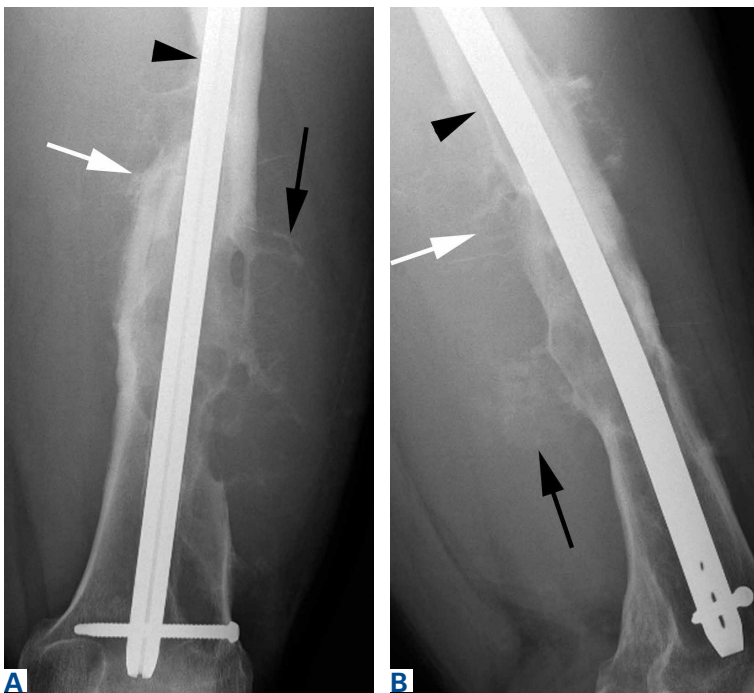

**Figure 1.** (A) Anteroposterior and (B) lateral radiographs at initial presentation show fracture through femoral diaphysis. Fracture is adjacent to well-margined 2 × 4-cm ovoid lesion with cortical scalloping and thin rim of sclerosis (arrowhead).

**Authors' Disclosure Statement:** Dr. Kansagra was supported by National Institutes of Health grant T32 EB001631. The authors report no actual or potential conflict of interest in relation to this article.



**Figure 2.** (A) Anteroposterior and (B) lateral radiographs 1 month after presentation. Scalloped appearance of posterior cortex persists (arrow). Periosteal new bone formation (arrowheads) occurs with fracture healing.



**Figure 3.** (A) Anteroposterior and (B) lateral radiographs 2 years after presentation show complex bony destructive changes (black arrowheads) with irregular sunburst pattern of periosteal reaction (white arrows) and faintly mineralized soft-tissue mass (black arrows). These findings are consistent with an aggressive lesion, particularly an osteosarcoma.

before antegrade intramedullary interlocked rod fixation. The histologic specimen was reported by the referring pathologist as being consistent with a unicameral bone cyst with hemorrhage. The patient returned for only 1 follow-up visit, 1 month after fracture fixation, and radiographic findings were similar—a benign-appearing cystic bone lesion adjacent to a healing fracture (**Figures 2A, 2B**). He had mild persistent thigh swelling, which did not interfere with daily activities, and he did not seek further medical attention.

Two years later, the patient had a bicycle accident and, after 2 weeks of significantly increased thigh swelling, presented to the emergency department at the referring institution. Radiographs showed a lytic lesion in the femoral diaphysis that was highly suspicious for malignancy (**Figures 3A, 3B**). The patient was transferred to our institution. Clinical examination revealed an extensive firm mass in the mid to distal thigh. Magnetic resonance imaging (MRI) showed an aggressive, multilobulated mass surrounding the mid to distal femoral diaphysis (**Figures 4A-4C**).

The initial biopsy specimens were evaluated at our institution and interpreted as being consistent with an ABC, with negative immunohistochemical staining for MDM2 (**Figures 5A, 5B**). A repeat incisional biopsy of the thigh soft-tissue mass was performed, and its results showed a high-grade osteosarcoma that was markedly positive for MDM2 (**Figures 6A, 6B**). The constellation of initial imaging findings (benign-appearing cystic lesion) and histologic appearance without MDM2 staining plus subsequent imaging findings (aggressive, multilobulated mass) with histology positive for MDM2 was considered evidence of sarcomatous degeneration of a primary ABC. Radiographs obtained 2 weeks after the osteosarcoma diagnosis showed worsening bone erosion (**Figures 7A, 7B**).

The patient underwent a 3-month course of neoadjuvant chemotherapy with cisplatin and doxorubicin. Interval-staging contrast-enhanced chest, abdomen, and pelvis computed tomography (CT) showed no evidence of metastatic disease. Preoperative MRI showed a significantly larger heterogeneous mass, now with neurovascular involvement, which precluded limb salvage. The massive size and proximal extent of the tumor required hip disarticulation for local control. Areas contaminated by the prior surgery, including the entry site of the antegrade rod and surrounding gluteal musculature, were resected widely, en bloc, with the amputation specimen. The surgical

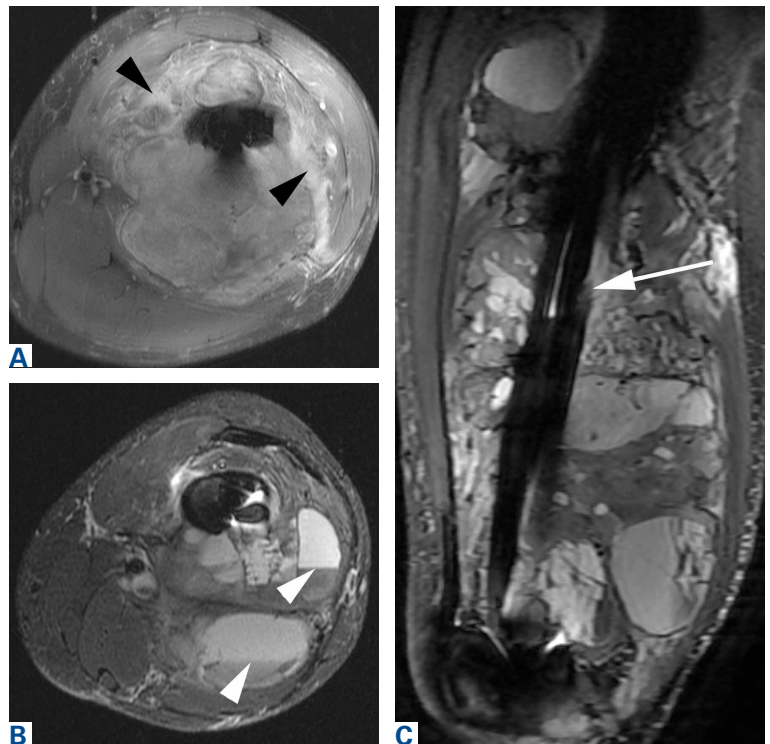
margins were widely free of tumor. Necrosis in response to chemotherapy was <1%. Histologic analysis revealed a heterogeneous 35-cm tumor with areas similar to those on the initial biopsy specimen (2 years earlier) intermixed with areas consistent with high-grade osteosarcoma (Figures 8A–8D). Adjuvant salvage chemotherapy was continued, and the patient had no evidence of tumor recurrence or metastatic disease more than 2 years after surgery.

### Discussion

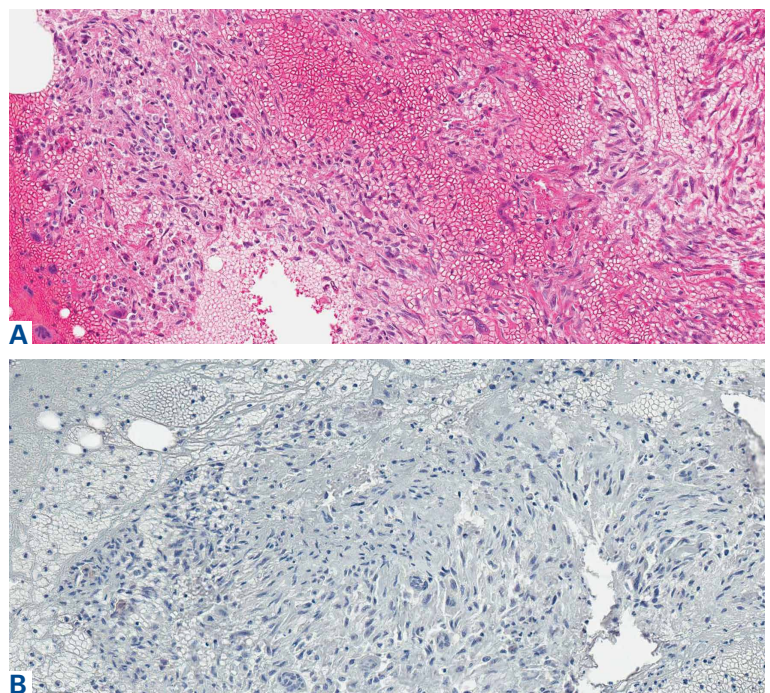
Aneurysmal bone cysts are expansile, hemorrhagic, locally destructive lesions that generally develop within the first 3 decades of life. Ever since they were first described by Jaffe and Lichtenstein<sup>11</sup> in 1942, the most widely accepted theory of their pathogenesis has been that they begin as a benign reactive vascular process.<sup>12</sup> However, more recent molecular studies by Oliveira and colleagues<sup>13</sup> and Panoutsakopoulos and colleagues<sup>14</sup> have demonstrated a clonal neoplastic basis for primary ABCs related to cytogenetic upregulation of oncogenes USP6 and CDH11 after translocation of 17p13 and 16q22.

Given the clonal nature of these lesions, it is surprising that malignant transformation is so rare. Until now, there have been only 4 reports of an ABC undergoing malignant degeneration to osteosarcoma without prior radiation exposure. Kyriakos and Hardy<sup>5</sup> described a patient with a distal tibial ABC that recurred as an ABC several times after curettage before finally changing 3 years later into a pleomorphic osteosarcoma. Hsu and colleagues<sup>9</sup> reported a proximal tibial ABC, treated with complete excision and phenol therapy, that transformed into an osteosarcoma after 6 years. Brindley and colleagues<sup>10</sup> described 2 cases of ABC (1 in the proximal humerus, 1 in the proximal tibia) that were treated with careful curettage but subsequently became telangiectatic and fibroblastic osteosarcomas after 5 years and 12 years, respectively.

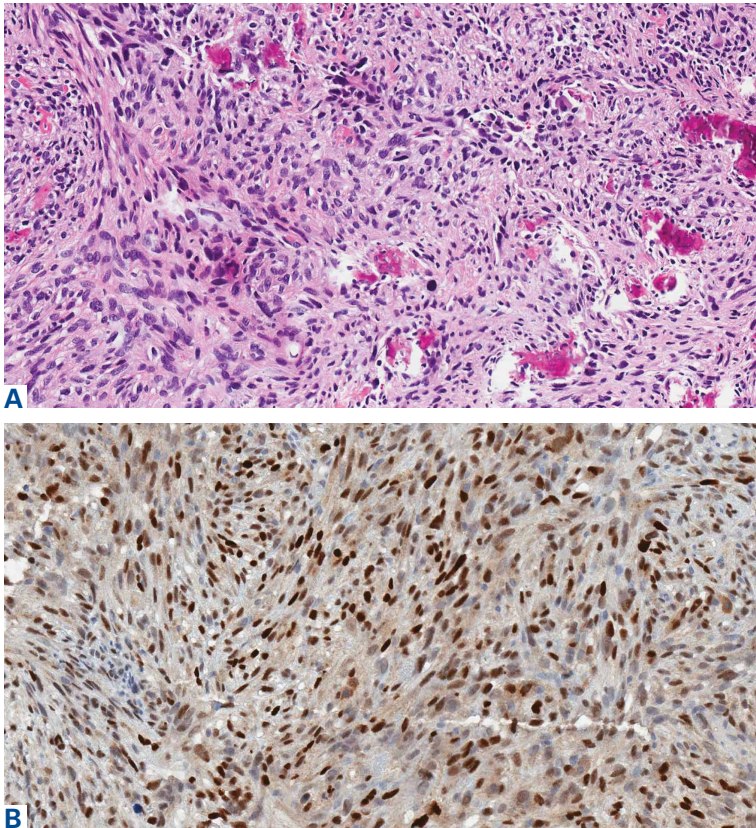
In this article, we have presented a fifth case of a primary ABC degenerating into an osteosarcoma, which in this instance was the fibroblastic subtype. This diagnosis was strongly supported by radiologic and pathologic evidence. From a radiologic perspective, imaging at initial presentation showed absolutely no suspicious features, and the same was true when follow-up radiographs were obtained, 1 month later. Although 1 month is short for a follow-up, the complete lack of radiographic changes



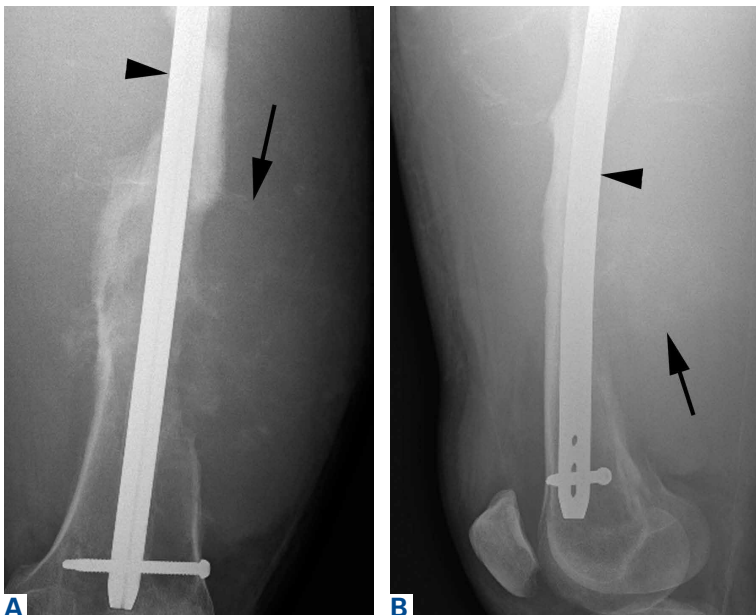**Figure 4.** (A) Axial T1-weighted postcontrast, (B) axial short-TI inversion recovery (STIR), and (C) sagittal STIR magnetic resonance imaging of thigh 2 years after presentation. A 32 × 13 × 14-cm heterogeneous soft-tissue lesion surrounds entire femoral diaphysis with interspersed enhancing soft tissue (black arrowheads) and innumerable cystic cavities containing fluid-fluid levels (white arrowheads). Also evident are extensive bone erosion and aggressive periostitis of femoral diaphysis (white arrow). Overall, imaging features are consistent with a highly aggressive sarcoma.



**Figure 5.** Histologic specimens at initial presentation. (A) Minimal nuclear atypia but extensive hemorrhage and scant fragments of narrow spindle cells mixed with osteoclast-type giant cells and small seams of osteoid (hematoxylin-eosin, original magnification ×200). (B) No appreciable expression of MDM2 (immunohistochemical staining, original magnification ×400).



**Figure 6.** Histologic specimens from biopsy 2 years after initial presentation. (A) Fragments of spindle cell tumor with pleomorphic nuclei in sheets and streaming fascicles; multinucleated giant cells and areas of necrosis are scattered throughout, with scant areas of osteoid formation by malignant cells (hematoxylin-eosin, original magnification  $\times 200$ ). (B) Strongly positive expression of MDM2 (immunohistochemical staining, original magnification  $\times 400$ ).



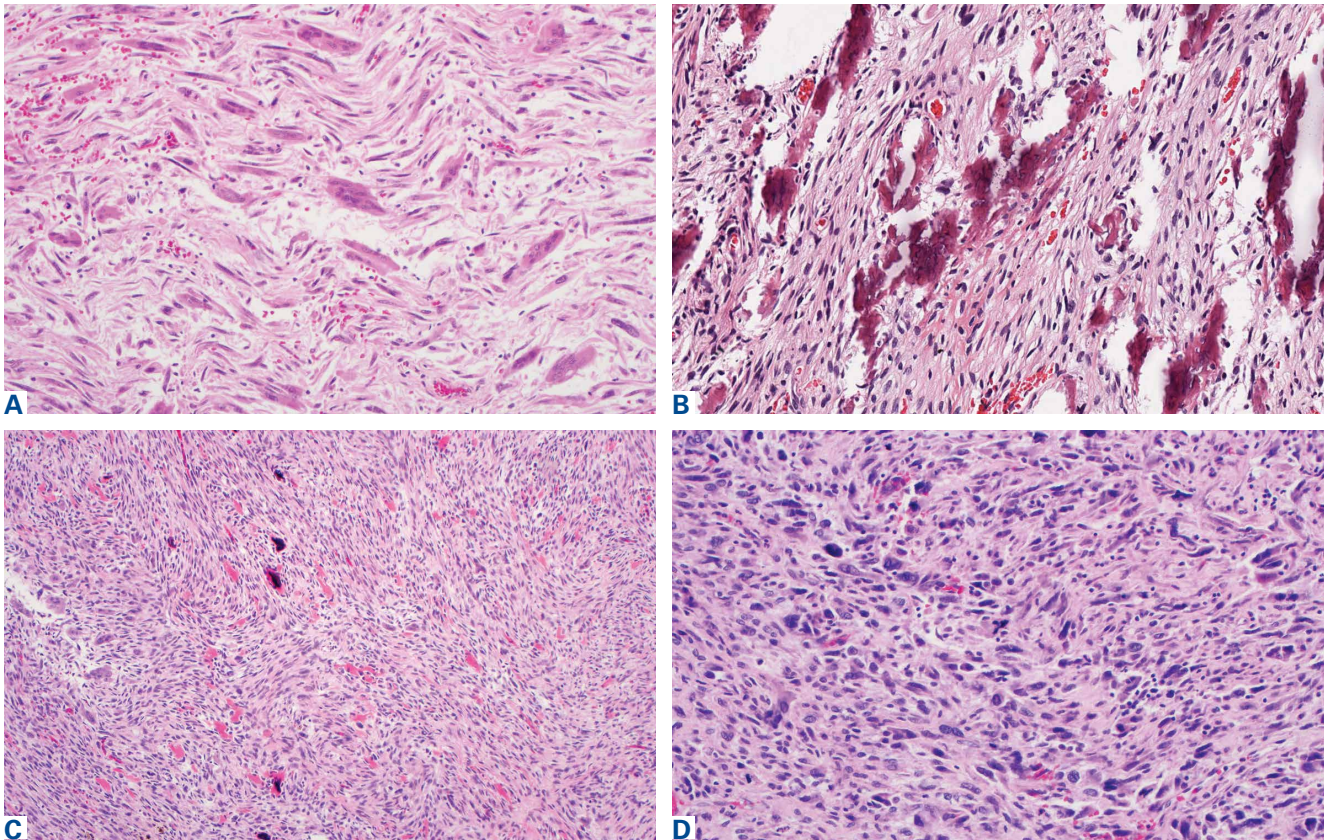
**Figure 7.** (A) Frontal and (B) lateral radiographs 1 month after osteosarcoma diagnosis show interval progression of bony destructive change with loss of about 12 cm of bony cortex (arrowheads) and interval enlargement of soft-tissue mass (arrows), again concerning for a highly aggressive, rapidly progressive osteosarcoma.

would be highly unusual if in fact there had been a coexisting, undetected lesion as aggressive as the one that ultimately developed. Furthermore, imaging at second presentation, almost 2 years later, showed an extremely rapid evolution of findings over 1 month. Extrapolating back in time, we think this time course indicates the malignancy developed not long before its aggressive features were detected.

Genetic evidence suggests that most conventional high-grade osteosarcomas arise de novo from a mesenchymal precursor driven by multiple genetic aberrations. Less often, low-grade osteosarcomas progress to high-grade osteosarcomas. Amplification of 12q13-15 with resulting overexpression of MDM2 and CDK4 proteins is found in low-grade osteosarcomas and persists in examples that progress to higher-grade forms.<sup>15</sup> Not only did review of our patient's initial biopsy sample reveal no evidence of malignant features or abnormal mitotic activity, but the complete absence of MDM2 suggests not even a low-grade osteosarcoma was present at the time. By contrast, the second incisional biopsy specimen, 2 years later, showed markedly different histology and pronounced expression of MDM2 throughout the specimen. This finding suggests the histologically high-grade osteosarcoma did not arise de novo but rather secondarily from a low-grade osteosarcoma that had arisen from an ABC. Results of the final heterogeneous histology of the very large mass, which contained benign ABC areas indistinguishable from the initial biopsy sample, as well as areas of high-grade osteosarcoma, further support a multistep process of de-differentiation. Together, these findings are compelling evidence of malignant transformation of a primary ABC.

We acknowledge that the initial surgery performed at the outside hospital might have properly included frozen-section analysis of the biopsy material and that sampling error may have occurred during the index procedure—possibilities in the absence of complete lesional resection. In this case, however, the radiographic findings and the dominant histologic immunophenotype from medullary canal bone were both consistent with ABC and not osteosarcoma, lending support to malignant degeneration.

We have presented a fifth case of primary ABC degenerating into an osteosarcoma, now with immunohistochemical evidence supporting traditional radiologic and histologic evidence. Despite the rarity of the diagnosis, this case yields consider-



**Figure 8.** Histologic specimens from hip disarticulation specimen. (A) Areas of low-grade atypia and cellularity similar to initial biopsy findings of aneurysmal bone cyst (hematoxylin-eosin, original magnification,  $\times 200$ ). (B) Areas of low-grade bone production (hematoxylin-eosin, original magnification,  $\times 200$ ). (C) Low-grade areas adjacent to high-grade areas with bone and osteoid production (hematoxylin-eosin, original magnification,  $\times 100$ ). (D) Areas of high-grade nuclear pleomorphism and prominent mitotic activity (hematoxylin-eosin, original magnification,  $\times 200$ ).

able insight into the pathogenetic mechanisms underlying malignant degeneration. Despite the widely held view that ABCs are benign, physicians caring for these patients must be aware that malignant transformation can occur.

Dr. Kansagra is Associate Professor of Radiology and Neurological Surgery, Washington University School of Medicine, St. Louis, Missouri. Dr. Kansagra was Chief Resident at the time the article was written. Dr. Wan and Dr. Devulapalli are Resident Physicians, Department of Radiology and Biomedical Imaging, Dr. Horvai is Clinical Professor and Associate Director of Surgical Pathology, Department of Pathology, Dr. O'Donnell is Chief of Orthopaedic Oncology Service, Department of Orthopaedic Surgery, and Dr. Link is Chief of Musculoskeletal Imaging and Clinical Director, Department of Radiology and Biomedical Imaging, University of California, San Francisco, California.

Address correspondence to: Jennifer J. Wan, MD, Department of Radiology and Biomedical Imaging, University of California, 505 Parnassus Avenue, M-361, San Francisco, CA 94143 (tel, 415-443-6870; email, jennifer.wan@ucsf.edu).

*Am J Orthop.* 2016;45(6):E367-E372. Copyright Frontline Medical Communications Inc. 2016. All rights reserved.

## References

1. Donaldson WF. Aneurysmal bone cyst. *J Bone Joint Surg Am.* 1962;44:25-40.
2. Biesecker JL, Marcove RC, Huvos AG, Miké V. Aneurysmal bone cysts. A clinicopathologic study of 66 cases. *Cancer.* 1970;26(3):615-625.
3. Aho HJ, Aho AJ, Einola S. Aneurysmal bone cyst, a study of ultrastructure and malignant transformation. *Virchows Arch A Pathol Anat Histol.* 1982;395(2):169-179.
4. Tillman BP, Dahlin DC, Lipscomb PR, Stewart JR. Aneurysmal bone cyst: an analysis of ninety-five cases. *Mayo Clin Proc.* 1968;43(7):478-495.
5. Kyriakos M, Hardy D. Malignant transformation of aneurysmal bone cyst, with an analysis of the literature. *Cancer.* 1991;68(8):1770-1780.
6. Mei J, Gao YS, Wang SQ, Cai XS. Malignant transformation of aneurysmal bone cysts: a case report. *Chin Med J (Engl).* 2009;122(1):110-112.
7. Anract P, de Pinieux G, Jeanrot C, Babinet A, Forest M, Tomeno B. Malignant fibrous histiocytoma at the site of a previously treated aneurysmal bone cyst: a case report. *J Bone Joint Surg Am.* 2002;84(1):106-111.
8. Hsu CC, Wang JW, Huang CH, Chen WJ. Osteosarcoma at the site of a previously treated aneurysmal bone cyst. A case report. *J Bone Joint Surg Am.* 2005;87(2):395-398.
9. Wuisman P, Roessner A, Blasius S, Grünert J, Vestering T, Winkelmann W. High malignant surface osteosarcoma arising at the site of a previously treated aneurysmal bone cyst. *J Cancer Res Clin Oncol.* 1993;119(7):375-378.
10. Brindley GW, Greene JF Jr, Frankel LS. Case reports: malignant transformation of aneurysmal bone cysts. *Clin Orthop.*

- Relat Res.* 2005;(438):282-287.
11. Jaffe HL, Lichtenstein L. Solitary unicameral bone cyst: with emphasis on the roentgen picture, the pathologic appearance and the pathogenesis. *Arch Surg.* 1942;44:1004-1025.
  12. Mirra JM. *Bone Tumors: Clinical, Radiologic, and Pathologic Correlations.* Philadelphia, PA: Lea & Febiger; 1989.
  13. Oliveira AM, Chou MM, Perez-Atayde AR, Rosenberg AE. Aneurysmal bone cyst: a neoplasm driven by upregulation of the USP6 oncogene. *J Clin Oncol.* 2006;24(1):e1.
  14. Panoutsakopoulos G, Pandis N, Kyriazoglou I, Gustafson P, Mertens F, Mandahl N. Recurrent t(16;17)(q22;p13) in aneurysmal bone cysts. *Genes Chromosomes Cancer.* 1999;26(3):265-266.
  15. Dujardin F, Binh MB, Bouvier C, et al. MDM2 and CDK4 immunohistochemistry is a valuable tool in the differential diagnosis of low-grade osteosarcomas and other primary fibro-osseous lesions of the bone. *Mod Pathol.* 2001;24(5):624-637.

*This paper will be judged for the Resident Writer's Award.*