

# Robotic Technology Produces More Conservative Tibial Resection Than Conventional Techniques in UKA

Danielle Y. Ponzio, MD, and Jess H. Lonner, MD

## Abstract

Conversion of unicompartmental knee arthroplasty (UKA) to total knee arthroplasty (TKA) may be relatively simple when tibial resection is conservative during the index UKA. However, with greater tibial resection, conversion to TKA may be complicated by osseous insufficiency, requiring stems and augments, and potentially compromising patient outcomes and TKA durability. Robotic assistance in UKA is shown to enhance the bone preparation accuracy. In our retrospective comparison of polyethylene insert sizes, 8-mm or 9-mm polyethylene inserts were used in 93.6% and 84.5% of robotic (N = 8421) and conventional (N = 27,989) UKAs, respectively. Aggressive tibial resection, requiring tibial inserts  $\geq 10$  mm, was performed in 6.4% of robotic-assisted cases and 15.5% of conventional cases. Robotic-assisted UKA more reproducibly achieved accurate and precise conservative resection.

Unicompartmental knee arthroplasty (UKA) is considered a less invasive approach for the treatment of unicompartmental knee arthritis when compared with total knee arthroplasty (TKA), with optimal preservation of kinematics.<sup>1</sup> Despite excellent functional outcomes, conversion to TKA may be necessary if the UKA fails, or in patients with progressive knee arthritis. Some studies have found UKA conversion to TKA to be comparable with primary TKA,<sup>2,3</sup> whereas others have found that conversion often requires bone graft, augments, and stemmed components and

has increased complications and inferior results compared to primary TKA.<sup>4-7</sup> While some studies report that <10% of UKA conversions to TKA require augments,<sup>2</sup> others have found that as many as 76% require augments.<sup>4-8</sup>

Schwarzkopf and colleagues<sup>9</sup> recently demonstrated that UKA conversion to TKA is comparable with primary TKA when a conservative tibial resection is performed during the index procedure. However, they reported increased complexity when greater tibial resection was performed and thicker polyethylene inserts were used at the time of the index UKA. The odds ratio of needing an augment or stem during the conversion to TKA was 26.8 (95% confidence interval, 3.71-194) when an aggressive tibial resection was performed during the UKA.<sup>9</sup> Tibial resection thickness may thus be predictive of anticipated complexity of UKA revision to TKA and may aid in preoperative planning.

Robotic assistance has been shown to enhance the accuracy of bone preparation, implant component alignment, and soft tissue balance in UKA.<sup>10-15</sup> It has yet to be determined whether this improved accuracy translates to improved clinical performance or longevity of the UKA implant. However, the enhanced accuracy of robotic technology may result in more conservative tibial resection when compared to conventional UKA and may be advantageous if conversion to TKA becomes necessary.

The purpose of this study was to compare the distribution of polyethylene insert sizes implanted during conventional and robotic-assisted UKA. We hypothesized that robotic assistance would demonstrate more conservative tibial resection compared to conventional methods of bone preparation.

## Methods

We retrospectively compared the distribution of polyethylene insert sizes implanted during con-

**Authors' Disclosure Statement:** Dr. Lonner reports that he is a consultant to, and receives royalties from, Zimmer Biomet and Smith & Nephew. Dr. Ponzio reports no actual or potential conflict of interest in relation to this article.

secutive conventional and robotic-assisted UKA procedures. Several manufacturers were queried to provide a listing of the polyethylene insert sizes utilized, ranging from 8 mm to 14 mm. The analysis included 8421 robotic-assisted UKA cases and 27,989 conventional UKA cases. Data were provided by Zimmer Biomet and Smith & Nephew regarding conventional cases, as well as Blue Belt Technologies (now part of Smith & Nephew) and MAKO Surgical (now part of Stryker) regarding robotic-assisted cases. (Dr. Lonner has an ongoing relationship as a consultant with Blue Belt Technologies, whose data was utilized in this study.) Using tibial insert thickness as a surrogate measure of the extent of tibial resection, an insert size of  $\geq 10$  mm was defined as aggressive while  $< 10$  mm was considered conservative. This cutoff was established based on its corresponding resection level with primary TKA and the anticipated need for augments. Statistical analysis was performed using a Mann-Whitney-Wilcoxon test. Significance was set at  $P < .05$ .

## Results

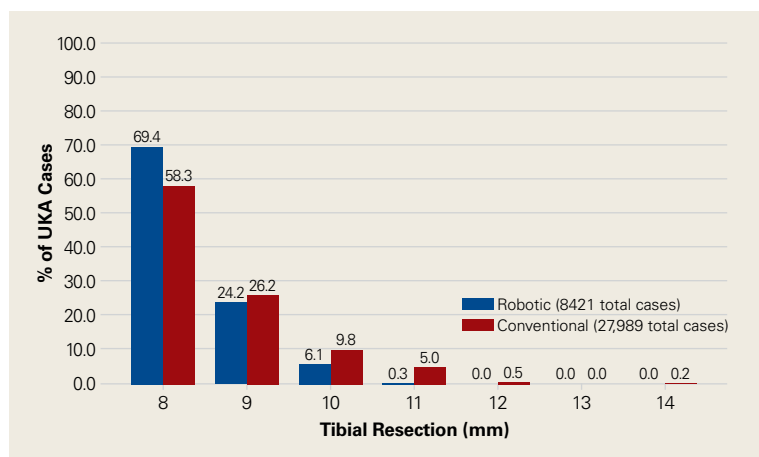
Tibial resection thickness was found to be most commonly conservative in nature, with sizes 8-mm and 9-mm polyethylene inserts utilized in the majority of both robotic-assisted and conventional UKA cases. However, statistically more 8-mm and 9-mm polyethylene inserts were used in the robotic group (93.6%) than in the conventional group (84.5%) ( $P < .0001$ ; **Figure**). Aggressive tibial resection, requiring tibial inserts  $\geq 10$  mm, was performed in 6.4% of robotic-assisted cases and

15.5% of conventional cases. Only .29% of robotic-assisted cases required tibial inserts  $\geq 10$  mm, whereas 5.7% of patients undergoing conventional UKA had tibial inserts  $\geq 10$  mm. In this analysis, the maximum tibial component thickness was 11 mm in robotic-assisted UKA and 14 mm in conventional UKA. The distribution of conventional UKA tibial resection thicknesses is significantly greater in comparison to robotic-assisted UKA, which more reproducibly achieved accurate and precise conservative resection. No significant differences were noted in the percentages of polyethylene sizes between Blue Belt Technologies or MAKO cases.

## Discussion

Robotic assistance enhances the accuracy of bone preparation, implant component alignment, and soft tissue balance in UKA.<sup>10-15</sup> It has yet to be determined whether this improved accuracy translates to improved clinical performance or longevity of the UKA implant. However, we demonstrate that the enhanced accuracy of robotic technology results in more conservative tibial resection when compared to conventional techniques with a potential benefit suggested in the literature upon conversion to TKA.

The findings of this study have important implications for patients undergoing conversion of UKA to TKA, potentially optimizing the ease of revision and clinical outcomes. The outcomes of UKA conversion to TKA are often considered inferior to those of primary TKA, compromised by bone loss, need for augmentation, and challenges of restoring the joint line and rotation.<sup>9,16-22</sup> Barrett and Scott<sup>18</sup> reported only 66% of patients had good or excellent results at an average of 4.6 years of follow-up after UKA conversion to TKA. Over 50% required stemmed implants and bone graft or bone cement augmentation to address osseous insufficiency. The authors suggested that the primary determinant of the complexity of the conversion to TKA was the surgical technique used in the index procedure. They concluded that UKA conversion to TKA can be as successful as a primary TKA and primary TKA implants can be used without bone augmentation or stems during the revision procedure if minimal tibial bone is resected at the time of the index UKA.<sup>18</sup> Schwarzkopf and colleagues<sup>9</sup> supported this conclusion when they found that aggressive tibial resection during UKA resulted in the need for bone graft, stem, wedge, or augment in 70% of cases when converted to TKA. Similarly, Khan and colleagues<sup>23</sup>



**Figure.** Range of implanted tibial component sizes using robotic and conventional unicompartmental knee arthroplasty (UKA) techniques. The distribution of conventional UKA tibial resection thicknesses is significantly greater in comparison to robotic-assisted UKA ( $P < .0001$ ).

found that 26% of patients required bone grafting and 26% required some form of augmentation, and Springer and colleagues<sup>3</sup> reported that 68% required a graft, augment, or stem.<sup>3,22</sup> Using data from the New Zealand Joint Registry, Pearse and colleagues<sup>5</sup> reported that revision TKA components were necessary in 28% of patients and concluded that converting a UKA to TKA gives a less reliable result than primary TKA, and with functional results that are not significantly better than a revision from a TKA.

Conservative tibial resection during UKA minimizes the complexity and concerns of bone loss upon conversion to TKA. Schwarzkopf and colleagues<sup>9</sup> found 96.6% of patients with conservative tibial resection received a primary TKA implant, without augments or stems. Furthermore, patients with a primary TKA implant showed improved tibial survivorship, with revision as an end point, compared with patients who received a TKA implant that required stems and augments or bone graft for support.<sup>9</sup> Also emphasizing the importance of minimal tibial resection, O'Donnell and colleagues<sup>8</sup> compared a cohort of patients undergoing conversion of a minimal resection resurfacing onlay-type UKA to TKA with a cohort of patients undergoing primary TKA. They found that 40% of patients required bone grafting for contained defects, 3.6% required metal augments, and 1.8% required stems.<sup>8</sup> There was no significant difference between the groups in terms of range of motion, functional outcome, or radiologic outcomes. The authors concluded that revision of minimal resection resurfacing implants to TKA is associated with similar results to primary TKA and is superior to revision of UKA with greater bone loss. Prior studies have shown that one of the advantages of robotic-assisted UKA is the accuracy and precision of bone resection. The present study supports this premise by showing that tibial resection is significantly more conservative using robotic-assisted techniques when using tibial component thickness as a surrogate for extent of bone resection. While our study did not address implant durability or the impact of conservative resection on conversion to TKA, studies referenced above suggest that the conservative nature of bone preparation would have a relevant impact on the revision of the implant to TKA.

Our study is a retrospective case series that reports tibial component thickness as a surrogate for volume of tibial resection during UKA. While the implication is that more conservative tibial resec-

tion may optimize durability and ease of conversion to TKA, future study will be needed to compare robotic-assisted and conventional cases of UKA upon conversion to TKA in order to ascertain whether the more conventional resections of robotic-assisted UKA in fact lead to revision that is comparable with primary TKA in terms of bone loss at the time of revision, components utilized, the need for bone graft, augments, or stems, and clinical outcomes. Given the method of data collection in this study, we could not control for clinical deformity, selection bias, surgeon experience, or medial vs lateral knee compartments. These potential confounders represent weaknesses of this study.

In conclusion, conversion of UKA to TKA may be associated with significant osseous insufficiency, which may compromise patient outcomes in comparison to primary TKA. Studies have shown that UKA conversion to TKA is comparable to primary TKA when minimal tibial resection is performed during the UKA, and the need for augmentation, grafting or stems is increased with more aggressive tibial resection. This study has shown that when robotic assistance is utilized, tibial resection is more precise, less variable, and more conservative compared to conventional techniques.

---

Dr. Ponzio is an Orthopedic Surgery Resident, and Dr. Lonner is an Orthopedic Surgeon, Adult Reconstruction, Rothman Institute at Thomas Jefferson University, Philadelphia, Pennsylvania.

Address correspondence to: Jess H. Lonner, MD, Rothman Institute at Thomas Jefferson University, 1025 Walnut Street, Suite 516, College Building, Philadelphia, PA 19107 (tel, 215-955-1500; email, jesslonner@comcast.net).

*Am J Orthop.* 2016;45(7):E465-E468. Copyright Frontline Medical Communications Inc. 2016. All rights reserved.

## References

1. Patil S, Colwell CW Jr, Ezzet KA, D'Lima DD. Can normal knee kinematics be restored with unicompartmental knee replacement? *J Bone Joint Surg Am.* 2005;87(2):332-338.
2. Johnson S, Jones P, Newman JH. The survivorship and results of total knee replacements converted from unicompartmental knee replacements. *Knee.* 2007;14(2):154-157.
3. Springer BD, Scott RD, Thornhill TS. Conversion of failed unicompartmental knee arthroplasty to TKA. *Clin Orthop Relat Res.* 2006;446:214-220.
4. Järvenpää J, Kettunen J, Miettinen H, Kröger H. The clinical outcome of revision knee replacement after unicompartmental knee arthroplasty versus primary total knee arthroplasty: 8-17 years follow-up study of 49 patients. *Int Orthop.* 2010;34(5):649-653.
5. Pearse AJ, Hooper GJ, Rothwell AG, Frampton C. Osteotomy and unicompartmental knee arthroplasty converted to total knee arthroplasty: data from the New Zealand Joint Registry. *J Arthroplasty.* 2012;27(10):1827-1831.
6. Rancourt MF, Kemp KA, Plamondon SM, Kim PR, Dervin GF.

- Unicompartmental knee arthroplasties revised to total knee arthroplasties compared with primary total knee arthroplasties. *J Arthroplasty*. 2012;27(8 Suppl):106-110.
7. Sierra RJ, Kassel CA, Wetters NG, Berend KR, Della Valle CJ, Lombardi AV. Revision of unicompartmental arthroplasty to total knee arthroplasty: not always a slam dunk! *J Arthroplasty*. 2013;28(8 Suppl):128-132.
  8. O'Donnell TM, Abouazza O, Neil MJ. Revision of minimal resection resurfacing unicondylar knee arthroplasty to total knee arthroplasty: results compared with primary total knee arthroplasty. *J Arthroplasty*. 2013;28(1):33-39.
  9. Schwarzkopf R, Mikhael B, Li L, Josephs L, Scott RD. Effect of initial tibial resection thickness on outcomes of revision UKA. *Orthopedics*. 2013;36(4):e409-e414.
  10. Conditt MA, Roche MW. Minimally invasive robotic-arm-guided unicompartmental knee arthroplasty. *J Bone Joint Surg Am*. 2009;91 Suppl 1:63-68.
  11. Dunbar NJ, Roche MW, Park BH, Branch SH, Conditt MA, Banks SA. Accuracy of dynamic tactile-guided unicompartmental knee arthroplasty. *J Arthroplasty*. 2012;27(5):803-808.e1.
  12. Karia M, Masjedi M, Andrews B, Jaffry Z, Cobb J. Robotic assistance enables inexperienced surgeons to perform unicompartmental knee arthroplasties on dry bone models with accuracy superior to conventional methods. *Adv Orthop*. 2013;2013:481039.
  13. Lonner JH, John TK, Conditt MA. Robotic arm-assisted UKA improves tibial component alignment: a pilot study. *Clin Orthop Relat Res*. 2010;468(1):141-146.
  14. Lonner JH, Smith JR, Picard F, Hamlin B, Rowe PJ, Riches PE. High degree of accuracy of a novel image-free handheld robot for unicondylar knee arthroplasty in a cadaveric study. *Clin Orthop Relat Res*. 2015;473(1):206-212.
  15. Smith JR, Picard F, Rowe PJ, Deakin A, Riches PE. The accuracy of a robotically-controlled freehand sculpting tool for unicondylar knee arthroplasty. *Bone Joint J*. 2013;95-B (suppl 28):68.
  16. Chakrabarty G, Newman JH, Ackroyd CE. Revision of unicompartmental arthroplasty of the knee. Clinical and technical considerations. *J Arthroplasty*. 1998;13(2):191-196.
  17. Levine WN, Ozuna RM, Scott RD, Thornhill TS. Conversion of failed modern unicompartmental arthroplasty to total knee arthroplasty. *J Arthroplasty*. 1996;11(7):797-801.
  18. Barrett WP, Scott RD. Revision of failed unicondylar unicompartmental knee arthroplasty. *J Bone Joint Surg Am*. 1987;69(9):1328-1335.
  19. Padgett DE, Stern SH, Insall JN. Revision total knee arthroplasty for failed unicompartmental replacement. *J Bone Joint Surg Am*. 1991;73(2):186-190.
  20. Aleto TJ, Berend ME, Ritter MA, Faris PM, Meneghini RM. Early failure of unicompartmental knee arthroplasty leading to revision. *J Arthroplasty*. 2008;23(2):159-163.
  21. McAuley JP, Engh GA, Ammeen DJ. Revision of failed unicompartmental knee arthroplasty. *Clin Orthop Relat Res*. 2001;(392):279-282.
  22. Böhm I, Landsiedl F. Revision surgery after failed unicompartmental knee arthroplasty: a study of 35 cases. *J Arthroplasty*. 2000;15(8):982-989.
  23. Khan Z, Nawaz SZ, Kahane S, Ester C, Chatterji U. Conversion of unicompartmental knee arthroplasty to total knee arthroplasty: the challenges and need for augments. *Acta Orthop Belg*. 2013;79(6):699-705.

*This paper will be judged for the Resident Writer's Award.*