

Safety of Superior Labrum Anterior and Posterior (SLAP) Repair Posterior to Biceps Tendon Is Improved With a Percutaneous Approach

Patrick J. Denard, MD, and Christopher R. Adams, MD

Abstract

We conducted a study to compare a standard anterosuperolateral (ASL) portal with a percutaneous Port of Wilmington (PW) portal for repair of superior labrum anterior and posterior (SLAP) tears. We hypothesized that anchors placed through the PW portal would be less likely to penetrate the glenoid or injure the suprascapular nerve (SSN).

This study used 6 matched-pair cadaveric shoulders. Two anchors were arthroscopically placed posterior to the biceps, at 11 o'clock and 10 o'clock, to simulate a SLAP repair. One set of anchors was placed through an ASL portal and the other through a PW portal. Glenoid vault penetration and distance to SSN were noted.

In the ASL portal group, 8 (66.7%) of 12 anchors violated the medial cortex of the glenoid; in the penetration cases, mean distance to SSN was 6.8 mm for 11 o'clock anchors and 4.8 mm for 10 o'clock anchors. In the PW portal group, 2 (16.7%) of 12 anchors violated the medial cortex of the glenoid; in the penetration cases, distance to SSN was 20 mm for the 11 o'clock anchor and 8 mm for the 10 o'clock anchor.

The risk of glenoid vault penetration during repair of SLAP tears posterior to the biceps tendon is reduced when a percutaneous posterior approach is used for anchor placement. This approach also directs the anchor away from the SSN.

Since being classified by Snyder and colleagues,¹ various arthroscopic techniques have been used to repair superior labrum anterior and posterior (SLAP) tears, particularly type II tears. Despite being commonly performed, repairs of SLAP lesions remain challenging. There is high variability in the rate of good/excellent functional outcomes and athletes' return to previous level of play after SLAP repairs.^{2,3} Furthermore, the rate of complications after SLAP repair is as high as 5%.⁴

One of the most common complications of repair of a type II SLAP tear is nerve injury.⁴ In particular, suprascapular nerve (SSN) injury has occurred after arthroscopic repair of SLAP tears.^{5,6} Three cadaveric studies have demonstrated that glenoid vault penetration is common during placement of knotted anchors for SLAP repair and that the SSN is at risk during placement of these anchors.⁷⁻⁹ However, 2 of the 3 studies used only an anterior portal in their evaluation of anchor placement. Safety of anchor placement posterior to the biceps tendon may be improved with a percutaneous approach using a Port of Wilmington (PW) portal.^{10,11} No studies have evaluated the risk of glenoid vault penetration and SSN injury with shorter knotless anchors.

We conducted a study to compare a standard anterosuperolateral (ASL) portal with a percutaneous PW portal for knotless anchors placed posterior to the biceps tendon during repair of SLAP tears. We hypothesized that anchors placed through the PW portal would be less likely to penetrate the glenoid vault and would be farther from the SSN in the event of bone penetration.

Materials and Methods

Six matched pairs of fresh human cadaveric shoulders were used in this study. Each specimen

Authors' Disclosure Statement: This study was funded by a research grant from Arthrex. Dr. Adams reports that he is Vice President of Global Medical Education at Arthrex. Dr. Denard reports that he is a consultant for Arthrex.

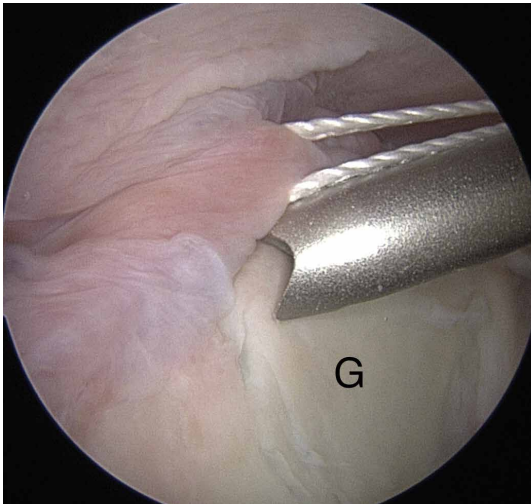


Figure 1. Arthroscopic view of 11 o'clock anchor placed through anterosuperolateral portal in right shoulder.

Abbreviation: G, glenoid.

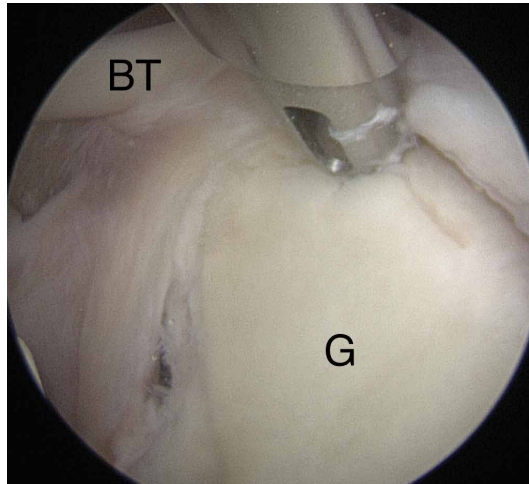


Figure 2. Arthroscopic view of 1 o'clock anchor placed through Port of Wilmington portal in left shoulder (11 o'clock in right shoulder).

Abbreviations: BT, biceps tendon; G, glenoid

included the scapula, the clavicle, and the humerus. All 6 specimens were male, and their mean age was 41.2 years (range, 23-59 years). Shoulder arthroscopy was performed for placement of SLAP anchors, and open dissection followed.

Anchor Placement

The scapula was clamped and the shoulder placed in the lateral decubitus position with 30° of abduction, 20° of forward flexion, and neutral rotation.¹⁰ A standard posterior glenohumeral viewing portal was established and a 30° arthroscope inserted. Both shoulders of each matched pair were randomly assigned to anchor placement through either an ASL portal or a PW portal. Two anchors were placed in the superior glenoid to simulate repair of a posterior SLAP tear.¹¹ Each was a 2.9-mm short (12.5-mm) knotless anchor (BioComposite PushLock; Arthrex) that included a polyetheretherketone (PEEK) eyelet for threading sutures before anchor placement. A drill guide was inserted according to manufacturer guidelines, and a 2.9-mm drill was used to make a bone socket 18 mm deep. The anchor eyelet was loaded with suture tape (Labral Tape; Arthrex), and the anchor and suture were inserted into the socket. The sutures were left uncut to aid in anchor visualization during open dissection. On a right shoulder, the first anchor was placed just posterior to the biceps tendon, at 11 o'clock, and the second anchor about 1 cm posterior to the first, at 10 o'clock. All anchors were placed by an arthroscopy fellowship-trained shoulder surgeon. Before placement, anchor

location was confirmed by another arthroscopy fellowship-trained shoulder surgeon.

The ASL portal was created, with an 18-gauge spinal needle and an outside-in technique, about 1 cm lateral to the anterolateral corner of the acromion. The portal was established through the rotator interval just anterior to the leading edge of the supraspinatus tendon and posterior to the long head of the biceps tendon. In this portal, an 8.25-mm threaded cannula was inserted for anchor placement (**Figure 1**).

In the opposite shoulder, the PW portal was created, with a percutaneous technique, about 1 cm anterior and 1 cm lateral to the posterolateral corner of the acromion. An 18-gauge spinal needle was inserted to allow a 45° angle of approach to the posterosuperior glenoid.¹¹ A guide wire was threaded through the needle, and the needle was removed. Then the portal was dilated, and a 4.5-mm metal cannula was inserted for anchor placement (**Figure 2**).

Cadaveric Dissection

After anchor placement, another shoulder surgeon performed the dissection. Skin, subcutaneous tissue, deltoid, and clavicle were removed. In the percutaneous specimens, PW portal location relative to rotator cuff was recorded

Take-Home Points

- Anchors placed posterior to the biceps during SLAP repair are at risk for glenoid vault penetration and/or suprascapular nerve (SSN) injury.
- Vault penetration and SSN injury are avoided by using a Port of Wilmington (PW) portal instead of an anterior portal.
- A percutaneous PW portal is safe and passes through the rotator cuff muscle only.

Table. **Glenoid Vault Penetration by Anchors With Anterosuperolateral and Port of Wilmington Portals**

Specimen	Anterosuperolateral Portal						Port of Wilmington Portal					
	11 o'clock			10 o'clock			11 o'clock			10 o'clock		
	Penetration	Type	SSN, mm	Penetration	Type	SSN, mm	Penetration	Type	SSN, mm	Penetration	Type	SSN, mm
1	Yes	Eyelet	5	Yes	Eyelet	2	No	—	—	No	—	—
2	Yes	Anchor	0	Yes	Anchor	0	No	—	—	No	—	—
3	No	—	—	No	—	—	No	—	—	No	—	—
4	Yes	Eyelet	8	Yes	Anchor	3	Yes	Eyelet	20	Yes	Eyelet	8
5	No	—	—	No	—	—	No	—	—	No	—	—
6	Yes	Eyelet	14	Yes	Eyelet	14	No	—	—	No	—	—

Abbreviation: SSN, suprascapular nerve.

before cuff removal. After overlying soft tissues were removed from a specimen, the anchors were examined for glenoid vault penetration. In the setting of vault penetration, digital calipers were used to measure the shortest distance from anchor to SSN.

Results

In the ASL portal group, 8 (66.7%) of 12 anchors (4/6 at 11 o'clock, 4/6 at 10 o'clock) penetrated the medial glenoid vault. In the 8 penetration cases, mean distance to SSN was 6.8 mm (range, 0-14 mm) for 11 o'clock anchors and 4.8 mm (range, 0-14 mm) for 10 o'clock anchors (Table).

In the PW portal group, 2 (16.7%) of 12 anchors (1/6 at 11 o'clock, 1/6 at 10 o'clock, both from a single specimen) penetrated the medial glenoid vault. Actually, in each case the eyelet and not the anchor penetrated the vault. In the penetration cases, distance to SSN was 20 mm for the 11 o'clock anchor and 8 mm for the 10 o'clock anchor (Table). Of the 6 portals, 3 passed through the supraspinatus muscle, 2 through the infraspinatus musculotendinous junction, and 1 through the infraspinatus muscle.

Discussion

Our study findings support the hypothesis that SLAP repair anchors placed posterior to the biceps tendon are more likely to remain in bone with use of a percutaneous approach relative to an ASL approach. Our findings also support the growing body of evidence that such anchors placed with an anterior approach increase the risk for SSN injury.

Three other cadaveric studies have evaluated anchor placement for SLAP repair. Chan and

colleagues⁷ evaluated drill penetration during bone socket preparation for SLAP repair in 21 matched pairs of formalin-embalmed cadavers. A 20-mm drill was used for correspondence to a 14.5-mm anchor, though no anchors were inserted, and sockets were created in an open manner. Through a mimicked ASL portal, 1 socket was made anterior to the biceps tendon, at 1 o'clock; then, through a mimicked PW portal, 2 sockets were made posterior to the tendon, at 11 o'clock and 9 to 10 o'clock. Glenoid vault penetration occurred in 29% of the 42 anterior sockets, but only 1 anchor (2.4%) touched the SSN. Penetration did not occur with the 11 o'clock anchors. The 9 to 10 o'clock anchor was at highest risk for SSN injury (9.5%, 4 cases). The study was limited by lack of anchor placement and open creation of bone sockets in embalmed cadavers.

Koh and colleagues⁸ evaluated arthroscopic placement of anterior SLAP anchors in 6 matched pairs of fresh-frozen cadavers. Through an ASL portal, each 14.5-mm knotted anchor was placed anterior to the biceps tendon, at 1 o'clock. As in the study by Chan and colleagues,⁷ drill depth was 20 mm. Notably, anchors were seated 2 mm beyond manufacturer recommendations, and the cadavers were of Asian origin, likely indicating smaller glenoids compared to specimens from North America or Europe. All 12 anchors penetrated the glenoid vault; mean distance to SSN was 3.1 mm.

Morgan and colleagues⁹ compared anterior and ASL portals created for SLAP repairs in 10 matched-pair cadavers. Anchors were placed at 1 o'clock, 11 o'clock, and 10 o'clock. As in the studies by Chan and colleagues⁷ and Koh and colleagues,⁸

14.5-mm knotted anchors were used. One anterior anchor (10%) placed through an ASL portal penetrated the cortex by 1 mm, and 2 anterior anchors (20%) placed through anterior portals penetrated the cortex (1 was completely out of the bone). Overall, 65% of 11 o'clock anchors and 100% of 10 o'clock anchors violated the glenoid vault. With the 11 o'clock anchors, mean distance to SSN was 6 mm for ASL portals and 4.2 mm for anterior portals; with the 10 o'clock anchors, mean distance to SSN was 8 mm for ASL portals and 2.1 mm for anterior portals.

Overall, the results of these 3 studies suggest that, with use of ASL portals, placement of SLAP anchors anterior to the biceps tendon is safe. Using the same portals, however, anchors placed posterior to the tendon are at higher risk for glenoid vault penetration. Supporting these findings are our study's penetration rates: 66.7% for anchors placed through ASL portals and 16.7% for anchors placed through percutaneous PW portals. The different rates are not surprising given that the coracoid process projects anterior to the glenoid and provides additional bone stock for placement of anchors anteriorly vs posteriorly. Therefore, with percutaneous PW portals, the approach angle directs the anchor toward the bone of the coracoid base. Furthermore, the SSN passes nearest the posterior aspect of the glenoid. In a study by Shishido and Kikuchi,¹² the distance from the posterior rim of the glenoid to the SSN was 18 mm, and from the superior rim was 29 mm. Therefore, anchors placed with an anterior approach naturally are directed toward the SSN. Given these findings, we think surgeons who repair posterior SLAP tears should place anchors through percutaneous PW portals, not ASL portals, in order to minimize the risks for glenoid vault penetration and SSN injury (Figures 3, 4A-4B).

In addition to portal placement and approach angle, anchor length likely affects the risks for glenoid vault penetration and SSN injury. Koh and colleagues⁹ found a mean distance of 14.2 mm from the glenoid rim to the medial cortex for anchors placed anterior to the biceps tendon and a mean distance of 20.7 mm from the glenoid rim to the SSN. Morgan and colleagues⁹ also evaluated the shortest distance from the glenoid rim to the SSN. Mean distance was 17.9 mm for 10 o'clock anchors and 20.9 mm for 11 o'clock anchors. Whereas the 3 cadaveric studies discussed earlier⁷⁻⁹ examined 14.5-mm knotted anchors with drill depths of 20 mm, we examined 12.5-mm knotless anchors

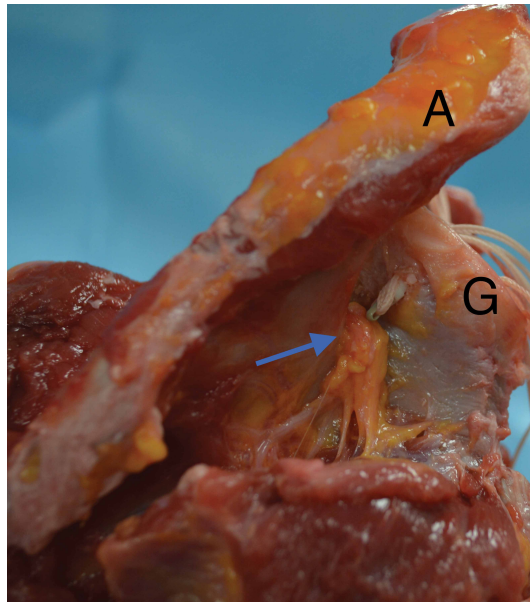


Figure 3. Cadaveric dissection of right shoulder reveals penetration by anchor placed through anterosuperolateral portal. Anchor breaches cortex, and polyetheretherketone (PEEK) eyelet displaces and touches suprascapular nerve (blue arrow).

Abbreviations: A, acromion; G, glenoid.

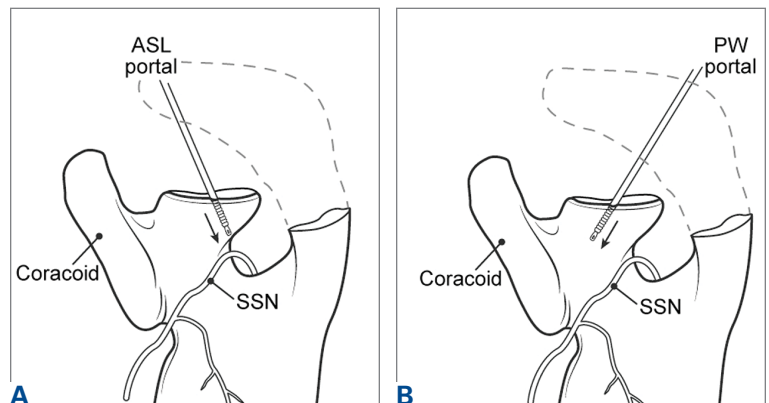


Figure 4. Schematic of anchor placement for superior labrum anterior and posterior (SLAP) repair posterior to biceps through (A) anterosuperolateral (ASL) portal vs (B) Port of Wilmington (PW) portal. Anchors placed posterior to biceps tendon through ASL portal risk glenoid vault penetration and suprascapular nerve (SSN) injury. Anchors placed through PW portal are directed toward base of coracoid and away from SSN.

with drill depths of 18 mm. Even with the 1 anchor penetration that occurred with a percutaneous portal in our study, the SSN was 20 mm from the 11 o'clock portal and 8 mm from the 10 o'clock portal. It is important to note that, for SLAP repair, the biomechanical characteristics of knotless anchors are equivalent to those of knotted anchors.¹³ In addition, knotless anchors offer the advantage of avoiding knot impingement and migration.¹⁴ On that basis, and given the anatomy mentioned, we primarily use short knotless anchors for SLAP repair and think that, as long as biomechanically

supported, the trend should be to use shorter anchors for SLAP repair in order to minimize the risks for glenoid vault penetration and SSN injury.

One limitation of this study was the small number of cadavers, all of which were male. Female cadavers and cadavers of other ethnic origins likely have smaller glenoid vaults, and thus their inclusion would have altered our results. This issue was well described in studies mentioned in this article, and our goal was simply to compare ASL portals with percutaneous PW portals, so we think it does not change the fact that the risks for glenoid vault penetration and SSN injury are reduced with use of PW portals for anchors placed posterior to the biceps tendon.

Conclusion

This study was the first to examine glenoid vault penetration and SSN proximity with short anchors for SLAP repair. The risk for glenoid vault penetration during repair of SLAP tears posterior to the biceps tendon was reduced by anchor placement with a percutaneous posterior approach. The percutaneous posterior approach also directs the anchor away from the SSN.

Dr. Denard is a Shoulder Surgeon, Southern Oregon Orthopedics, Medford, Oregon, and Department of Orthopaedics and Rehabilitation, Oregon Health and Science University, Portland, Oregon. Dr. Adams is an Attending Surgeon, Naples Community Hospital, Naples, Florida, and Vice President of Global Medical Education, Arthrex, Naples, Florida.

Address correspondence to: Patrick J. Denard, MD, 2780 E. Barnett Rd, Suite 200, Medford, OR 97504 (tel, 541-779-6250; email, pjenard@gmail.com).

Am J Orthop. 2017;46(1):E60-E64. Copyright Frontline Medical Communications Inc. 2017. All rights reserved.

References

1. Snyder SJ, Banas MP, Karzel RP. An analysis of 140 injuries to the superior glenoid labrum. *J Shoulder Elbow Surg.* 1995;4(4):243-248.
2. Denard PJ, Lädermann A, Burkhart SS. Long-term outcome after arthroscopic repair of type II SLAP lesions: results according to age and workers' compensation status. *Arthroscopy.* 2012;28(4):451-457.
3. Gorantla K, Gill C, Wright RW. The outcome of type II SLAP repair: a systematic review. *Arthroscopy.* 2010;26(4):537-545.
4. Weber SC, Martin DF, Seiler JG 3rd, Harrast JJ. Superior labrum anterior and posterior lesions of the shoulder: incidence rates, complications, and outcomes as reported by American Board of Orthopedic Surgery. Part II candidates. *Am J Sports Med.* 2012;40(7):1538-1543.
5. Kim SH, Koh YG, Sung CH, Moon HK, Park YS. Iatrogenic suprascapular nerve injury after repair of type II SLAP lesion. *Arthroscopy.* 2010;26(7):1005-1008.
6. Yoo JC, Lee YS, Ahn JH, Park JH, Kang HJ, Koh KH. Isolated suprascapular nerve injury below the spinoglenoid notch after SLAP repair. *J Shoulder Elbow Surg.* 2009;18(4):e27-e29.
7. Chan H, Beaupre LA, Bouliane MJ. Injury of the suprascapular nerve during arthroscopic repair of superior labral tears: an anatomic study. *J Shoulder Elbow Surg.* 2010;19(5):709-715.
8. Koh KH, Park WH, Lim TK, Yoo JC. Medial perforation of the glenoid neck following SLAP repair places the suprascapular nerve at risk: a cadaveric study. *J Shoulder Elbow Surg.* 2011;20(2):245-250.
9. Morgan RT, Henn RF 3rd, Paryavi E, Dreesse J. Injury to the suprascapular nerve during superior labrum anterior and posterior repair: is a rotator interval portal safer than an anterosuperior portal? *Arthroscopy.* 2014;30(11):1418-1423.
10. Lo IK, Lind CC, Burkhart SS. Glenohumeral arthroscopy portals established using an outside-in technique: neurovascular anatomy at risk. *Arthroscopy.* 2004;20(6):596-602.
11. Morgan CD, Burkhart SS, Palmeri M, Gillespie M. Type II SLAP lesions: three subtypes and their relationships to superior instability and rotator cuff tears. *Arthroscopy.* 1998;14(6):553-565.
12. Shishido H, Kikuchi S. Injury of the suprascapular nerve in shoulder surgery: an anatomic study. *J Shoulder Elbow Surg.* 2001;10(4):372-376.
13. Uggen C, Wei A, Glousman RE, et al. Biomechanical comparison of knotless anchor repair versus simple suture repair for type II SLAP lesions. *Arthroscopy.* 2009;25(10):1085-1092.
14. Kim SH, Crater RB, Hagens AR. Movement-induced knot migration after anterior stabilization in the shoulder. *Arthroscopy.* 2013;29(3):485-490.