

Pronator Teres Myotendinous Tear

Usama Qayyum, MBBS, Diego Villacis, MD, and Charles M. Jobin, MD

Abstract

Pronator teres muscle strain is a rare sporting injury reported thus far only in cricket and golf players. The injury appears to occur when the sporting club or racket strikes the ground during a forceful swing and causes the elbow to experience an eccentric force during resisted elbow flexion and pronation. On initial presentation, this injury can be mistaken for injury to the medial ulnar collateral ligament, or exacerbation of medial epicondylitis. On examination, bruising and tenderness distal to the elbow over the course of the pronator teres are often present. Advanced imaging confirms the diagnosis and can help in grading injury severity. In this article, we report the case of a patient who was conservatively treated, and returned to function and sport by 6 weeks after a period of rest and restricted activities. The prognosis is excellent for even high-grade strains. Complete return to sporting function without residual weakness is expected.

Pronator teres muscle strain is a rare sporting injury reported only in cricket players, and now in a golfer whose forearm experienced an eccentric force during resisted elbow flexion and pronation.^{1,2} The injury occurs when the sporting club or racket strikes the ground during a swing, impeding forward progress and subjecting the pronator teres muscle to eccentric forces in excess of what it can withstand. The pronator teres, one of several muscles that comprise the flexor wad of the forearm, consists of 2 heads, originating proximally from the medial epicondyle and attaching distally to the shaft of the radius on its lateral surface and just distal to the supinator.

The oblique orientation of the muscle belly allows it to serve in its primary rotatory role as the main pronator of the forearm. Injuries to the soft tissue of the medial forearm are common in both elite and recreational athletes, especially in racket and club sports.³ Often, these injuries are related to overuse and chronic fatigue of the surrounding soft tissue—caused by repetitive flexing, gripping, or swinging. Even when identified early, these injuries can result in a significant loss of training time.⁴ In this article, we report a case of pronator teres muscle tear at the myotendinous junction. The patient provided written informed consent for print and electronic publication of this case report.

Case Report

A right-hand-dominant 36-year-old man presented to the clinic with pain on the medial side of his

Take-Home Points

- Pronator teres muscle injuries are rare.
- Injury can be mistaken for MUCL injury in athletes.
- Tenderness and weak/painful forearm pronation are common findings.
- MRI confirms the diagnosis and helps grade the muscle strain injury.
- Conservative treatment is recommended and prognosis is excellent even for high-grade strains.

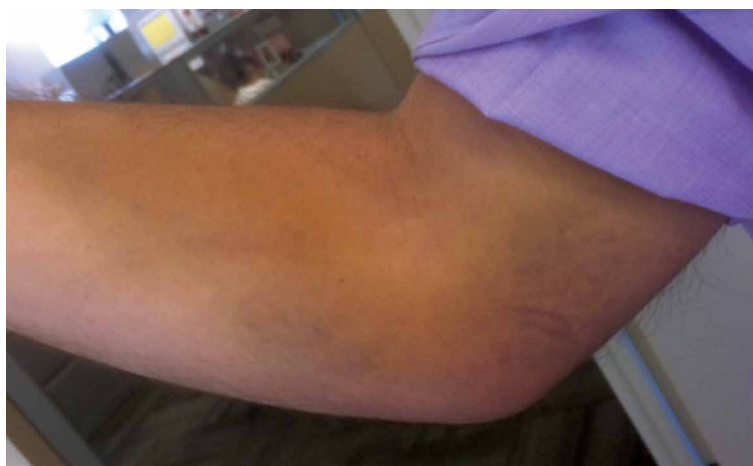

Figure 1. Medial elbow with non-gravity-dependent ecchymosis over course of pronator teres muscle, 3 days after injury.

Authors' Disclosure Statement: The authors report no actual or potential conflict of interest in relation to this article.

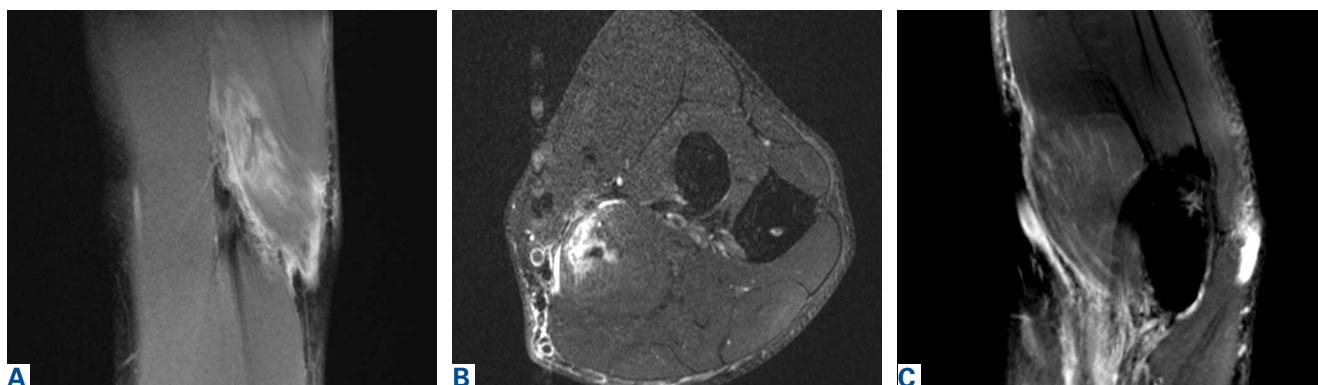


Figure 2. (A) Coronal T2-weighted magnetic resonance imaging (MRI) shows isolated edema of pronator teres and partial tearing of muscle belly near the myotendinous junction. (B) Axial T2-weighted MRI of proximal forearm shows edema of pronator teres muscle belly and fluid around the myotendinous zone of injury. (C) Sagittal T2-weighted MRI of the pronator teres injury.

right elbow after sustaining an injury to the elbow while playing golf several days earlier. The patient, an advertising executive, was playing recreational golf several times a month and had no significant medical history or previous symptoms related to the elbow. Initial pain symptoms began during a second round of play, immediately after the patient miss-hit an iron shot, making contact mostly with the ground and causing the club to forcefully stop. The pain was on the medial side of the elbow and forearm. The patient noted progressive swelling and bruising at the pain site and development of forearm weakness. Physical examination during the clinic presentation revealed ecchymosis on the anterior medial forearm, medial elbow, and medial triceps (**Figure 1**). Mild tenderness to palpation was elicited over the medial elbow, specifically over the course of the flexor pronator mass. When the elbow was assessed for tender areas, the medial epicondyle was not tender. Range of motion (ROM) testing revealed 120° of flexion and 10° short of full extension, attributed to swelling from acute injury. The patient had full supination and pronation, but the pain was reproduced with either movement. The pain produced weakness with flexion and pronation. Valgus stress test results were normal; there was no re-creation of symptoms. The median nerve was negative for the Tinel sign, and the rest of the neurovascular examination was unremarkable. The ipsilateral shoulder was normal on examination.

Noncontrast magnetic resonance imaging (MRI) showed a high-grade partial tear of the pronator teres myotendinous junction (**Figures 2A-2C**). In the surrounding tissue there was an associated increased signal representing edema. Also found was a small intramuscular hematoma. The median nerve, medial collateral ligament, distal biceps, and

triceps were uninjured.

The patient was instructed to rest the elbow from strenuous activity, golf in particular, for 4 weeks. Physical therapy for ROM and forearm strengthening of the surrounding flexor was initiated at 2 weeks and continued for 4 weeks. The patient was advised to take over-the-counter nonsteroidal anti-inflammatory drugs as needed for comfort. On repeat examination at 4 weeks, with tenderness or weakness with pronation absent and full ROM regained, the patient was released back to full activity. He was able to return to golf and reported being symptom-free and having no sense of weakness or loss of control.

Discussion

A tear of the pronator teres is an exceedingly rare injury. Our results with conservative treatment and a full return to previous activity level are consistent with the only other case reported in the literature.⁵ In contrast to our patient, the previous patient sustained a tear of the pronator teres after a prolonged period of batting during a recreational cricket match.

Our patient's pronator teres injury occurred at the myotendinous junction, a muscle-tendon transition zone often susceptible to injury. What is unusual for this athletic medial elbow injury is that the patient reported no previous symptoms, and it appears that, though the surrounding muscle may have been fatigued by overuse from the round of golf earlier that day, the pathology was caused by an acute eccentric force. During a golf swing, tremendous forces are put on the entire body, from the lower extremities to the forearm and the fingers. Successful completion of the transfer of energy from the golf club to the ball requires both

proper technique and proper functioning of key muscles. Specifically, parameters such as ball positioning, club angle, and wrist control play a major role.⁶ Altered forearm positioning or swing arc can significantly affect club head velocity and energy transfer without putting more stress on the golfer.⁷ Therefore, it is easy to understand how prolonged or extended play may fatigue the surrounding elbow muscles, leading to altered technique and increased susceptibility to acute injury. Biomechanical analysis of shoulder motion can provide a helpful baseline for assessing injury-related changes in golf swing and developing specific exercise and rehabilitation programs.^{8,9}

Although injury to the pronator teres is rare, sport physicians should be aware that, after a valgus stress or force, bruising and swelling along the medial elbow do not always indicate a medial ulnar collateral ligament (MUCL) tear or medial epicondylitis. The key examination findings that differentiate this injury from a MUCL injury are the exact location of pain, the milking maneuver for MUCL incompetence, and the extensive bruising over the muscle course of the pronator teres. MRI plays a pivotal role in proper diagnosis.⁴ In addition, MRI allows for evaluation of any concomitant injuries that may be obscuring the clinical presentation.

Successful treatment of such injuries is important for both elite and recreational athletes. With rest and physical therapy, our patient recovered from this rare isolated injury to the pronator teres with complete resolution of symptoms and full ROM. In the literature, we found no other reports of isolated full-thickness myotendinous rupture of the pronator teres or avulsion from the medial epicondyle. Therefore, it is unclear whether the same outcome can be expected with conservative therapy. However, because of the good outcomes for partial-thickness injuries treated conservatively and the lack of robust tendinous tissue to repair at the myotendinous junction, we recommend an initial course of conservative treatment. Sports physicians should be aware of this exceedingly rare injury to the elbow and understand the large forces experienced by the soft tissues of the forearm during the golf swing.^{9,10}

Conclusion

Pronator teres muscle strain is a rare sporting injury reported in cricket and golf players. The elbow experiences a large eccentric force during resisted elbow flexion and pronation. The injury appears to

occur when the sporting club or racket strikes the ground during a forceful swing impeding forward progress of the arm. The injury can be confused with a MUCL injury, or exacerbation of medial epicondylitis. Physical examination reveals bruising and tenderness over the course of the pronator teres, often distal to the elbow. Advanced imaging confirms the diagnosis and helps grade the severity of muscle strain. Treatment is often conservative, with return to function and sport after 4 to 6 weeks of rest and restricted activities. The patient in this case report had complete return to sporting function, with no residual weakness or pain.

Dr. Qayyum is a Research Fellow, Columbia University Department of Orthopedics, New York, New York. Dr. Villacis is a Clinician Educator, Orthopedic Surgeon, NorthShore University Health System, a teaching affiliate of The University of Chicago Pritzker School of Medicine, Glenview, Illinois. Dr. Jobin is Assistant Professor of Orthopaedic Surgery and Residency Program Director, Department of Orthopaedic Surgery, New York Presbyterian/Columbia University Medical Center, New York, New York.

Address correspondence to: Charles M. Jobin, MD, Department of Orthopaedic Surgery, New York Presbyterian/Columbia University Medical Center, 622 W 168th St, New York, NY 10032 (tel, 212-305-6445; fax, 212-305-4040; email, jobin@columbia.edu).

Am J Orthop. 2017;46(2):E105-E107. Copyright Frontline Medical Communications Inc. 2017. All rights reserved.

References

1. Field LD, Savoie FH. Common elbow injuries in sport. *Sports Med.* 1998;26(3):193-205.
2. Loomer RL. Elbow injuries in athletes. *Can J Appl Sport Sci.* 1982;7(3):164-166.
3. Dines JS, Bedi A, Williams PN, et al. Tennis injuries: epidemiology, pathophysiology, and treatment. *J Am Acad Orthop Surg.* 2015;23(3):181-189.
4. Banks KP, Ly JQ, Beall DP, Grayson DE, Bancroft LW, Tall MA. Overuse injuries of the upper extremity in the competitive athlete: magnetic resonance imaging findings associated with repetitive trauma. *Curr Probl Diagn Radiol.* 2005;34(4):127-142.
5. Niebulski HZ, Richardson ML. High-grade pronator teres tear in a cricket batsman. *Radiol Case Rep.* 2015;6(3):540.
6. Zhang X, Shan G. Where do golf drive swings go wrong? Factors influencing driver swing consistency. *Scand J Med Sci Sports.* 2014;24(5):749-757.
7. Nesbit SM, McGinnis RS. Kinetic constrained optimization of the golf swing hub path. *J Sports Sci Med.* 2014;13(4):859-873.
8. Helton MS. Conservative treatment of a proximal full-thickness biceps brachii muscle tear in a special operations soldier. *Phys Ther.* 2014;94(4):571-577.
9. Mitchell K, Banks S, Morgan D, Sugaya H. Shoulder motions during the golf swing in male amateur golfers. *J Orthop Sports Phys Ther.* 2003;33(4):196-203.
10. Grimshaw P, Giles A, Tong R, Grimmer K. Lower back and elbow injuries in golf. *Sports Med.* 2002;32(10):655-666.