

Arthroscopic Excision of Bipartite Patella With Preservation of Lateral Retinaculum in an Adolescent Ice Hockey Player

Evan W. James, MD, Christopher M. LaPrade, BA, Jorge Chahla, MD, Mark E. Cinque, BS, MS, Nicholas I. Kennedy, MD, and Robert F. LaPrade, MD, PhD

Abstract

Bipartite patella usually is an asymptomatic anatomical variant. However, in some adolescent athletes, it causes anterior knee pain, resulting in decreased participation and performance.

We report the case of a high-level adolescent ice hockey player who underwent successful arthroscopic excision with preservation of the lateral retinaculum of a symptomatic bipartite patella after failed nonoperative treatment. The patient returned to play by 6 weeks, and 31-month subjective follow-up scores showed high satisfaction and good clinical outcomes.

For patients with a symptomatic bipartite patella, arthroscopic surgery is a good option for reducing pain and returning the athlete to competition.

In 2% to 3% of the general population, the finding of bipartite patella on knee radiographs is often incidental.^{1,2} During development, the patella normally originates in a primary ossification center. Occasionally, secondary ossification centers emerge around the margins of the primary center and typically join that center. In some cases, the secondary² center remains separated, leading to patella partita and an accessory patellar fragment.^{3,4}

The bipartite patella is connected to the primary patella by fibrocartilage. The fibrous attachment may become irritated or separated as a result of trauma, overuse, or strenuous activity.^{1,5-7} Saupé classifi-

cation of bipartite patella is based on accessory patellar fragment location: type I, inferior pole; type II, lateral margin; and type III, superior lateral pole.⁸ When an individual with a bipartite patella becomes symptomatic, anterior knee pain (AKP) is the most common complaint—it has been described in adolescent athletes in numerous sports.^{7,9-11}

For most patients, first-line treatment is nonoperative management. A typical regimen includes reduced activity, use of nonsteroidal anti-inflammatory drugs, physical therapy, and isometric quadriceps-strengthening exercises.^{1,12} Other nonoperative approaches described in the literature are immobilization,^{5,10} steroid and anesthetic injection, and ultrasound therapy.¹³ If symptoms do not improve, surgical treatment should be considered. Surgical treatment options include open excision of fragment,^{3,9,12} arthroscopic excision of fragment,^{7,14,15} tension band wiring,^{5,16} open reduction and internal fixation,¹⁷ open or arthroscopic vastus lateralis release,¹⁸⁻²⁰ and lateral retinacular release.²¹ However, the optimal surgical option remains controversial.

In this case report, we present a modification of an arthroscopic surgical technique for excising a symptomatic bipartite patella and report midterm clinical outcomes. The patient provided written informed consent for print and electronic publication of this report.

Take-Home Points

- Bipartite patella is an asymptomatic anatomical variant.
- Occasionally, some adolescent athletes can present with AKP, resulting in decreased participation and performance.
- Bipartite patella is classified in type I, inferior pole; type II, lateral margin; and type III, superior lateral pole, depending on where the accessory patellar fragment is.
- Nonoperative treatment is advocated first. If symptoms persist surgical treatment should be attempted.

Authors' Disclosure Statement: Dr. R. F. LaPrade reports that he is a consultant to and receives royalties from Arthrex, Össur, and Smith & Nephew. The other authors report no actual or potential conflict of interest in relation to this article.

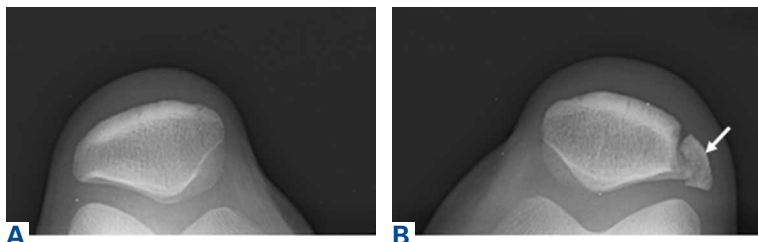


Figure 1. Preoperative (A) anteroposterior and (B) lateral sunrise radiographs of the left knee show laterally based bipartite patella (white arrow).

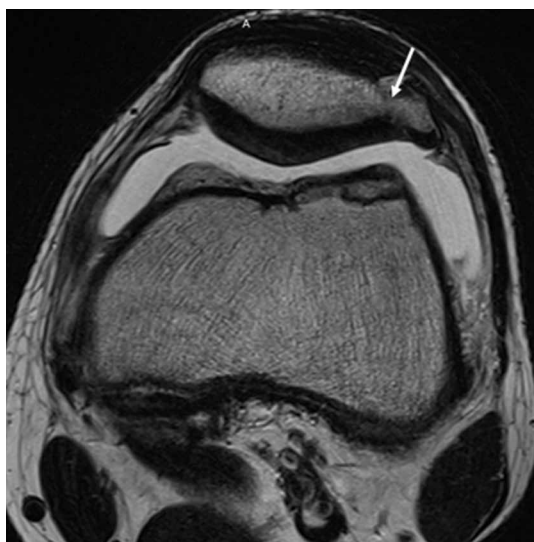


Figure 2. Axial magnetic resonance imaging shows damaged fibrocartilage bridge (white arrow) and bipartite patella separated from the primary patella.

Case Report

A 16-year-old elite male ice hockey player presented to clinic with a 2-week history of left AKP. He could not recall a specific injury that triggered the symptoms. Radiographs were obtained at an outside institution, and knee patellar fracture was diagnosed. The patient, placed in a straight-leg immobilizer, later presented to a referral clinic for a second opinion and further evaluation. Physical examination revealed significant tenderness to palpation of the lateral aspect of the patella. Range of motion was symmetric and fully intact. Patellar mobility was excellent. However, the patient could not perform a straight-leg raise because of the pain.

We obtained anteroposterior and lateral radiographs (**Figures 1A, 1B**), which showed evidence of a Saupé type III bipartite patella with separation at the superolateral pole. A magnetic resonance imaging (MRI) series was ordered for further evaluation of the soft tissues (**Figure 2**). There

was bony edema in the anteromedial aspect of the distal femur. The visualized patella showed no evidence of fracture, though there was evidence of disruption through the fibrous attachments of the bipartite patella fragment. Physical therapy (range-of-motion exercises, quadriceps sets, and stationary bicycling) was initiated. By 6 weeks, the patient's discomfort had resolved, and he resumed on-ice activities as tolerated.

Two years later, the patient returned with left AKP, again localized to the lateral aspect of the patella, over the bipartite fragment. The pain was significant with compression. Given the patient's history, arthroscopic excision of the bipartite patella was recommended. After discussing all treatment options, the patient elected to proceed with the surgery.

Surgical Technique

The patient was positioned supine on the operating table. Medial and lateral parapatellar arthroscopic portals were created. Menisci, cruciate ligaments, and tibiofemoral articular cartilage were arthroscopically visualized and determined to be normal. The bipartite patella was easily visualized, and notably loose when probed. Grade 2 chondromalacia was present diffusely throughout the bipartite patella and on the far lateral aspect of the patella, at the fragment interface.

Attention was then turned to arthroscopic removal of the accessory patellar fragment (**Figures 3A, 3B**). An accessory superolateral arthroscopic portal was created to improve surgical instrument access. Round and oval burrs, straight and curved shavers, pituitary rongeur, curettes, and small osteotome were used to meticulously excise the accessory bipartite patella fragment, leaving the overlying (anterior) retinaculum intact. After the fragment was excised, the region was palpated, and no additional loose fragments were felt (**Figures 4A, 4B**). The remaining patellar articular cartilage was intact. On palpation, the patella did not sublux medially, indicating the lateral retinaculum was well maintained during excision of the patella fragment.

Postoperative Rehabilitation

Rehabilitation focused on protection of the healing patella and accelerated rehabilitation for early return to play. Range-of-motion exercises and stationary bicycling were initiated on postoperative day 1. Weight-bearing was allowed as tolerated. Quadriceps sets, straight-leg raises, and ankle pumps were

performed 5 times daily for 6 weeks. Six weeks after surgery, the patient was cleared, and he returned to full on-ice activities.

Outcomes

This study was approved by an Institutional Review Board. Preoperative and postoperative outcomes were obtained and stored in a data registry. The patient's Lysholm score²² improved from 71 before surgery to 100 at 31-month follow-up. In addition, his subjective International Knee Documentation Committee score²³ improved from 65.5 before surgery to 72.4 after surgery. At follow-up, patient satisfaction with outcome was 10/10. In addition, the patient had returned to playing hockey at a higher national level without functional limitation.

Discussion

The most important finding in this case is that arthroscopic excision of a bipartite patella with preservation of the lateral retinaculum in an elite adolescent hockey player resulted in improved subjective clinical outcomes scores and early return to competition. Arthroscopic excision was favored over open excision in this patient because of potential quicker recovery,¹⁴ less pain, and expedited return to competition. In addition, previous arthroscopic techniques were modified to shorten postoperative rehabilitation. The modified technique included preservation of the lateral retinaculum and total arthroscopic excision of the accessory bipartite patella fragment.

Although results of open techniques have been favorable,^{3,8,9} these procedures are far more invasive than arthroscopic techniques and may result in loss of quadriceps strength and prolonged rehabilitation.¹⁸ Weckström and colleagues¹² followed 25 male military recruits for a minimum of 10 years after open excision of symptomatic bipartite patella. Mean Kujala score was 95 (range, 75-100), and median visual analog scale score for knee pain was 1.0 (range, 0.0-6.0). In a study by Bourne and Bianco,³ 13 of 16 patients who were followed for an average of 7 years experienced complete pain relief with an average recovery time of 2 months.

Other studies have described the arthroscopic excision technique for symptomatic bipartite patella,^{7,14,15} but outcomes are underreported, especially for follow-ups longer than 2 years. Felli and colleagues⁷ described a case of arthroscopic excision and lateral release in a 23-year-old female professional volleyball player; at 1-year follow-up,

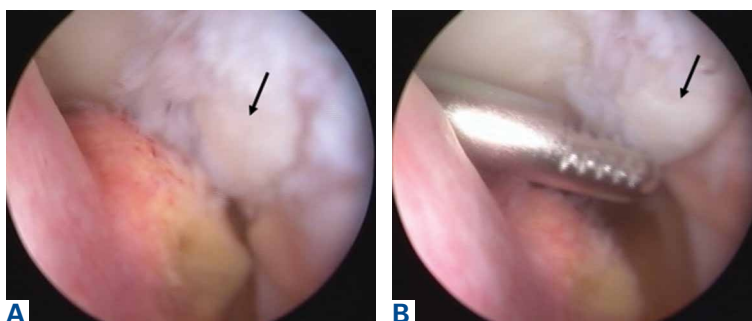


Figure 3. (A) Arthroscopy shows bipartite patella fragment (black arrow). (B) Fibrocartilage bridge connecting bipartite patella (black arrow) to the primary patella was excised with a straight shaver to facilitate removal of the bony fragment.

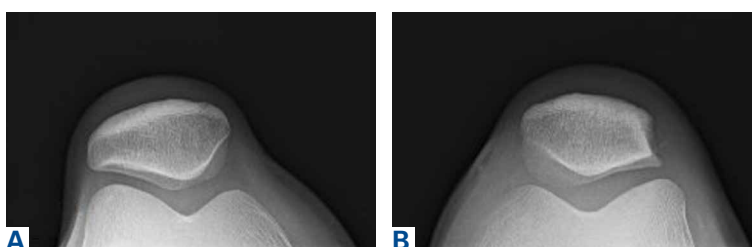


Figure 4. Postoperative (A) anteroposterior and (B) lateral sunrise radiographs of bilateral knees show complete extraction of symptomatic fragment of bipartite patella.

the patient was symptom-free and back to full athletic participation. Azarbod and colleagues¹⁴ also reported on a patient who was symptom-free, 6 weeks after arthroscopic excision of bipartite patella. Carney and colleagues¹⁵ indicated that successful excision of bipartite patella was evident on 6-month radiographic follow-up. Our 31-month follow-up is the longest of any study on arthroscopic excision of bipartite patella. Clinical outcomes were excellent both in our patient's case and in the earlier studies.

Our patient was a high-level hockey player who wanted to return to competition as quickly as possible. Conservative management, including physical therapy, initially resolved his symptoms and allowed him to resume on-ice activities after 6 weeks. In time, however, his symptoms returned and began limiting his on-ice performance. Arthroscopic removal of the bipartite patella accessory fragment allowed him to return to full on-ice activities after 6 weeks. His case provides evidence that arthroscopic management of bipartite patella with preservation of the vastus lateralis and lateral retinaculum may be an excellent treatment option for patients who want to return to athletics as quickly as possible.

Our technique of arthroscopic excision with preservation of lateral retinaculum is an excellent

treatment option for symptomatic bipartite patella. This option, combined with an aggressive rehabilitation protocol, allows for pain relief and expedited return to competition.

Dr. James is a Resident, Hospital for Special Surgery, New York, New York. Mr. C. M. LaPrade is a Medical Student, Medical College of Wisconsin, Milwaukee, Wisconsin. Dr. Chahla is Regenerative Sports Medicine Fellow, Steadman Philippon Research Institute, Vail, Colorado. Dr. R. F. LaPrade is Chief Medical Officer, The Steadman Clinic, Vail, Colorado.

Address correspondence to: Robert F. LaPrade, MD, PhD, The Steadman Clinic, 181 W Meadow Dr, Suite 400, Vail, CO 81657 (tel, 970-476-1100; fax, 970-479-5813; email, drlaprade@sprivaail.org).

Am J Orthop. 2017;46(3):135-138. Copyright Frontline Medical Communications Inc. 2017. All rights reserved.

References

1. Atesok K, Doral MN, Lowe J, Finsterbush A. Symptomatic bipartite patella: treatment alternatives. *J Am Acad Orthop Surg.* 2008;16(8):455-461.
2. Insall J. Current concepts review: patellar pain. *J Bone Joint Surg Am.* 1982;64(1):147-152.
3. Bourne MH, Bianco AJ Jr. Bipartite patella in the adolescent: results of surgical excision. *J Pediatr Orthop.* 1990;10(1):69-73.
4. Oohashi Y, Koshino T, Oohashi Y. Clinical features and classification of bipartite or tripartite patella. *Knee Surg Sports Traumatol Arthrosc.* 2010;18(11):1465-1469.
5. Okuno H, Sugita T, Kawamata T, Ohnuma M, Yamada N, Yoshizumi Y. Traumatic separation of a type I bipartite patella: a report of four knees. *Clin Orthop Relat Res.* 2004;(420):257-260.
6. Yoo JH, Kim EH, Ryu HK. Arthroscopic removal of separated bipartite patella causing snapping knee syndrome. *Orthopedics.* 2008;31(7):717.
7. Felli L, Fiore M, Bigliani L. Arthroscopic treatment of symptomatic bipartite patella. *Knee Surg Sports Traumatol Arthrosc.* 2011;19(3):398-399.
8. Green WT Jr. Painful bipartite patellae. A report of three cases. *Clin Orthop Relat Res.* 1975;(110):197-200.
9. Ishikawa H, Sakurai A, Hirata S, et al. Painful bipartite patella in young athletes. The diagnostic value of skyline views taken in squatting position and the results of surgical excision. *Clin Orthop Relat Res.* 1994;(305):223-228.
10. Stocker RL, van Laer L. Injury of a bipartite patella in a young upcoming sportsman. *Arch Orthop Trauma Surg.* 2011;131(1):75-78.
11. Wong CK. Bipartite patella in a young athlete. *J Orthop Sports Phys Ther.* 2009;39(7):560.
12. Weckström M, Parviainen M, Pihlajamäki HK. Excision of painful bipartite patella: good long-term outcome in young adults. *Clin Orthop Relat Res.* 2008;466(11):2848-2855.
13. Kumahashi N, Uchio Y, Iwasa J, Kawasaki K, Adachi N, Ochi M. Bone union of painful bipartite patella after treatment with low-intensity pulsed ultrasound: report of two cases. *Knee.* 2008;15(1):50-53.
14. Azarbod P, Agar G, Patel V. Arthroscopic excision of a painful bipartite patella fragment. *Arthroscopy.* 2005;21(8):1006.
15. Carney J, Thompson D, O'Daniel J, Cassidy J. Arthroscopic excision of a painful bipartite patella fragment. *Am J Orthop.* 2010;39(1):40-43.
16. Tauber M, Matis N, Resch H. Traumatic separation of an uncommon bipartite patella type: a case report. *Knee Surg Sports Traumatol Arthrosc.* 2007;15(1):83-87.
17. Werner S, Durkan M, Jones J, Quilici S, Crawford D. Symptomatic bipartite patella: three subtypes, three representative cases. *J Knee Surg.* 2013;26(suppl 1):S72-S76.
18. Adachi N, Ochi M, Yamaguchi H, Uchio Y, Kuriwaka M. Vastus lateralis release for painful bipartite patella. *Arthroscopy.* 2002;18(4):404-411.
19. Maeno S, Hashimoto D, Otani T, Masumoto K, Hui C. The "coiling-up procedure": a novel technique for extra-articular arthroscopy. *Arthroscopy.* 2010;26(11):1551-1555.
20. Ogata K. Painful bipartite patella. A new approach to operative treatment. *J Bone Joint Surg Am.* 1994;76(4):573-578.
21. Mori Y, Okumo H, Iketani H, Kuroki Y. Efficacy of lateral retinacular release for painful bipartite patella. *Am J Sports Med.* 1995;23(1):13-18.
22. Lysholm J, Gillquist J. Evaluation of knee ligament surgery results with special emphasis on use of a scoring scale. *Am J Sports Med.* 1982;10(3):150-154.
23. Grevnerts HT, Terwee CB, Kvist J. The measurement properties of the IKDC-subjective knee form. *Knee Surg Sports Traumatol Arthrosc.* 2015;23(12):3698-3706.

This paper will be judged for the Resident Writer's Award.