

THE CLINICAL PICTURE

ARAM BARBARYAN, MD

Department of Medicine,
HSHS Saint Mary's Hospital, Decatur, IL

JIGNESH MODI, MD

Department of Infectious Disease,
HSHS Saint Mary's Hospital, Decatur, IL

WAJIH RAQEEM, MD

Department of Medicine,
HSHS Saint Mary's Hospital, Decatur, IL

MICHAEL I. CHOI, MD

Department of Pathology,
HSHS Saint Mary's Hospital, Decatur, IL

ALAN FRIGY, MD

Department of Pathology,
HSHS Saint Mary's Hospital, Decatur, IL

AIBEK E. MIRRAKHIMOV, MD

Department of Medicine,
University of Kentucky School of Medicine,
Lexington, KY

Ring-enhancing cerebral lesions

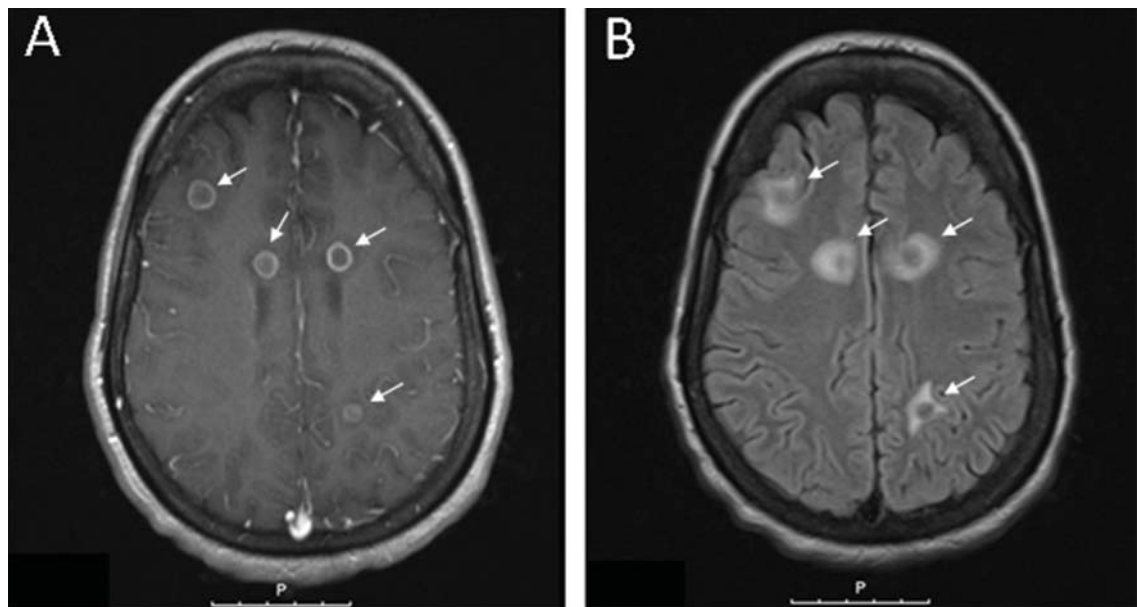


FIGURE 1. (A) Axial contrast-enhanced T1-weighted magnetic resonance imaging showed ring-enhancing lesions (white arrows), while (B) axial T2-weighted images showed ring-enhancing lesions surrounding hyperintensity, consistent with vasogenic edema (white arrows).

She has poorly controlled HIV, seizures, and brain lesions; is it *Histoplasma* or *Toxoplasma*?

A 39-YEAR-OLD WOMAN with a history of human immunodeficiency virus (HIV) and hepatitis B virus infection was brought to the emergency department for evaluation of seizures, which had started a few days earlier. She was born and raised in a state bordering the Ohio River, an area where *Histoplasma capsulatum* is endemic. She denied any recent travel.

Her vital signs and neurologic examination were normal. Computed tomography of the head showed two areas of increased attenuation anterior to the frontal horns. To better characterize those lesions, magnetic resonance imaging (MRI) with contrast was done, which showed about a dozen 1-cm ring-enhancing lesions in the right cerebellum and both cerebral hemispheres (Figure 1).

Results of a complete blood cell count, metabolic profile, and chest radiography were normal. Her CD4 count was 428/ μ L (reference range 533–1,674) and 20% (60%–89%); her HIV viral load was 326,000 copies/mL.

She was initially treated empirically with sulfadiazine, pyrimethamine, and leukovorin for possible toxoplasmosis, which is the most common cause of ring-enhancing brain lesions in HIV patients. In the meantime, cerebrospinal fluid, blood, and urine were sent for a detailed workup for fungi, including *Histoplasma*. Results of the *Histoplasma* antibody and antigen studies of the serum, urine, and cerebrospinal fluid were positive, while cerebrospinal fluid testing for *Toxoplasma* by polymerase chain reaction testing was negative. Empirical treatment for toxoplasmosis was stopped and amphotericin B was started to treat disseminated histoplasmosis.

doi:10.3949/ccjm.84a.16037

During her hospital course, she underwent brain biopsy via right frontotemporal craniotomy with resection of right frontal lesions. Pathologic study showed partially organizing abscesses with central necrosis (**Figure 2**), microscopy with Grocott-Gomori methenamine silver stain was positive for budding yeast forms consistent with *H capsulatum* (**Figure 3**), and special stain for acid-fast bacilli was negative for mycobacteria. Cultures of the brain biopsy specimen, blood, and cerebrospinal fluid for fungi, acid-fast bacilli, and bacteria did not reveal any growth after 28 days.

The patient was discharged home with instructions to take amphotericin B for a total of 6 weeks and then itraconazole. About 1 year later, she remained free of symptoms, although repeat MRI did not show any significant change in the size or number of histoplasmosis.

She did not comply well with her HIV treatment, and her immune status did not improve, so we decided to continue her itraconazole treatment for more than 1 year.

■ CEREBRAL HISTOPLASMOMA

The term “histoplasmosis” was introduced by Shapiro et al¹ in 1955, when they first described numerous focal areas of softening, up to 1 cm in diameter, scattered throughout the brain at autopsy in a 41-year-old man who had died of disseminated histoplasmosis. They coined the word to describe these discrete areas of necrosis that might resemble tumors on the basis of their size, location, and capability of causing increased intracranial pressure.

Central nervous system involvement can either be a manifestation of disseminated disease or present as an isolated illness.² It occurs in 5% to 10% of cases of disseminated histoplasmosis.³ Histoplasmosis of the central nervous system can have different manifestations; the most common presentation is chronic meningitis.⁴

Laboratory diagnosis is based on detecting *H capsulatum* antigen and antibody in the urine, blood, and cerebrospinal fluid. Tissue biopsy (histopathology) as well as cultures of tissue samples or body fluids may also establish the diagnosis.⁴

Toxoplasmosis and primary central nervous system lymphoma are the most common

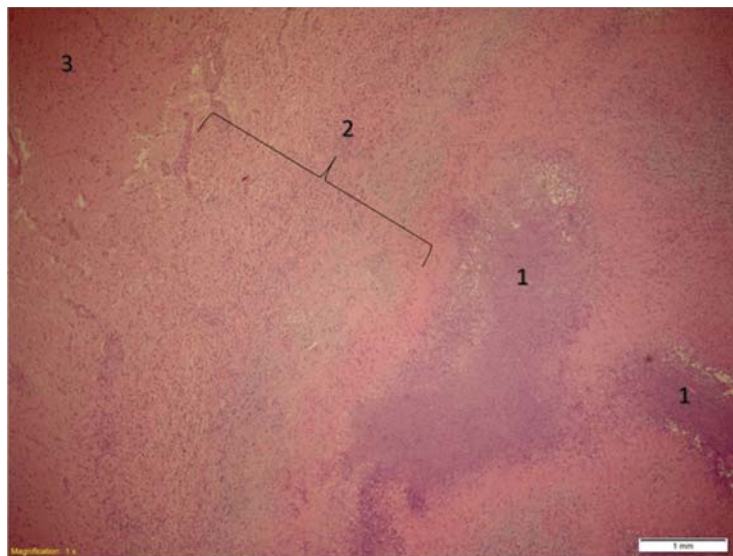


FIGURE 2. Partially organizing central nervous system abscess showing necrosis with acute inflammatory cells (1), fibrosis with acute and chronic inflammatory cells (2), and the normal-appearing brain tissue (3) (hematoxylin and eosin, $\times 4$).

causes of brain ring-enhancing lesions in HIV patients in developed countries, while in the developing world neurocysticercosis and tuberculomas are more common.^{5,6} Much less common causes include brain abscesses secondary to bacterial infections (pyogenic abscess),⁷ cryptococcomas,⁸ syphilitic cerebral gummata,⁹ primary brain tumors (gliomas), and metastases.¹⁰

Compared with other forms of the disease, histoplasmosis of the central nervous system has higher rates of treatment failure and relapse, so treatment should be prolonged and aggressive.^{2,3} The cure rate with amphotericin B ranges from 33% to 61%, and higher doses produce better response rates.³

Current treatment recommendations are based on 2007 guidelines of the Infectious Diseases Society of America.¹¹ Liposomal amphotericin B is the drug of choice because it achieves higher concentrations in the central nervous system than other drugs and is less toxic. It is given for 4 to 6 weeks, followed by itraconazole for at least 1 year and until the cerebrospinal fluid *Histoplasma* antigen test is negative and other cerebrospinal fluid abnormalities are resolved.

In patients who have primary disseminated histoplasmosis that includes the cen-

Itraconazole can be continued long-term—lifelong if necessary

CONTINUED ON PAGE 110

CONTINUED FROM PAGE 105

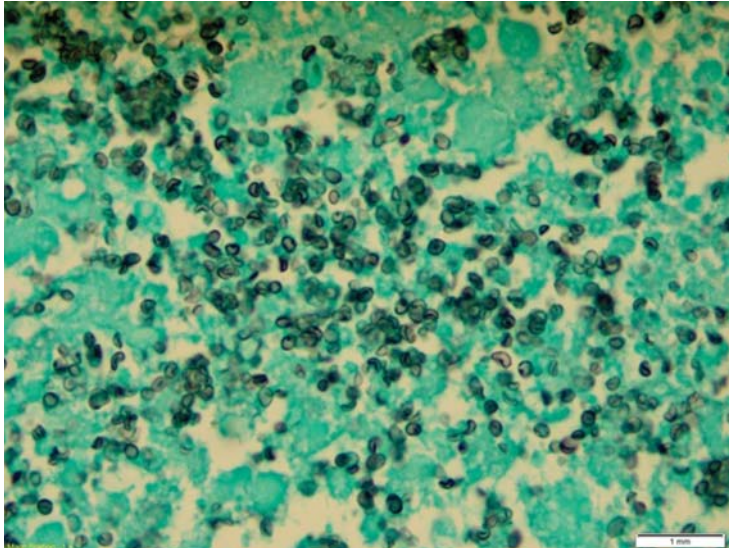


FIGURE 3. Grocott-Gomori methenamine silver staining of a biopsy specimen of a right frontal brain lesion showed budding yeast forms, consistent with *Histoplasma capsulatum* ($\times 100$).

tral nervous system, itraconazole can be given for more than 1 year or until immune recovery is achieved—or lifelong if necessary.^{2,12} Long-term suppressive antifungal therapy also should be considered in pa-

tients for whom appropriate initial therapy fails.²

Nephrotoxicity (acute kidney injury, hypokalemia, and hypomagnesemia), infusion-related drug reactions, and rash are among the well-described side effects of amphotericin B. Maintenance of intravascular volume and replacement of electrolytes should be an integral part of the amphotericin B treatment regimen.¹³

■ TAKE-AWAY POINTS

- Histoplasmosis should be considered in the differential diagnosis of ring-enhancing lesions of the central nervous system, along with toxoplasmosis and primary central nervous system lymphoma. This will allow timely initiation of the diagnostic workup, avoiding unnecessary and potentially risky interventions and delays in starting targeted antifungal therapy.
- There is no single gold standard test for central nervous system histoplasmosis. Rather, the final diagnosis is based on the combination of clinical, laboratory, and radiologic findings. ■

ACKNOWLEDGMENT: Library research assistance provided by HSHS St. John's Hospital Health Sciences Library staff.

■ REFERENCES

1. Shapiro JL, Lux JJ, Sproffkin BE. Histoplasmosis of the central nervous system. *Am J Pathol* 1955; 31:319–335.
2. Wheat LJ, Musial CE, Jenny-Avital E. Diagnosis and management of central nervous system histoplasmosis. *Clin Infect Dis* 2005; 40:844–852.
3. Wheat LJ, Batteiger BE, Sathapatayavongs B. *Histoplasma capsulatum* infections of the central nervous system: a clinical review. *Medicine (Baltimore)* 1990; 69:244–260.
4. Kauffman CA. Histoplasmosis: a clinical and laboratory update. *Clin Microbiol Rev* 2007; 20:115–132.
5. Modi M, Mochan A, Modi G. Management of HIV-associated focal brain lesions in developing countries. *QJM* 2004; 97:413–421.
6. Miller RF, Hall-Craggs MA, Costa DC, et al. Magnetic resonance imaging, thallium-201 SPET scanning, and laboratory analyses for discrimination of cerebral lymphoma and toxoplasmosis in AIDS. *Sex Transm Infect* 1998; 74:258–264.
7. Cohen WA. Intracranial bacterial infections in patients with AIDS. *Neuroimaging Clin N Am* 1997; 7:223–229.
8. Troncoso A, Fumagalli J, Shinzato R, Gulotta H, Toller M, Bava J. CNS cryptococcoma in an HIV-positive patient. *J Int Assoc Physicians AIDS Care (Chic)* 2002; 1:131–133.
9. Land AM, Nelson GA, Bell SG, Denby KJ, Estrada CA, Willett LL. Widening the differential for brain masses in human immunodeficiency virus-positive patients: syphilitic cerebral gummata. *Am J Med Sci* 2013; 346:253–255.
10. Balsys R, Janousek JE, Batnitzky S, Templeton AW. Peripheral enhancement in computerized cranial tomography: a non-specific finding. *Surg Neurol* 1979; 11:207–216.
11. Wheat LJ, Freifeld AG, Kleiman MB, et al; Infectious Diseases Society of America. Clinical practice guidelines for the management of patients with histoplasmosis: 2007 update by the Infectious Diseases Society of America. *Clin Infect Dis* 2007; 45:807–825.
12. Wheat J, Hafner R, Wulfsohn M, et al; National Institute of Allergy and Infectious Diseases Clinical Trials and Mycoses Study Group Collaborators. Prevention of relapse of histoplasmosis with itraconazole in patients with the acquired immunodeficiency syndrome. *Ann Intern Med* 1993; 118:610–616.
13. Saccante M. Central nervous system histoplasmosis. *Curr Treat Options Neurol* 2008; 10:161–167.

ADDRESS: Aram Barbaryan, MD, University of Kansas Medical Center, 3901 Rainbow Boulevard, Mail Stop 1020, Kansas City, KS 66160; abarbaryan@kumc.edu