

## THE CLINICAL PICTURE

### TAKESHI KONDO, MD

Department of General Medicine,  
Chiba University Hospital, Chiba, Japan

### YOSHIYUKI OHIRA, PhD

Department of General Medicine,  
Chiba University Hospital, Chiba, Japan

### TAKANORI UEHARA, PhD

Department of General Medicine,  
Chiba University Hospital, Chiba, Japan

### KAZUTAKA NODA, PhD

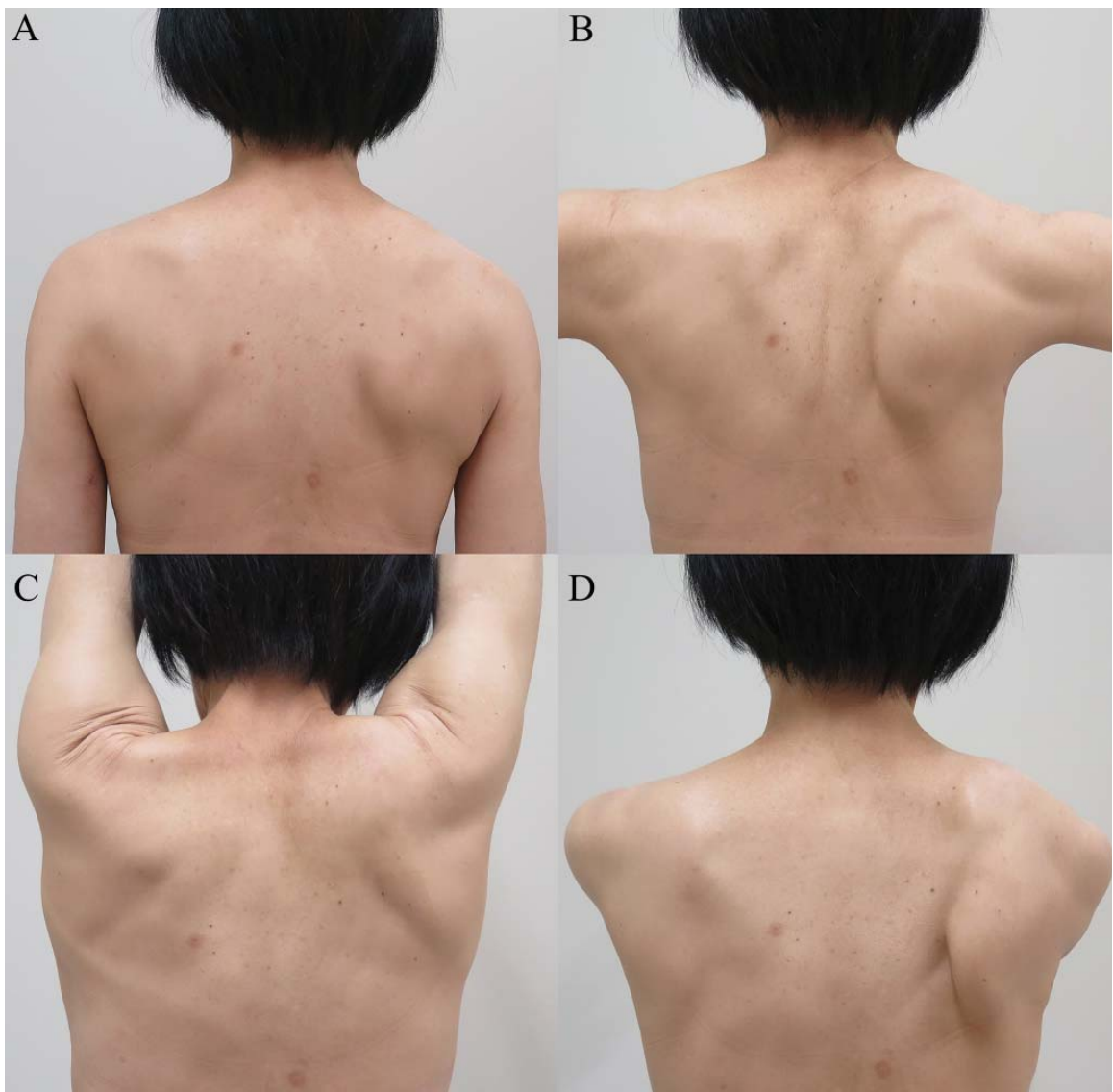
Department of General Medicine,  
Chiba University Hospital, Chiba, Japan

### MASATOMI IKUSAKA, PhD

Department of General Medicine,  
Chiba University Hospital, Chiba, Japan

# An unexpected cause of shoulder pain

The diagnosis is often delayed, as the presentation may mimic a joint or rotator cuff pathology



**FIGURE 1.** Scapular appearances at (A) 0 degrees of shoulder abduction, (B) 90 degrees of shoulder abduction, (C) 180 degrees of shoulder forward elevation, and (D) 90 degrees of shoulder forward flexion.

doi:10.3949/ccjm.84a.16051

**A** 58-YEAR-OLD WOMAN who sustained right-sided traumatic rib fractures after falling down stairs 8 months earlier presented with right shoulder pain that had been present for 6 months. She received nonsteroidal anti-inflammatory drugs at another hospital, which were partially effective. Magnetic resonance imaging of the neck and right shoulder had shown no abnormalities.

See related editorial, page 278

On physical examination, her right scapula was found to protrude abnormally (ie, to “wing”) during forward flexion and abduction of the right arm (**Figure 1**). Electromyography showed evidence of right serratus anterior paralysis and denervation of the right long thoracic nerve, leading to a diagnosis of traumatic long thoracic nerve paralysis. A course of physical therapy was initiated to improve her symptoms.

### LONG THORACIC NERVE PARALYSIS

Scapular winging is caused by dysfunction of any of the 3 main muscles that attach the scapula to the posterior thoracic wall—the serratus anterior, the trapezius, and the rhomboid. The problem is most often in the serratus anterior muscle, innervated by the long thoracic nerve, a pure motor nerve that originates from the

fifth, sixth, and seventh cervical nerves and descends along the lateral thoracic wall.

Long thoracic nerve paralysis can have traumatic, nontraumatic, or iatrogenic causes. Traumatic injuries result from blunt trauma to the neck, shoulder girdle, and thorax, while nontraumatic causes include viral illness, toxic exposure, apical pulmonary tumor, and C7 radiculopathy.<sup>1-3</sup> Iatrogenic injuries may be caused by mastectomy with axillary dissection, chest tube thoracostomy, first-rib resection, or scalenotomy, or occur after general anesthesia.<sup>1,2,4</sup>

Scapular winging due to paralysis of the serratus anterior muscle is accentuated by forward elevation and—particularly—by pushing against a wall, and the entire scapula is displaced more medially and superiorly.<sup>2</sup> The compensatory muscular activity required for shoulder stability induces secondary shoulder pain.<sup>5</sup>

The diagnosis is often delayed, as the clinical presentation may mimic the symptoms of shoulder joint or rotator cuff pathology. Although physical therapy resolves the pain and improves the function of the arm, mild endurance deficits and asymptomatic scapular winging may persist. Tendon transfer surgery is considered if adequate recovery is not achieved after a 6- to 24-month course of physical therapy.<sup>2</sup>

### REFERENCES

1. **Vastamäki M, Kauppila LI.** Etiologic factors in isolated paralysis of the serratus anterior muscle: a report of 197 cases. *J Shoulder Elbow Surg* 1993; 2:240–243.
2. **Martin RM, Fish DE.** Scapular winging: anatomical review, diagnosis, and treatments. *Curr Rev Musculoskelet Med* 2008; 1:1–11.
3. **Toshkezi G, Dejesus J, Jabre JF, Hohler A, Davies K.** Long thoracic neuropathy caused by an apical pulmonary tumor. *J Neurosurg* 2009; 110:754–757.
4. **Kauppila LI, Vastamäki M.** Iatrogenic serratus anterior paralysis. Long-term outcome in 26 patients. *Chest* 1996; 109:31–34.
5. **Nath RK, Lyons AB, Bietz G.** Microneurolysis and decompression of long thoracic nerve injury are effective in reversing scapular winging: long-term results in 50 cases. *BMC Musculoskelet Disord* 2007; 8:25.

**ADDRESS:** Takeshi Kondo, MD, Department of General Medicine, Chiba University Hospital, 1-8-1, Inohana, Chuo-ku, Chiba City, Chiba 260-8677, Japan; reds\_liverpool\_2005@yahoo.co.jp

## CME CREDIT TEST

Visit [WWW.CCJM.ORG](http://WWW.CCJM.ORG)  
Test your knowledge  
of clinical topics and earn  
AMA PRA Category 1 Credit™

