

# Social withdrawal and confusion in an inmate with schizoaffective disorder

Michele A. Andrade, MD



## How would you handle this case?

Answer the **challenge questions** throughout this article

Mr. J, age 54, has a history of schizoaffective disorder and violence, which led to his incarceration. Recently he's withdrawn socially and has an unsteady gait. What could be the cause?

### **CASE** Withdrawn and confused

Mr. J, age 54, is brought to the emergency department from a correctional treatment facility where he is reported to be displaying new, unusual behavior. He has a history of schizoaffective disorder, which has been stable with haloperidol, 10 mg/d, for more than a year.

Although previously Mr. J openly discussed his long-standing delusions about the FBI coming to release him from prison, he no longer mentions this or any other delusional beliefs, and has become less communicative with staff and peers. Mr. J no longer accompanies the other patients to the cafeteria for meals and eats in his room alone and appears to be losing weight. He says, "I do not feel good," but otherwise does not communicate spontaneously. Intermittently, he is irritable, without known triggers. The staff notices that Mr. J often lays on his bed, sometimes in a fetal position. Over time, he becomes confused and is seen attempting to open his room door with a toothbrush. His personal hygiene is poor, and he often urinates through his clothes, on the floor, and in his bed. Recently, Mr. J's eczema has worsened. His gait has become unsteady, and he has orthostasis.

### What could be causing these new symptoms?

- a) worsening schizoaffective disorder
- b) illicit drug use in the prison
- c) atypical dementia
- d) cardiac etiology

### The author's observations

The differential diagnosis for Mr. J appeared to be wide and without specific etiology. Because of the complex types of symptoms that Mr. J was experiencing, the emergency department managed his care and specialty clinic referrals were ordered.

It was reported that Mr. J started complaining of lightheadedness a few months ago, which worsened (unsteady gait, near falls). In the context of Mr. J's history of lightheadedness and orthostasis, the cardiology clinic ordered a tilt table test, which was within normal limits:

- 70° head-up tilt: blood pressure, 91/67 to 102/62 mm Hg, and pulse, 70 to 79 beats per minute (bpm)
- with isoproterenol, 1 µg/minute: blood pressure, 90/66 to 110/70 mm Hg, and pulse, 77 to 124 bpm
- with isoproterenol, 2 µg/minute: blood pressure, 98/58 to 111/66 mm Hg, and pulse, 121 to 134 bpm.

The neurologist's diagnostic impression was atypical dementia; however, Mr. J

Dr. Andrade is Staff Psychiatrist, Wisconsin Resource Center, Winnebago, Wisconsin, Consultant Psychiatrist, Wisconsin Department of Corrections, Madison, Wisconsin, and Assistant Clinical Professor, Medical College of Wisconsin, Milwaukee, Wisconsin.

### Disclosure

The author reports no financial relationship with any company whose products are mentioned in this article or with manufacturers of competing products.



Discuss this article at [www.facebook.com/CurrentPsychiatry](http://www.facebook.com/CurrentPsychiatry)



showed no memory deficits. Parkinsonism also was considered, but Mr. J had no unilateral tremor, masked facies, or micrographia. Mr. J showed some restriction in his movement, but he was not bradykinetic. The team suspected haloperidol could be causing his stiff movement.

Although it was possible that Mr. J's schizoaffective disorder was worsening and led to the new symptoms, Mr. J appeared to be less delusional because he was no longer talking to the staff about his delusions. There seemed to be no outward evidence of progression of psychotic symptoms.

Mr. J had a history of substance abuse, including alcohol, cocaine, and *Cannabis*. Although prison inmates have been known to manufacture and drink "hooch," the new symptoms Mr. J was experiencing were severe enough that his social interactions with other inmates diminished substantially. Because Mr. J had not been communicating with the other inmates and had no recent visitors, the team felt that it was unlikely that drugs were causing these symptoms. Also, a urine drug screen for cocaine, amphetamines, benzodiazepines, *Cannabis*, and opioids was negative.

### **HISTORY** Substance use, violence

Mr. J was diagnosed with bipolar disorder at age 18. After later hospitalizations, his diagnosis was changed to schizoaffective disorder as a matter of diagnostic clarification. He has a long history of non-compliance with treatment, homelessness, and drug abuse.

Mr. J is serving a 20-year sentence for first-degree reckless homicide. A year after he was incarcerated, Mr. J was sent to a specialized mental health facility for inmates whose illness cannot be managed in a typical correctional setting. While at the treatment facility, Mr. J was non-compliant with medications and because of concerns about dangerousness and psychosis, the court found probable cause for involuntary commitment.

His medication regimen is trihexyphenidyl, 2 mg/d, for extrapyramidal

symptoms; haloperidol, 10 mg/d, for psychosis; trazodone, 150 mg/d, for insomnia; vitamin D<sub>3</sub>, 2,000 IU/d; vitamin E, 400 IU/d, for symptoms of tardive dyskinesia; IM ziprasidone, 20 mg, because he refused oral haloperidol; and hydrocortisone cream 1% for eczema.

### **EVALUATION** Additional tests

Mr. J's blood pressure is 124/72 mm Hg, and pulse, 104 bpm, laying down; blood pressure, 110/84 mm Hg, and pulse, 112 bpm, sitting; and blood pressure, 108/82 mm Hg, and pulse, 129 bpm, standing. With repeated readings: blood pressure, 128/84 mm Hg, and pulse, 98 bpm, laying down; blood pressure, 125/86 mm Hg, and pulse, 113 bpm, sitting; and blood pressure, 105/76 mm Hg, and pulse, 130 bpm, standing.

Laboratory tests, including complete blood count, chemistry panel, thyroid-stimulating hormone, are within normal limits. The team feels that the investigation for an etiology for Mr. J's symptoms needs to be more exhaustive and additional tests are ordered, including vitamin levels (C, B<sub>1</sub>, B<sub>12</sub>, B<sub>6</sub>), rapid plasma reagin for syphilis, and arbovirus testing (eastern equine encephalitis virus, western equine encephalitis, West Nile virus, La Crosse encephalitis, St. Louis encephalitis), which are negative.

### **What's the next best step in managing Mr. J's care?**

- adjust his medication
- eliminate a medication
- order further testing

### **The author's observations**

To determine if Mr. J's new-onset symptoms might be related to the progression of his psychiatric illness, the haloperidol dosage was increased to 20 mg/d; however, we saw no positive response to this change. His tardive dyskinesia symptoms (bruxism and

### **Clinical Point**

**Mr. J started complaining about lightheadedness a few months before admission, which significantly worsened**

**Figure 1**

**24-Hour urine test results**

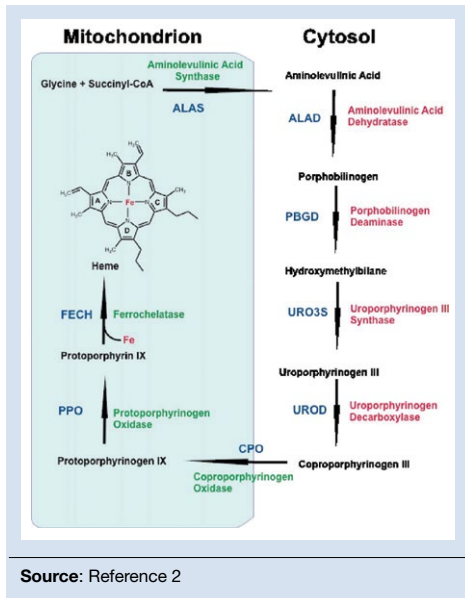
TESTS	RESULT	FLAG	UNITS	REFERENCE INTERVAL	LAB
<b>Porphyrins, Qa, 24 Hr Ur.</b>					
Uroporphyrins (UP)	4		ug/L	Undefined	01
Uroporph (UP), 24hr	11		ug/24 hr	0 - 24	
Heptacarboxyl (7-CP)	<1		ug/L	Undefined	01
Heptacarb (7-CP), 24hr	<3		ug/24 hr	0 - 4	
Hexacarboxyl (6-CP)	<1		ug/L	Undefined	01
<b>Hexacarb (6-CP), 24hr</b>	<b>&lt;3</b>	<b>High</b>	ug/24 hr	0 - 1	
Pentacarboxyl (5-CP)	<1		ug/L	Undefined	01
Pentacarb (5-CP), 24hr	<3		ug/24 hr	0 - 4	
Coproporphyrin (CP) I	16		ug/L	Undefined	01
<b>Coproporph (CP) I, 24hr</b>	<b>43</b>	<b>High</b>	ug/24 hr	0 - 24	
Coproporphyrin (CP) III	103		ug/L	Undefined	01
<b>Copropor (CP) III, 24hr</b>	<b>278</b>	<b>High</b>	ug/24 hr	0 - 74	

**Clinical Point**

The treatment team suspected that haloperidol could be causing Mr. J's stiff movement; however adjusting the dosage worsened symptoms

**Figure 2**

**Porphyrin cascade in forming heme**



other oral buccal movements) worsened. Haloperidol was reduced to 10 mg/d.

Trihexyphenidyl then was suspected to contribute to Mr. J's confusion. Unfortunately, lowering the dosage of trihexyphenidyl to 1 mg/d, did not affect Mr. J's current symptoms and exacerbated extrapyramidal symptoms.

The treatment team then questioned if porphyria—known as the “little imitator”—

might be considered because of the variety of symptoms without an etiology, despite extensive testing. A 24-hour urine collection was ordered.

**What is the correct method of collecting a urine sample for porphyrins?**

- collect a small sample and expose it to light before testing
- collect a 24-hour sample with the sample kept in ambient temperature and light
- collect a 24-hour sample with the sample kept on ice in a light-blocking container and frozen when sent to the laboratory

**EVALUATION Diagnosis revealed**

The 24-hour urine collection is obtained. However, it needed to be collected twice, because the first sample was not a full sample. Interestingly, the first sample, which is exposed to light and not kept on ice, turned dark in color. The second sample is obtained properly and sent to the laboratory. When the laboratory results are returned (**Figure 1**), Mr. J is diagnosed with hereditary coproporphria (HCP).

**The author's observations**

There are several types of porphyria, each associated with a different step in the chain

continued from page 50

of enzymes associated with synthesis of a heme molecule in the mitochondria. A defect in any single enzyme step will create a build up of porphyrins—a precursor to heme molecules—in erythrocytes or hepatic cells.

It is important to differentiate hepatic from erythropoietic porphyrias. The acute porphyrias (acute intermittent porphyria [AIP], HCP, and variegate porphyria) generally are hepatic in origin with neuropsychiatric and neurovisceral symptoms. Cutaneous porphyrias originate in bone marrow and therefore are erythropoietic. However, there are exceptions such as porphyria cutanea tarda (PCT), which is hepatic in origin but the manifestations mainly are cutaneous<sup>1</sup> (Figure 2, page 50).<sup>2</sup>

Although acute porphyria originates in the liver, it is a neuropsychiatric illness. In these cases, excess porphyrins cannot cross the blood–brain barrier and are neurotoxic.

Clinicians can look for abnormalities in the liver via liver function tests, but liver parenchyma is not damaged by these enzyme precursors. During an acute porphyric attack, patients could experience symptoms such as:

- muscle spasms (commonly abdominal, but can be any muscle group)
- confusion
- disorientation
- autonomic instability
- lightheadness
- disorientation
- diarrhea
- light sensitivity
- dermatologic conditions
- weakness (particularly peripheral weakness)
- hypesthesia
- allodynia
- severe nausea and vomiting
- emotional lability
- psychosis as well as general malaise.

The attack could result in death.

Mr. J had many differing symptoms and was evaluated by several specialty provid-

**Table**

### Factors that can trigger a porphyric attack

Inter-current illnesses
Chemical/environmental exposure
Alcohol use
Some medications, including: Antifungals Barbiturates Medications with sulphur moiety Some anesthetics Reproductive hormones
Certain foods, including: Vinegar Spinach Coffee Cilantro Rhubarb
Hand lotions/cream
Sun exposure
Pregnancy or postpartum status
Restrictive or low carbohydrate diets
<b>Source:</b> Reference 7,8

ers. He had a chronic dermatologic condition; he was confused, disoriented, and complained of nausea, weakness, orthostasis, and loose stools. With the variety of possible symptoms that patients such as Mr. J could experience, one can see why it would lead to many different providers being involved in the diagnosis. It is not uncommon for psychiatrists to be the last providers to care for such patients who could have been evaluated by hematology, cardiology, gastroenterology, dermatology, and/or neurology.

### Hereditary coproporphyria

The team considered hepatic porphyrias because of new-onset symptoms of mood lability, confusion, orthostasis, unsteady gait, weakness, dermatologic conditions on hands not responsive to treatment, and general malaise. Mr. J was diagnosed with HCP, a type of porphyria caused by a

### Clinical Point

Although acute porphyrias originate in the liver, it is a neuropsychiatric illness

## Clinical Point

Porphyrins cause the reddish-purple coloration of the urine sample

## Related Resources

- American Porphyria Foundation. [www.porphyrifoundation.com](http://www.porphyrifoundation.com).
- The Porphyrias Consortium. [www.rarediseasesnetwork.org/cms/porphyrias](http://www.rarediseasesnetwork.org/cms/porphyrias).

## Drug Brand Names

Chlorpromazine • Thorazine	Trazodone • Desyrel, Oleptro
Haloperidol • Haldol	Trihexyphenidyl • Artane
Isoproterenol • Isuprel	Ziprasidone • Geodon
Loxapine • Loxitane	

defect in coproporphyrinogen oxidase that leads to an accumulation of coproporphyrinogen III. This precursor, as are many porphyrin precursors, is neurotoxic, leading to neurovisceral or neuropsychiatric effects. Although in Mr. J's case the coproporphyrinogen III value from the 24-hour drug screen was only modestly elevated, it has been noted that levels of excreted porphyrins do not necessarily correlate with symptom severity.<sup>3</sup>

In the past, porphyria testing was performed using the Watson-Schwartz test, which used Ehrlich's reagent to precipitate porphyrins in a urine sample,<sup>4</sup> and was used as a "bedside" test. Interestingly, porphyrins—not the iron found in the heme molecule—are precipitated in this test and cause the reddish-purple coloration of the urine sample. When quantitative testing was developed, a 24-hour sample of urine—kept on ice and away from ambient light, later to be frozen when sent to the laboratory—became the standard tool for testing for porphyrins. Now DNA testing can be used to diagnose HCP.

## OUTCOME Symptoms resolve

Mr. J is started on loxapine, 20 mg at bedtime, and his symptoms resolve within 2 weeks. He maintains some baseline delusional ideation consistent with his history of schizoaffective disorder, but he is more social, his personal hygiene improves, he attends groups, eats in the cafeteria with his peers, and is no longer confused.

## The author's observations

In the 1950s, chlorpromazine was used to treat AIP.<sup>5</sup> Mr. J received loxapine, a mid-potency first-generation antipsychotic, although it has been this author's observation that high-potency first-generation antipsychotics are not effective for treating porphyria.

Other treatment modalities include phlebotomy, and more extreme treatments include liver transplantation for hepatic porphyrias or bone marrow transplantation for erythropoietic porphyrias. PCT can be treated with scheduled phlebotomy and/or medication. The mechanism by which treatment (whether dietary or avoidance of triggers) is thought to be based on negative feedback to a rate limiting step in the heme synthesis chain ( $\Delta$ amino levulinic acid). Method of action (and this author's observations with loxapine) is thought to be effective in part due to peripheral and neuromuscular blocking action.<sup>6</sup>

Another mainstay of porphyria treatment is avoiding triggers (*Table, page 55*).<sup>7,8</sup>

continued on page 58

## Bottom Line

Porphyrias are known as the "little imitator" because of the onset of various and, at times, seemingly unrelated symptoms. A patient could see a variety of specialists before, often as last resort, being referred to a psychiatrist. This type of history should prompt the consideration of porphyria as a part of the differential.

continued from page 56

It is unclear what could have triggered the development of HCP in Mr. J. It may be that this was genetic, but because of incomplete dominant inheritance, it is unknown but can be assumed. There was a large scale occurrence of iatrogenic porphyria (PCT) in Turkey<sup>3</sup> due to exposure to hexachlorobenzene in the wheat supply. Porphyrias usually are passed down in families. Due to incomplete penetrance of inheritance, many with an enzyme defect will not become symptomatic. Usually symptoms present post-puberty, and often, but not always, in the fourth decade of life. It is unknown when a potential trigger will cause the illness.

### Clinical Point

**Porphyrias usually are genetic and many patients will not develop symptoms until mid-life**

### References

1. NIH: National Human Genome Research Institute. Learning about porphyria. <https://www.genome.gov/19016728/learning-about-porphyrin/learning-about-porphyrin>. Accessed February 23, 2017.
2. Ajioka RS, Phillips JD, Kushner JP. Biosynthesis of heme in mammals. *Biochim Biophys Acta*. 2006;1763(7):723-736.
3. Peters HA, Gocmen A, Cripps DJ, et al. Epidemiology of hexachlorobenzene-induced porphyria in Turkey: clinical and laboratory follow-up after 25 years. *Arch Neurol*. 1982;39(12):744-749.
4. The Watsonschwartz test. *JAMA*. 1966;195(6):481.
5. Brunton L, Chabner BA, Knollman B. Goodman & Gilman's the pharmacological basis of therapeutics. 12th ed. New York, NY: McGraw-Hill Professional; 2010.
6. Broomfield B. Acute Intermittent porphyria treated with chlorpromazine. *Proc R Soc Med*. 1962;55(9):799-800.
7. Hunter JA, Khan SA, Hope E, et al. Hereditary coproporphyrin. Photosensitivity, jaundice and neuropsychiatric manifestations associated with pregnancy. *Br J Dermatol*. 1971;84(4):301-310.
8. Bonkovsky HL, Maddukuri V. Merck Manual. <http://www.merckmanuals.com/professional/endocrine-and-metabolic-disorders/porphyrias/overview-of-porphyrin>. Accessed February 2, 2017.