

Ultrasound-Guided Femoral Nerve Block

Sierra Beck, MD; Todd Taylor, MD; Jehangir Meer, MD

A step-by-step, easy-to-learn alternative to blind anesthetic injection or procedural sedation.

Case Scenario

A young man presented to the ED for evaluation of a large laceration to the anterior thigh that resulted from an industrial accident (**Figure 1**). As an emergency physician, you can easily imagine the length of time and the large volume of anesthetic required to ensure a painless repair of this patient's laceration using local infiltration alone. While procedural sedation is certainly an option,

it can be a significant drain on nursing and physician time and resources. There is, however, an alternative that is both easy to learn and perform. Instead of procedural sedation, the patient in this case underwent a painless repair via an ultrasound-guided femoral nerve block.

Femoral nerve blocks are useful in a variety of clinical scenarios, including fractures of the femur or hip¹ and laceration repairs (**Figure 2**). Although a fascia

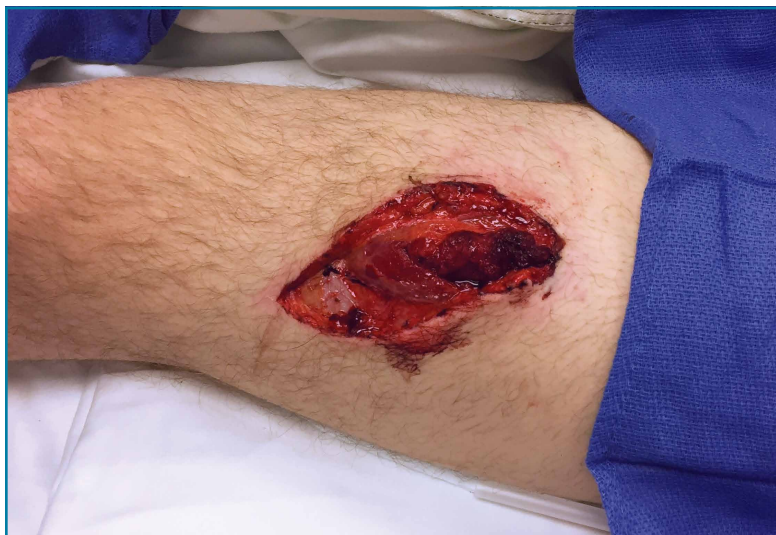

Figure 1. Photo of the laceration to the patient's anterior thigh.

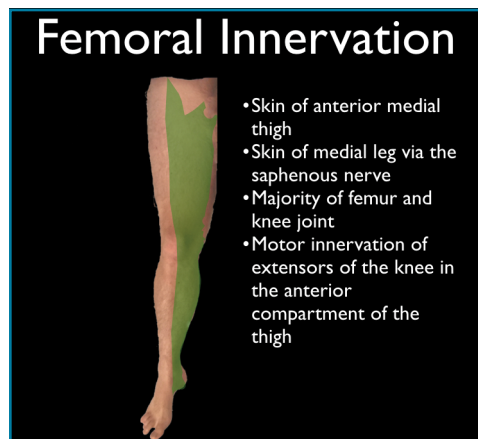


Figure 2. Illustration detailing femoral innervation.

Dr Beck is an assistant professor, department of emergency medicine, Emory University School of Medicine, Atlanta, Georgia. **Dr Taylor** is an assistant professor and director of postgraduate medical education, department of emergency medicine, Emory University School of Medicine, Atlanta, Georgia. **Dr Meer** is an assistant professor and director of emergency ultrasound, department of emergency medicine, Emory University School of Medicine, Atlanta, Georgia.

Authors' Disclosure Statement: The authors report no actual or potential conflict of interest in relation to this article.

DOI: 10.12788/emed.2016.0065

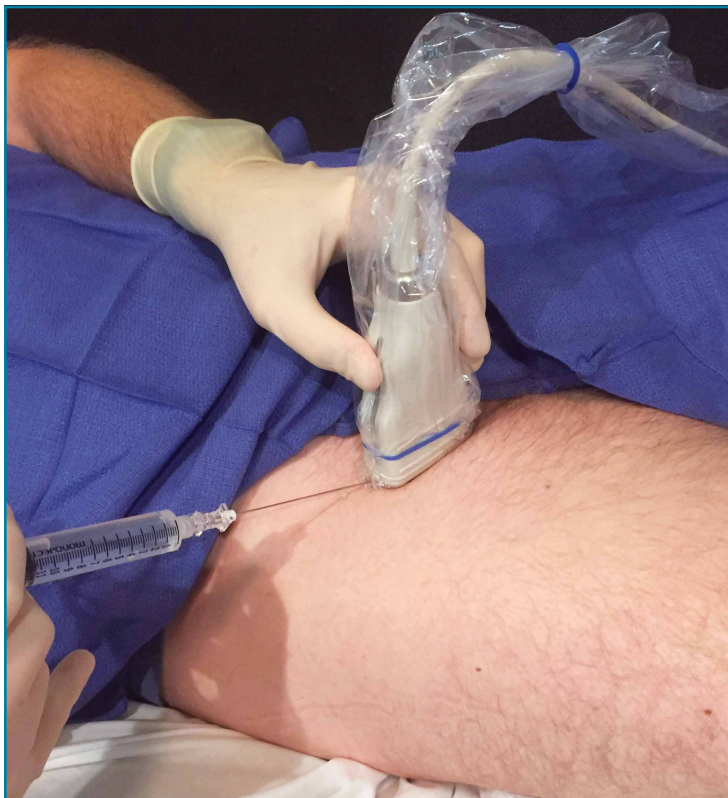

Figure 3. Photo demonstrating the correct probe position over the femoral crease for visualization of the femoral nerve.

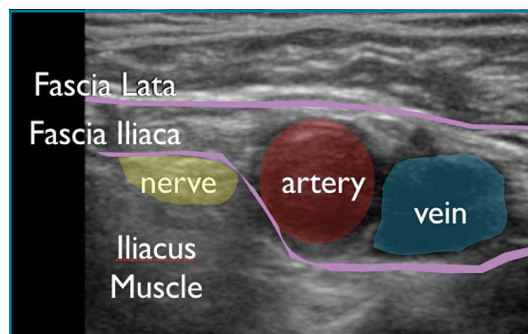


Figure 4. Ultrasound image of the femoral nerve, identified by its flat, hyperechoic, honeycomb appearance in short axis overlying the iliacus muscle adjacent to the femoral artery.

iliaca block can be performed blind, ultrasound guidance can improve the success of the procedure.

Identifying the Femoral Nerve on Ultrasound

To perform this nerve block, one must recall the anatomy of femoral central-line placement. The femoral nerve lies lateral to the femoral artery and vein. The high-frequency probe should be placed over the femoral crease (**Figure 3**). The femoral nerve can be identified by its flat, hyperechoic, honeycomb appearance in short axis overlying the iliacus muscle adjacent to the femoral artery (**Figure 4**). It is sometimes difficult to distinguish the femoral nerve from the surrounding fat and fascial planes. Fanning the probe back and forth toward the patient's head and feet may make the nerve appear brighter and increase visualization.

Performing the Block

An ultrasound-guided femoral nerve block can be performed using a 22-gauge blunt tip spinal needle,

and an in-plane or out-of-plane technique can be employed. We prefer using an in-plane technique because the entire shaft of the needle can be visualized as it approaches the nerve. Anatomically, the femoral nerve lies in a separate fascial plane from the artery and vein, beneath the fascia iliaca (**Figure 4**). You can use this anatomic location of the femoral nerve to your advantage when performing the block. The needle can be advanced to a target slightly lateral to the nerve until it pops beneath the fascia iliaca. On the ultrasound, you can monitor the spread of anesthetic as it is injected. If the needle is in the right location, the hypoechoic fluid will spread medially toward the nerve, but will not track around the artery or vein. At least 15 cc to 20 cc of local anesthetic is typically required.^{2,3} If you prefer, the anesthetic can be diluted in normal saline, in a 1:1 ratio, to achieve adequate volume.

If you do not see the anesthetic spread during the injection, you should stop and check the needle placement, as it may be intravascular. Using a more lateral approach, targeting the injection at the fascial plane,

rather than the nerve, helps to avoid direct intraneural injection or contact with the nerve—and it keeps the needle far away from the femoral vascular bundle.

Safety Considerations

As with any technique, prior to the procedure, aseptic measures should be taken, including the use of a sterile probe cover and sterile gloves. All patients undergoing ultrasound-guided nerve blocks proximal to the wrist or ankle should be placed on a cardiac monitor. In addition, intralipid emulsion should be readily available for administration in the unlikely event there is inadvertent intravascular injection of local anesthetic and cardiovascular collapse occurs.

Summary

With practice, ultrasound guidance can improve the procedural success of femoral nerve blocks and decrease the risk of nerve injury compared to blind nerve blocks

References

1. Dickman E, Pushkar I, Likourezos A, et al. Ultrasound-guided nerve blocks for intracapsular and extracapsular hip fractures. *Am J Emerg Med.* 2016;34(3):586-589.
2. Femoral nerve block. In: Hadzic A, Carrera A, Clark T, et al, eds. *Hadzic's Peripheral Nerve Blocks: An Anatomy for Ultrasound-Guided Regional Anesthesia.* 2nd ed. New York, NY: The McGraw Hill Companies, Inc; 2012:267-279.
3. Ultrasound-guided femoral nerve block. In: Hadzic A, Carrera A, Clark T, et al, eds. *Hadzic's Peripheral Nerve Blocks: An Anatomy for Ultrasound-Guided Regional Anesthesia.* 2nd ed. New York, NY: The McGraw Hill Companies, Inc; 2012:397-404.



HCV HUB

**Bringing you the latest
hepatitis C virus news.**

Look to **HCV Hub** for
cutting-edge news from
medical meetings, the FDA, and
medical specialty journals.

www.HCVhub.com