



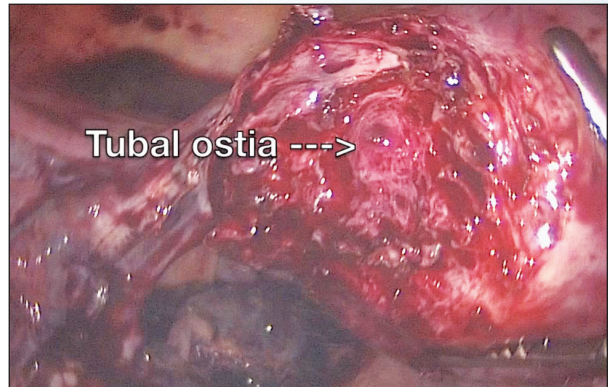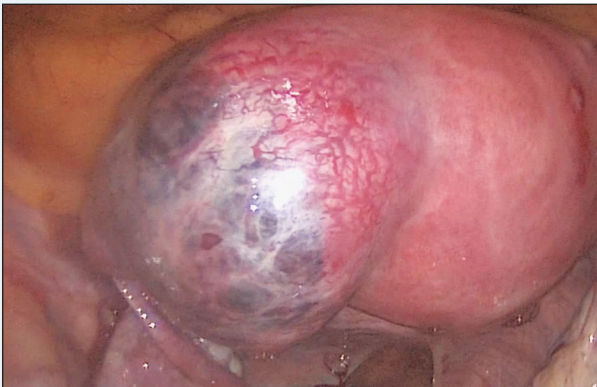Dr. Arnold P. Advincula's

VIDEO CHANNEL 

Laparoscopic management of interstitial ectopic pregnancy

An overview of surgical techniques illustrated by a case of laparoscopic cornual resection

Mireille D. Truong, MD, and Johanna (Jana) K. Halfon, MD




Interstitial ectopic pregnancies, commonly reported as “cornual” ectopic pregnancies, are rare, accounting for only 2% to 3% of all tubal ectopic pregnancies. They can be managed medically with methotrexate or surgically via laparotomy or laparoscopy. Many variations of laparoscopic techniques have been described in the literature but no standardized surgical management has been established.

In this video, we begin by reviewing interstitial ectopic pregnancy and surgical approaches to treatment,

with a focus on key surgical techniques and steps for successful laparoscopic management.

We then present the case of a 40-year-old woman (G3P1011) at 7 weeks 2 days gestation with a 5-cm left interstitial ectopic pregnancy who underwent a laparoscopic cornual resection.

We hope this video can serve as a quick reference in your practice for the surgical management of interstitial ectopic pregnancies. 


Dr. Truong is Fellow in Minimally Invasive Gynecologic Surgery, Columbia University Medical Center, New York, New York.

Dr. Halfon is Graduated Resident, Department of Obstetrics & Gynecology, Columbia University Medical Center, New York, New York.

Dr. Advincula is the Levine Family Professor of Women's Health and Vice-Chair, Department of Obstetrics & Gynecology and Chief of Gynecology, Sloane Hospital for Women at Columbia University Medical Center in New York, New York. He serves on the OBG MANAGEMENT Board of Editors.

Dr. Advincula reports being a consultant to Blue Endo, CooperSurgical, Intuitive Surgical, SurgiQuest, Titan Medical, and receiving royalties from CooperSurgical. The other authors report no financial relationships relevant to this article.

To view the video

Visit Dr. Arnold P. Advincula's Surgical Techniques Video Channel in the Video Library at obgmanagement.com or use the QR code at right 



Watch for this video coming soon:

Managing complicated ectopic pregnancy presentations, Part 2: Cesarean section scar ectopic pregnancy