

CUTANEOUS
MEDICINE
FOR THE
PRACTITIONER

VOL. 80 NO. 6S

DECEMBER 2007

A SUPPLEMENT TO

cutis®

NATURAL ADVANCES IN ECZEMA CARE



A SUPPLEMENT TO
cutis[®]

CUTANEOUS MEDICINE
FOR THE PRACTITIONER
VOL. 80 NO. 6S

DECEMBER 2007

Cutis[®] Cutaneous Medicine for the Practitioner, December 2007,
Volume 80 Number 6S

TRADEMARK: *Cutis*[®] is a registered trademark of Quadrant
HealthCom Inc.

PUBLISHER: *Cutis*[®] (ISSN-0011-4162) (GST #128741063) is pub-
lished monthly by Quadrant HealthCom Inc., with business offices at
7 Century Dr, Suite 302, Parsippany, NJ 07054-4609; telephone
973-206-3434; fax 973-206-9378.

COPYRIGHT: Copyright Quadrant HealthCom Inc. 2007. All
rights reserved. No part of this publication may be reproduced,
stored in a retrieval system, or transmitted in any form or by
any means, mechanical, computer, photocopying, electronic
recording, or otherwise, without the prior written permission of
Quadrant HealthCom Inc. The copyright law of the United States
(Title 17, U.S.C., as amended) governs the making of photocopies
or other reproductions of copyrighted material.

PHOTOCOPY PERMISSIONS POLICY: This publication has
been registered with Copyright Clearance Center, Inc (CCC),
222 Rosewood Dr, Danvers, MA 01923, telephone 508-750-8400.
Permission is granted for the photocopying of specified articles
provided that the base fee is paid directly to CCC (ref. *Cutis*[®], ISSN-
0011-4162, specifying volume, date, and title of article). This con-
sent does not extend to other kinds of copying, such as for general
distribution, resale, advertising, and promotional purposes, or for
creating new collective works.

OPINIONS: Opinions expressed in articles are those of the authors
and do not necessarily reflect those of Quadrant HealthCom Inc. or
the Editorial Board. Quadrant HealthCom Inc. assumes no liability for
any material published herein.

REPRINTS: Contact Shannon C. Conover at 973-206-8015; fax 973-
206-9256.

PAID SUBSCRIPTIONS: All prices listed are for one-year subscription.
Individual, USA, \$146; Individual, Canada/Mexico, \$227; Individual,
all other nations, \$271 surface, \$350 air; Student/Resident, USA, \$40;
Institution, USA, \$218; Institution, Canada/Mexico \$284; Institution, all
other nations, \$345. For single issues: USA, \$21; Canada/Mexico, \$26;
all other nations, \$31.

BACK ISSUES: For back issues (subject to availability), call
800-480-4851 to charge your credit card. Written requests will be
accepted and must be accompanied by a check or money order.
Send payment and request to *Cutis*[®], Circulation Subscription
Service, 151 Fairchild Ave, Suite 2, Plainview, NY 11803-9758.
Claims for free replacement of missing copies of *Cutis*[®] must be
made within 3 months of the date of the missing issue requested.
Otherwise, the cost of replacement is \$26 per copy, USA; \$31,
Canada/Mexico; \$36, all other nations.

**FREE SUBSCRIPTIONS, CHANGE OF ADDRESS (FREE OR PAID
SUBSCRIPTIONS), OR PROFESSIONAL INFORMATION:** If you
change your professional address, specialty, or affiliation, please
call 800-480-4851, Subscription Service, 151 Fairchild Ave, Suite 2,
Plainview, NY 11803-9758; or e-mail quadrantcut@emscirc.com.

POSTMASTER: Send address changes to:
Cutis[®], Subscription Service, 151 Fairchild Ave,
Suite 2, Plainview, NY 11803-9758. Periodicals
postage paid at Parsippany, New Jersey, and at
additional mailing offices.



EDITOR	Melissa Steiger 973-206-8096
MANAGING EDITOR	Laura A. Piserchia 973-206-8098
ASSISTANT EDITOR	Stephanie Andersen 973-206-8097
PROOFREADER	Michele V. Murray
SENIOR DESIGNER	Thomas La Velle 973-206-9069
CREATIVE DIRECTOR	Mary Ellen Niatas 973-206-8973
PRODUCTION MANAGER	Jaime Serra 973-206-8011
CORPORATE CIRCULATION DIRECTOR	Donna Sickles
SUBSCRIPTION SERVICE	800-480-4851
DIRECTOR, MARKETING RESEARCH	Lori Raskin 973-206-8013
SENIOR VICE PRESIDENT/ GROUP PUBLISHER	Sharon Finch 973-206-8952
PUBLISHING CONSULTANT	Claudia Shayne- Ferguson 914-522-3188
REGIONAL SALES MANAGER	Richard D. O'Donnell 847-832-1512
PROGRAM MANAGER	Shannon C. Conover 973-206-8015
ADVERTISING/BILLING COORDINATOR	Kathleen Corbett 973-206-8022 Fax 973-206-9378
REPRINT INQUIRIES	Shannon C. Conover 973-206-8015 Fax 973-206-9256

PRESIDENT AND CEO
Stephen Stoneburn



Natural Advances in Eczema Care

Lawrence F. Eichenfield, MD; Joseph F. Fowler, Jr, MD; Darrell S. Rigel, MD; Susan C. Taylor, MD

Atopic dermatitis (AD) is a chronic relapsing dermatitis characterized by increased transepidermal water loss (TEWL) and subjective symptoms of pruritus, inflammation, skin sensitivity, and dryness. AD is a frequent issue for individuals of color, though it may be underrecognized. Therapy for AD is based on reducing pruritus and inflammation, and normalizing skin surface lipids, particularly ceramides. Topical corticosteroids are the gold-standard treatment for controlling disease flares, but a variety of active natural ingredients can be used adjunctively to help control itch, inflammation, and dryness. Oatmeal, particularly avenanthramides, a newly discovered oat fraction, may be of particular value in restoring the cutaneous barrier and reducing symptoms of AD. Feverfew, licorice, and dexpanthenol also have been shown to be effective in the management of inflammation. Licorice, which has some skin-lightening activity, may be helpful in patients with postinflammatory hyperpigmentation (PIH).

The compromised skin barrier in AD is especially vulnerable to UV radiation exposure. Several new long-lasting photostable sunscreen ingredients provide longer durations of protection with improved cosmetic attributes.

Cutis. 2007;80(suppl 6):2-16.

Atopic dermatitis (AD) is a chronic relapsing dermatitis that typically develops in infancy or early childhood. It is characterized by pruritus that is usually accompanied by scratching, erythema, crusting, and scaling. AD can have a variable course, with flares and quiescent periods in some individuals, and persistent unrelenting disease in others.

The prevalence of AD has steadily increased over the past 4 decades, with a threefold to fivefold increase in incidence since 1960.¹ According to the National Institutes of Health,² an estimated 20% of children in the first few years of life are affected by AD, with 65% of patients developing symptoms during the first year of life. Many cases of AD may remit or become subclinical in adulthood. The most recent prevalence data are based on the responses to questionnaires sent to a sample of 60,000 US households. Of the total questionnaires sent, 42,249 households (70%) responded, representing 116,202 individuals. Approximately 17% of the population studied had at least 1 of 4 symptoms of eczema.³ Empirically defined eczema^{4,5} was found in 11% of the total population and empirically defined AD in 6%.³ Therefore, it is estimated that 31.6 million and 17.8 million individuals in the United States would meet the empirical symptom criteria for eczema and AD, respectively.³ The prevalence of empirically defined eczema and AD combined was 17% among white individuals, 16% among African Americans/black individuals, and 21% among Asians and Pacific Islanders. Skin symptoms were moderate to severe in approximately two thirds of individuals with an empirical diagnosis of eczema or AD and sleep was disturbed in one third. Underdiagnosis was widespread; of respondents reporting symptoms in the previous

Dr. Eichenfield is from Rady Children's Hospital-San Diego, California, and the University of California, San Diego School of Medicine. Dr. Fowler is from the Department of Medicine, University of Louisville, Kentucky. Dr. Rigel is from New York University Medical Center, New York. Dr. Taylor is from St. Luke's-Roosevelt Hospital Center, New York, and Columbia University, New York.

Dr. Eichenfield is an investigator for and has received grants and research support from Allergan, Inc; Amgen Inc; Astellas Pharma Inc; Barrier Therapeutics, Inc; Ceragenix Pharmaceuticals, Inc; Dermik Laboratories; Dow Pharmaceutical Sciences, Inc; Galderma Laboratories, LP; GlaxoSmithKline; Graceway Pharmaceuticals, LLC; Hill Dermaceuticals, Inc; Johnson & Johnson Consumer Products, Inc; Novartis Pharmaceuticals Corporation; OrthoNeutrogena; RegeneRX; and Stiefel Laboratories, Inc. He also is an advisory board member and consultant for Astellas Pharma Inc; Graceway Pharmaceuticals, LLC; Medicis Pharmaceutical Corporation; Novartis Pharmaceuticals Corporation; Obagi Medical Products, Inc; SkinMedica; and Stiefel Laboratories, Inc. Dr. Fowler is consultant, researcher, and speaker for Johnson & Johnson Consumer Products, Inc. Dr. Rigel is an advisory board member and consultant for Johnson & Johnson Consumer Products, Inc, and Neutrogena Corporation. Dr. Taylor is an advisory board member, researcher, and speaker for Johnson & Johnson Consumer Products, Inc.

year, approximately 37% had received a physician's diagnosis of an eczematous condition.³

AD substantially impacts both the individual affected and the entire family.⁶ The physical symptoms of the disease may have substantial adverse psychosocial effects, including withdrawal, anxiety, poor self-esteem, and reduced ability to function at work or school. Sleep disturbances due to itching can substantially disturb well-being. In one study, AD's impact on quality of life was equivalent to that of renal disease and exceeded the impact of cystic fibrosis, seizures, and diabetes mellitus on quality of life.⁷ In a study by Absolon and colleagues,⁸ the rates of psychologic disturbances in the eczema cohort were similar to those in patients with epilepsy and leukemia.

DIAGNOSIS AND PATHOGENESIS

Diagnosis of AD is based on history and clinical morphology. The classic diagnostic criteria are those of Hanifin and Rajka⁴ and include pruritus, typical morphology and skin distribution, chronicity or a relapsing course, and a family history of allergy/atopy. Young children may present with facial dermatitis and extensor involvement but usually will exhibit the more typical flexural dermatitis within the first year of life.⁹

Concepts of AD pathogenesis are evolving. AD is the result of a "complex interplay of immune, genetic, metabolic, infectious, and neuroendocrine factors and their interaction with the environment."⁶ The scope of this discussion permits only a cursory overview of these factors. Immune dysregulation in the development of AD skin lesions is only partially understood. Abnormal inflammatory cells, including Langerhans cells and inflammatory dendritic epidermal cells, are highly responsive to antigens and mediate excessive T-cell activation responses.⁶ The development of AD lesions also is mediated by local tissue expression of proinflammatory cytokines such as tumor necrosis factor α (TNF- α) and interleukin (IL) 1 from keratinocytes, mast cells, and dendritic cells.⁹ Neural mediators, including α -melanocyte-stimulating hormone, substance P, and neurokinin A, may interact with various immune system cells and also modulate itch.⁶ The skin of patients with AD is colonized by *Staphylococcus aureus* in approximately 90% of cases.¹⁰ Increased immunoglobulin E (IgE) synthesis also may play a role in pathogenesis, though increases in total IgE are inconsistent with elevated absolute IgE levels and occur only in 70% to 80% of patients with AD.¹¹ The epidermis also appears to be

an important immunologic organ and the location of much innate immune activity.¹² The classic histopathologic sign of spongiosis seen in biopsy results of AD skin represents cellular apoptosis edema developing between cells and correlates with clinical signs of weeping, vesicles, and bullae.

EPIDERMAL BARRIER ABNORMALITIES IN AD

The epidermal barrier is abnormal in AD in both lesional and nonlesional, or dry atopic, skin. These abnormalities include increased transepidermal water loss (TEWL) and abnormal lipid metabolism, particularly of ceramides.¹³ One explanation for barrier dysfunction in some atopic individuals may be increased activity of proteases such as stratum corneum (SC) chymotryptic enzymes.¹⁴ Increased protease activity may result from serine protease inhibitor defects and genetic structural mutations.¹¹

Several mutations in the gene that encodes filaggrin (FLG) were found to cause ichthyosis vulgaris, which also appeared to be strongly correlated with AD. FLG is the major protein of keratohyalin granules in the epidermis. A study by Seguchi et al¹⁵ in 1996 demonstrated that FLG levels were decreased, even in nonlesional AD skin. Because of the large number of families with ichthyosis vulgaris and AD comorbidity, an association study was conducted to determine whether the FLG mutation increased AD risk.¹⁶ The association turned out to be highly significant ($P=5.4 \times 10^{-6}$). It also was noted that subjects with AD and the FLG mutation tended to have high serum IgE levels and positive allergy test results or clinical allergies. The FLG mutation also may predict a more severe course in individuals with chronic AD.¹⁶

In one study of subjects with AD, TEWL was increased in both dry atopic and clinically healthy skin but was higher in dry atopic areas. It was suggested that changes in the architecture or composition of the SC may increase water flux across the skin and thus account for the abnormal barrier function in both dry atopic and clinically healthy skin in subjects with AD.¹⁷

Imokawa and colleagues¹⁸ found marked reductions in SC ceramides in lesional forearm skin in subjects with AD compared with skin from age-matched healthy controls. Nonlesional skin of subjects with AD also exhibited significant decreases in ceramide levels ($P<.01$).¹⁸ In addition, sphingomyelin hydrolysis was highest in involved atopic skin but also was 6 times higher in nonlesional skin compared with the skin of

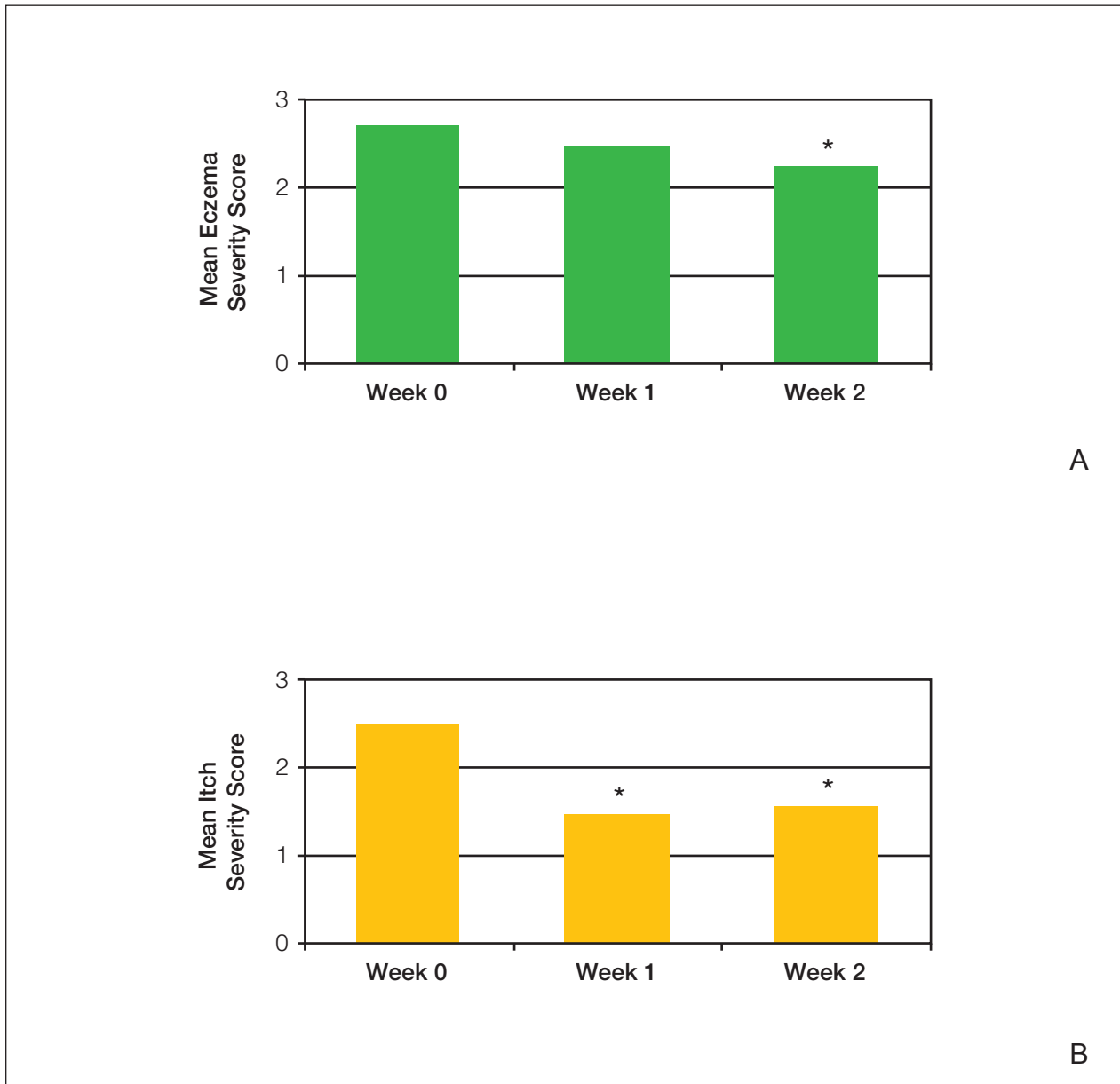


Figure 1. Dermatologist assessments (based on a 5-point scale [0=none, 1=slight, 2=mild, 3=moderate, 4=severe]) of eczema (A) and itch severity (B) after treatment with an oatmeal-based skin care regimen. Asterisk indicates $P < .05$ versus baseline. Adapted with permission from Nebus et al.³⁶

healthy controls as well as that of subjects with contact dermatitis and nonatopic chronic eczema. High levels of the epidermal enzyme sphingomyelin deacylase were found in the SC of subjects with AD and appeared to be associated with the ceramide deficiency.¹³ In a study by Di Nardo et al,¹⁹ subjects with AD who had no active signs of the disease had normal skin barrier function as evidenced by TEWL and had intermediate levels of ceramides and cholesterol compared with subjects with active AD and healthy controls. TEWL

was correlated specifically with the quantity of ceramide 3 and was greater in subjects with active eczema. In addition, the ceramide-cholesterol ratio was decreased in the skin of atopic subjects.¹⁹ Sator et al²⁰ found a decrease in both skin surface lipids and water content of dry atopic skin from several anatomical locations, which they summarized under the finding of “hydro lipid film of the skin.”

A defective skin barrier in AD may permit the entry of environmental irritants and allergens,

which can stimulate the release of cytokines and lead to dermal inflammation and the signs and symptoms of AD. TEWL that arises from the defective barrier also can stimulate cytokine release and initiate the inflammatory cascade.^{9,21,22} The extreme dryness associated with barrier impairment results in increased scratching and excoriations and thus further barrier damage, possibly increasing antigen absorption and cutaneous hyperreactivity.⁹

TREATMENT OF AD

The main treatment goals in eczema are to heal and normalize barrier function, decrease inflammation and itching, and prevent flares. Induction therapy is targeted at controlling flared eczematous skin. Topical corticosteroids are the traditional first-line therapies for disease flares. As noted in a consensus conference on pediatric AD, "when selected and used appropriately, these agents are not associated with significant adverse effects."⁶ Recently, several topical agents have been made available for prescription use through US Food and Drug Administration 510(k) filings. These agents can be useful steroid-sparing or topical calcineurin-sparing treatment alternatives, improving AD signs and symptoms and skin barrier function. Calcineurin inhibitors are useful alternatives to topical corticosteroids for skin inflammation, particularly in atrophy-prone areas and for intermittent chronic use. They are labeled for use in patients aged 2 years and older. Although theoretical safety concerns have been raised, data showing distinct systemic toxicity in humans have not been reported.²³

Bathing can hydrate and debride atopic skin and thus control symptoms. It should be followed by application of topical medication and an emollient, or an emollient only.⁶ Emollients occlude the skin surface and increase SC water content, which improves its biomechanical properties and thus increases elasticity and reduces the risk of cracking and further barrier disruption. Emollients also may be antipruritic and anti-inflammatory and may decrease the need for topical prescriptives.²¹

Special Concerns in Skin of Color

The prevalence of AD in skin of color is controversial. A study of 400 patients at a general dermatology practice found that 47 of 63 (75%) black subjects had never been diagnosed with AD, eczema, or contact dermatitis. However, when questioned about breakouts, dryness, or itching after using fragranced skin care products, 43 subjects (68%) stated that they had experienced these symptoms, suggesting an impaired barrier and

substantial irritation (L. Baumann, MD; unpublished data; 2005). Practice survey data based on 2000 black patients randomly selected from several private dermatology practices at Howard University Hospital in Washington, DC, found that eczema/AD was the most common dermatosis in black patients, with an incidence of 20.3%.²⁴ A similar incidence was found among Latino patients at both a private dermatology practice and a hospital-based clinic.²⁵

Special concerns confront clinicians when treating individuals of color. Findings regarding differences in skin sensitivity are conflicting. In early studies, erythema was used as an index of skin sensitivity. However, erythema is difficult to detect in skin of color because of its greater melanin content. Equating skin redness with irritation may have led to the erroneous conclusion that skin with more pigmentation is not irritated easily. However, it has been noted that "moderate to dark pigmented skin is as easily irritated as Caucasian skin."²⁶ The development of diffuse reflectance spectroscopy and other objective measures has greatly facilitated the differentiation of vascular and pigmentary reactions and thus research into sensitivity and irritation in more deeply melanized skin.²⁷

Ethnic skin frequently reacts to cutaneous damage, strong topical agents, or inflammation by developing postinflammatory hyperpigmentation (PIH) or uneven skin tone²⁸ because melanocytes in black skin produce larger quantities of melanin and show an exaggerated response to skin damage.²⁹ Thus, although all patients with AD require gentle barrier-enhancing treatments, these treatments are especially necessary in patients with skin of color.

Active Natural Ingredients in the Management of AD

Active natural ingredients may be useful adjuncts in the management of eczematous conditions, particularly with regard to repairing and protecting the compromised epidermal barrier. They are effective in decreasing inflammation and erythema as well as in helping to treat hyperpigmentation.

Oatmeal—Oatmeal is one of few natural ingredients to be regulated by the US Food and Drug Administration, which has determined that colloidal oatmeal is a skin protectant that provides temporary skin protection and relieves minor itching and irritation caused by eczema, rashes, poison ivy, and other contact allergens, as well as insect bites.³⁰

Colloidal oatmeal is composed of proteins, lipids, and polysaccharides. The skin-protectant

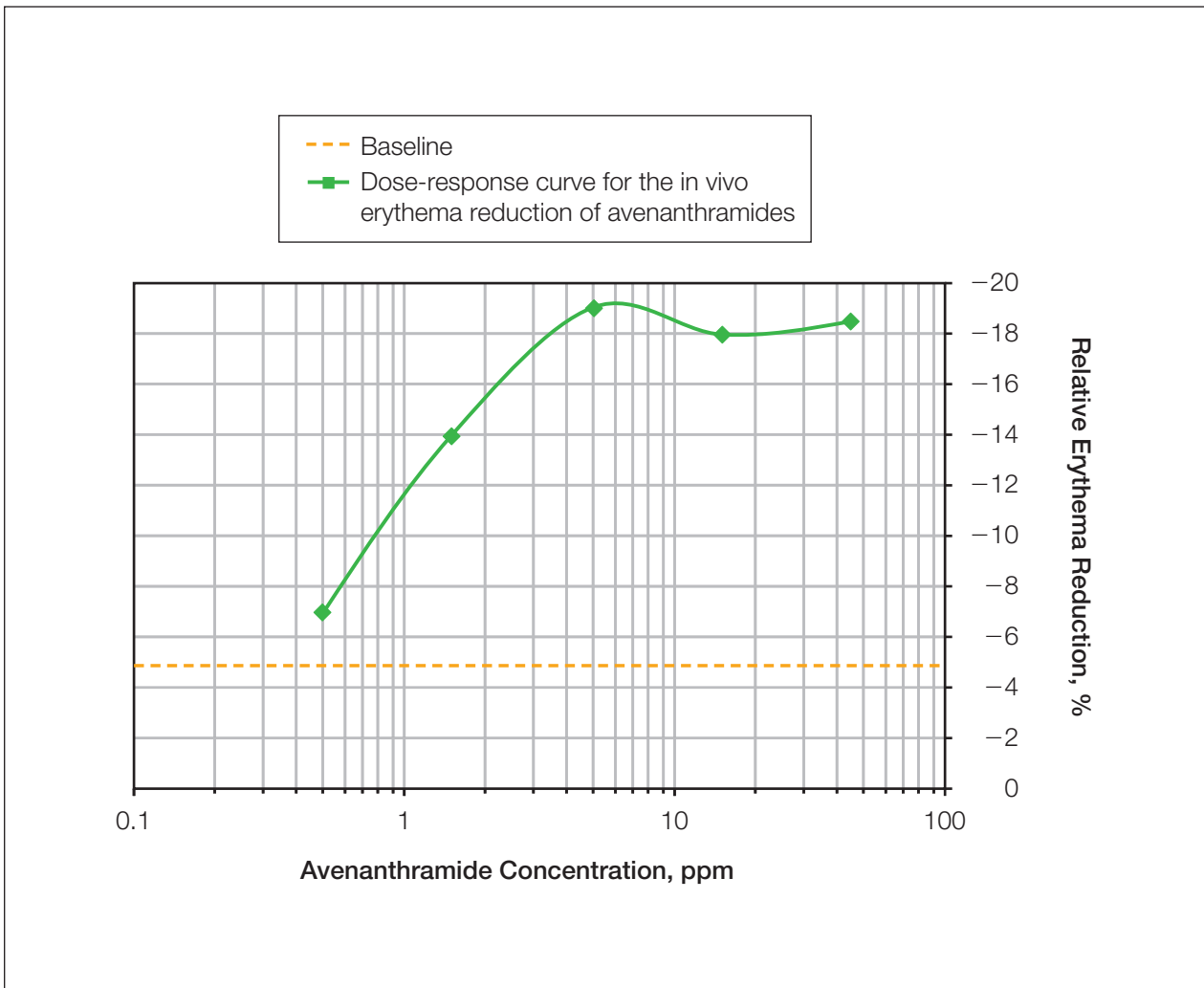


Figure 2. Anti-irritant activity of avenanthramides. Erythema was calculated 24 hours after irradiation with 1.5 minimal erythema dose UV light, with oat fractions diluted in 50% ethanol to a constant volume, relative to baseline. Adapted with permission from Schmaus et al.⁴⁰

barrier-enhancing properties of colloidal oatmeal are partially a function of oatmeal's ability to buffer acids and bases, which lowers the pH of pathologic skin in eczema and other pruritic conditions.³¹ Proteins and polysaccharides in colloidal oatmeal bind to the skin, forming a protective moisturizing barrier.³² Colloidal oatmeal functions as an emollient, humectant, and occlusive, forming a film on the skin's surface and thus decreasing TEWL. Oat lipids, glucans, and proteins also provide emollient and skin-softening activity.³³ Oat lipids constitute 2% to 12% of dry weight and include triglycerides; phospholipids; lecithin; glycolipids; and free fatty acids, such as stearic, palmitic, and oleic acids.^{34,35}

Oatmeal-Based Skin Care in AD—A skin care regimen that used a fragrance-free oatmeal-based

body wash once daily and an oatmeal-based therapeutic cream twice daily was studied in 21 subjects with mild to moderate AD and at least 5% body surface area involvement.³⁶ The oatmeal cream also contained glycerin as a humectant, ceramides to aid in moisture retention, panthenol to condition the skin, and petrolatum to act as an occlusive to slow TEWL. At least 70% of the subjects were using over-the-counter or prescription topical treatment of AD.³⁶ A 5-point scale (0=none, 1=slight, 2=mild, 3=moderate, 4=severe) was used to assess disease severity, itching, erythema, and scaling.³⁷ By the end of the 2-week study, there was a significant reduction from baseline in mean eczema severity score ($P<.05$). Mean itch severity scores were significantly improved

at weeks 1 and 2 after initiation of the skin care regimen ($P < .05$) (Figure 1).³⁶

Individuals of color with and without AD frequently experience dry skin with an ashy appearance, particularly in areas of friction and on extensor surfaces. A colloidal oatmeal moisturizer was studied in a 2-week investigator-blinded trial of subjects with Fitzpatrick skin types IV through VI.³⁸ Subjects used the oatmeal moisturizer twice daily. Improvements in moisturization and skin ash were visible after one day of use. The appearance of flaking and ash was reduced, and subjects perceived significant reductions in itching, tightness, ash, and scale, also within one day of use ($P < .05$).^{36,38,39}

The use of oiled colloidal oatmeal baths in 25 subjects with a history of AD and moderately dry legs was evaluated in a 4-week, investigator-blinded, crossover study. Subjects soaked their legs for 20 minutes daily for 7 days.³² After one week with no treatment, they crossed over to another treatment for 7 days. The oatmeal bath provided 50% and 67% reductions in itching and burning scores, respectively.³²

Avenanthramides: A Newly Discovered Oat Fraction—Avenanthramides, a class of polyphenolic antioxidants that constitutes approximately 0.05% dry weight, have been discovered in oat grains and may account for the anti-inflammatory activity attributed to colloidal oatmeal.⁴⁰ Recently, a formulation containing a proprietary standardized avenanthramide fraction isolated from oats, *Avena sativa* kernel extract, has been introduced for inclusion into topical products.

The ability of 7 oat fractions to reduce UV radiation–induced erythema was studied by chromometry in 9 subjects.⁴⁰ Test areas of the skin were treated 24 hours after irradiation with 1.5 minimal erythema dose UV light, with the different oat fractions diluted in 50% ethanol to a constant volume. Erythema was calculated relative to baseline. The avenanthramide fraction was shown to have the greatest activity against erythema. This activity was dose-dependent, with an 18% reduction from baseline at a concentration of 100 ppm (Figure 2).⁴⁰

Other measures were used to evaluate the anti-inflammatory property of avenanthramides.

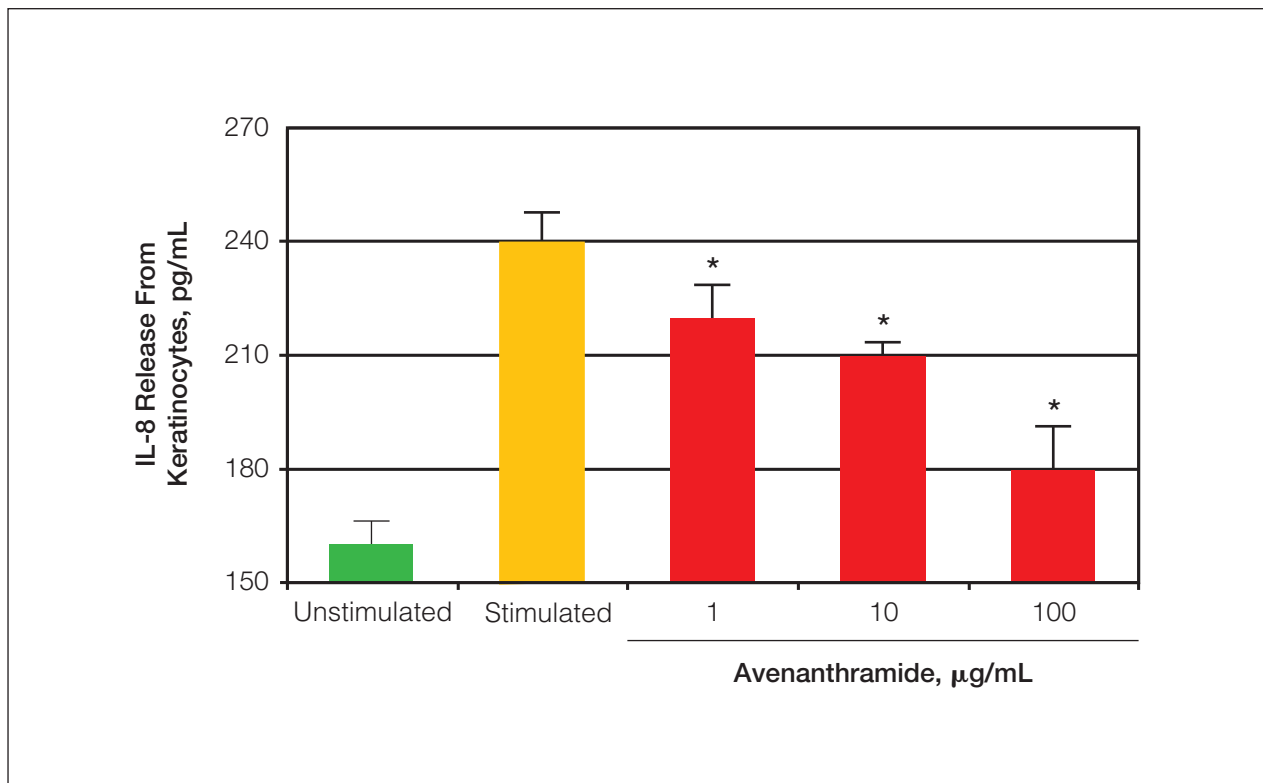


Figure 3. Reduction of stimulated release of interleukin 8 (IL-8) from tetradecanoylphorbol acetate–stimulated keratinocytes by avenanthramides. Unstimulated findings also are presented. Asterisk indicates significant reduction in nuclear factor- κ B activity ($P < .05$). Adapted with permission from Wallo et al.³²

IL-8 is a proinflammatory cytokine that is elevated in irritated and inflamed skin. It is a potent chemotactic factor in AD and can induce infiltration of neutrophils to inflamed areas.⁴¹ In one study, healthy human neonate epidermal keratinocytes were incubated either with or without tetradecanoylphorbol acetate (TPA) 25 nm in the presence of avenanthramides at concentrations ranging from 0.1 to 100 $\mu\text{g/mL}$ or vehicle.³² The release of IL-8 from keratinocytes was measured by enzyme-linked immunosorbent assay. Figure 3 shows the significant reductions of stimulated release of IL-8 from TPA-stimulated keratinocytes at each dose of avenanthramide ($P < .05$). In another study, avenanthramides were found to significantly decrease TPA-stimulated transcription of nuclear factor- κB (NF- κB)-dependent luciferase activity at doses of 0.1, 1, 10, and 100 $\mu\text{g/mL}$ ($P < .05$) (Figure 4).³² NF- κB is a primary transcription factor in numerous inflammatory pathways in skin (including cyclooxygenase 2 and TNF- α) and appears to be an important inflammatory mediator in AD.⁴² Treatment with NF- κB signaling pathway inhibitors has been

shown to reduce atopiclike symptoms in preclinical studies. Thus, the ability of avenanthramides to reduce production of proteins from numerous inflammatory pathways associated with AD would seem likely to be of clinical benefit in AD.³²

Another in vitro study examined the effect of avenanthramides on histamine release from peritoneal mast cells stimulated by substance P.⁴⁰ Mast cells were incubated for 2 minutes in substance P and either avenanthramides at 0.5, 5, or 50 ppm, or reference products, and the supernatants were harvested by centrifuge. Secreted histamine was quantified by spectrofluorometer. Figure 5 shows the dose-related net histamine release as a percentage of control at the 3 different concentrations.⁴⁰ At a concentration of 50 ppm, histamine release was virtually completely inhibited.

An in vivo study of 10 subjects sought to evaluate the effect of avenanthramides on histamine-induced itch, skin redness, and wheal area at 6 application sites in each subject.⁴⁰ They were treated with a commercial formulation, placebo, pentylene glycol humectant 5% vehicle, avenanthramide 100 ppm, or avenanthramide 100 ppm in

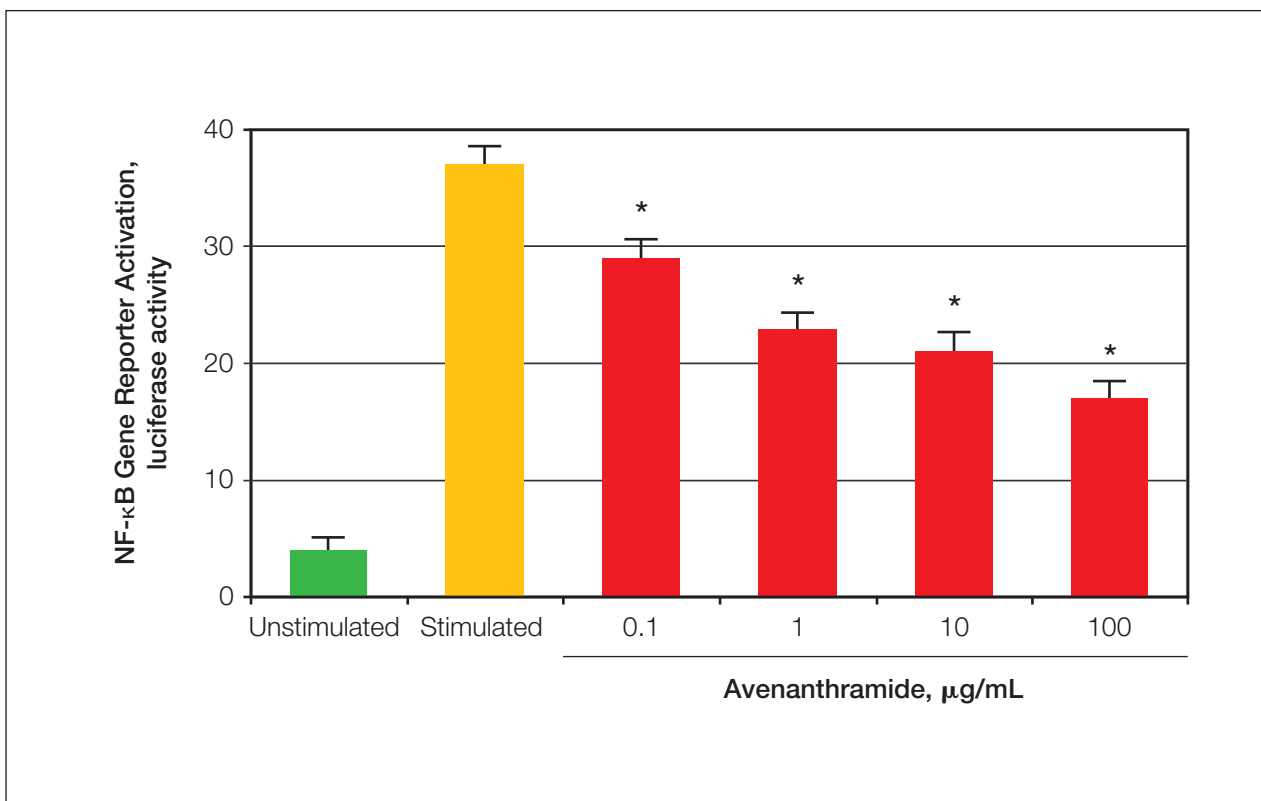


Figure 4. Dose-dependent reduction in nuclear factor- κB (NF- κB) activation by avenanthramides. *Stimulated* refers to the release of NF- κB ; NF- κB is stimulated by an agent (tetradecanoylphorbol acetate [TPA]) to create or induce an inflammatory response. *Unstimulated* means that TPA was not used to stimulate NF- κB . Asterisk indicates significant reduction in NF- κB ($P < .05$). Adapted with permission from Wallo et al.³²

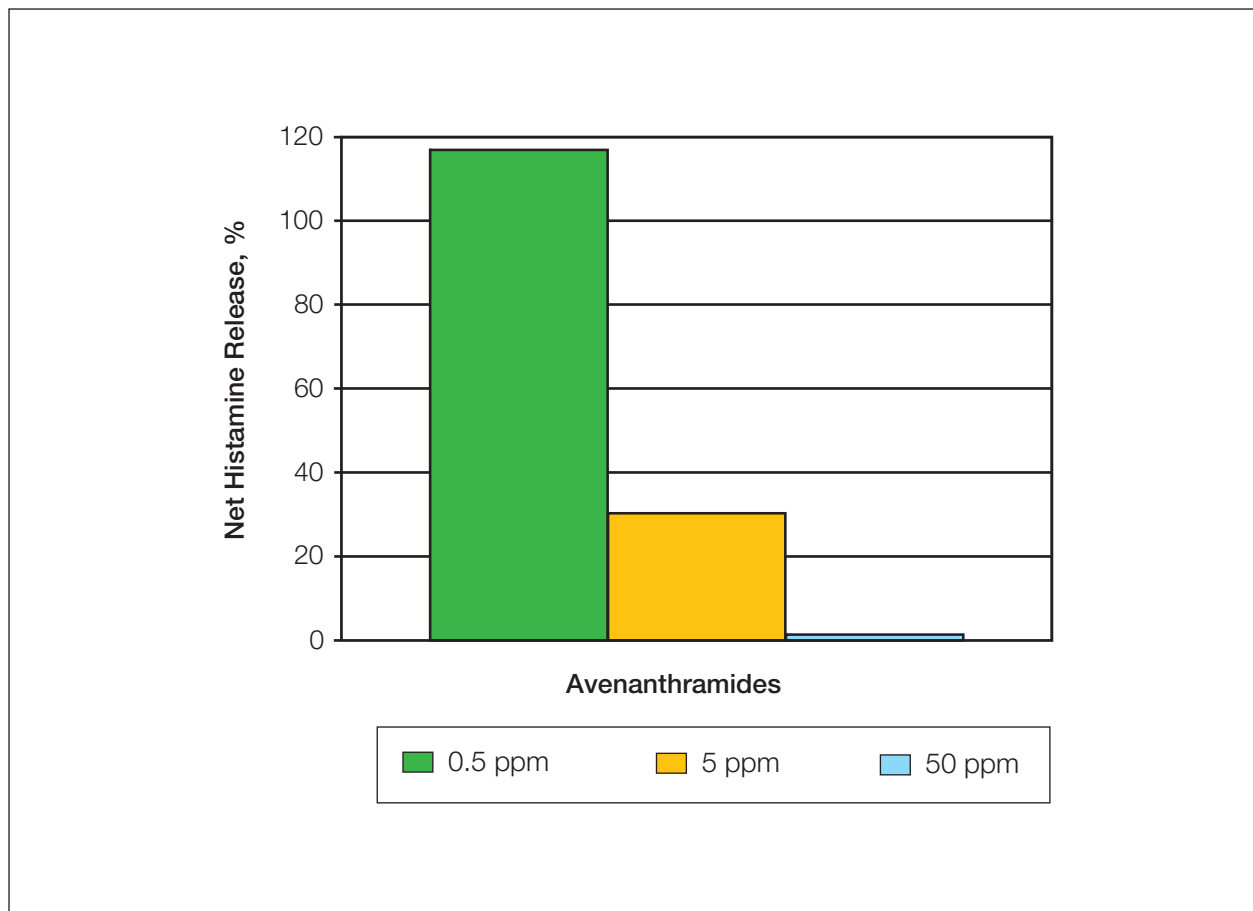


Figure 5. Dose-related net histamine release as a percentage of control at 3 different concentrations of avenanthramides. Adapted with permission from Schmaus et al.⁴⁰

the humectant 5% vehicle, or they were untreated. Histamine hydrochloride 10 mg/mL was applied to the skin, and the skin was pricked. Itch and a strong wheal response were observed after 5 minutes, at which point test products were applied at a dose of 2 mg/cm². Itch, skin redness, and wheal area were measured at 30-minute intervals for 3 hours after treatment. Itch was significantly reduced in the 2 avenanthramide-treated groups compared with untreated controls within 30 minutes ($P < .05$). A similar reduction over time also was seen in wheal area. Redness began to diminish within 30 minutes and had virtually disappeared in the avenanthramide-treated groups within 2.5 hours after application.⁴⁰

Natural Ingredients to Treat Inflammation—Feverfew, a flowering plant related to the chrysanthemum family, has been used orally in folk medicine to treat fevers and migraine headaches. However, efficacy in those conditions has been attributed to skin-sensitizing compounds called parthenolides.

Recently, a parthenolide-free extract of feverfew (feverfew PFE™) was developed and found to have strong anti-inflammatory and antioxidant activity when used topically.⁴³ In a randomized, double-blind, 3-week study, 31 women aged 25 to 62 years with self-perceived or clinically defined sensitive skin and/or a history of atopic disorders were treated with a facial moisturizer containing feverfew PFE.⁴⁴ For morning use, the formulation also contained a UVA/UVB sunscreen with sun protection factor (SPF) 15. A formula that did not contain sunscreen was applied every evening. Significant improvements in erythema, overall irritation, and tactile roughness were noted by subjects and investigators ($P < .05$).⁴⁴

Several licorice extracts from the plant *Glycyrrhiza glabra* have been shown to possess anti-inflammatory activity and the ability to inhibit melanogenesis.⁴⁵ Licochalcone A, which is derived from another member of the licorice family, also has been shown to possess potent

anti-inflammatory activity including inhibition of UV-induced prostaglandin E₂ release by keratinocytes as well as stimulated release of IL-6/TNF- α by monocyte-derived dendritic cells. Licochalcone A also may inhibit cyclooxygenase and lipoxygenase.⁴⁶ The dual activity of licorice extracts with regard to inhibition of both inflammation and melanogenesis makes them ideal for the management of both irritation and PIH in sensitive ethnic skin.

Maintenance of the Skin Barrier in AD With Active Natural Ingredients—Maintenance of remission in AD is partially dependent on ensuring the health of the epidermal barrier. Typical emollients may temporarily decrease TEWL, increase hydration, and improve skin comfort. In a study of children with stubborn to recalcitrant AD who continued standard therapy for AD (topical calcineurin inhibitors or corticosteroids), subjects were treated for 21 weeks with a ceramide-dominant, physiologic, lipid-based emollient in place of standard moisturizers.⁴⁷ The treatment formulation contained physiologic lipids that included 2.1% free fatty acids and 0.8% cholesterol in an oil-in-water vehicle. By week 12, there was dramatic improvement in almost all subjects, and application was reduced to once daily. Subjects were assessed by severity scoring of atopic dermatitis (SCORAD) values. By 3 weeks of treatment, SCORAD values had improved significantly in 22 of 24 subjects ($P < .05$). The values continued to improve in all subjects to study end at 21 weeks. TEWL, which was increased in both involved and nonlesional areas at baseline, also decreased and continued to improve after SCORAD values had reached a plateau. SC cohesion and hydration as quantified by tape stripping and quantitation of electrical capacitance by corneometry improved slowly but significantly over the course of the trial ($P < .01$). Tape stripping also revealed the presence of extracellular lamellar membranes that were typically absent at baseline.⁴⁷

Pantothenic acid is essential to normal epithelial function and is frequently added to cosmetic products as an anti-inflammatory agent. Dexpanthenol, the stable alcohol analogue of pantothenic acid, has been shown to moisturize, reduce TEWL, and improve pruritus, in addition to reducing UV radiation-induced erythema. In a multicenter study, 483 subjects with AD, ichthyosis, psoriasis, or contact dermatitis were treated with several commercially available emollient formulations containing dexpanthenol 3%.⁴⁸ All symptoms, including dryness, roughness, scaling, pruritus, erythema, and skin fissures, improved by

more than 80% over baseline. Improvement in dryness and desquamation improved as much as 90%. Local irritation was observed only in 1.9% of subjects.⁴⁸

SUN AND SUN PROTECTION IN AD AND SENSITIVE ETHNIC SKIN

All skin types require protection from the sun's radiation, not only for sensitive or atopic skin but also for more deeply pigmented skin types, which is contrary to what many medical authorities, as well as patients themselves, have long believed. The need for sun protection is best demonstrated by the rising rates of malignant melanoma (MM) in groups previously believed to be relatively immune from UV radiation-related cancers and other types of photodamage.

UV Radiation Effects on the Skin Barrier

UV radiation can affect the skin barrier in several ways, particularly in individuals with sensitive or atopic skin whose barrier already is likely to be compromised. Most studies suggest that the low-humidity conditions of winter are most apt to exacerbate atopic and/or sensitive skin.⁴⁹⁻⁵¹ It has been shown that low-humidity conditions increase the number of mast cells and dermal histamine content, which is an important chemical mediator for itching. A minority of patients with AD have disease flares in the summer if heat or exposure to sun, saltwater, or pool water initiates the itch-scratch-itch cycle. However, a recent study in the hairless mouse model demonstrated significant increases in TEWL following a single dose of UVB irradiation (0.15 J/cm²) ($P < .05$).⁵² TEWL began at day 2 post-irradiation and peaked at day 4. Electron microscopy revealed marked morphologic abnormalities, including abnormal profiles of lamellar granules and their contents at the interface between the SC and the stratum granulosum and the persistence of nuclei in the SC.⁵² This finding suggests that UV radiation may affect SC health through alterations in SC lipids and consequent barrier disruption. There is evidence that UV radiation has direct effects on the skin barrier, which is already compromised in patients with AD, in addition to the well-known cancer risks of sun exposure, namely invasive MM and melanoma in situ.

New Findings on Melanoma Risk

The most recent projections regarding the risk of both invasive MM and melanoma in situ in the United States show an estimated total of 108,650 cases in 2007, with a 1 in 33 lifetime risk of developing MM.⁵³ From 2000 to 2004, the

largest increases in incidence and mortality were among the growing Hispanic population (4% and 1%, respectively) and, although the incidence of MM increased between 1992 and 1999 in African Americans (4.9%), mortality has actually decreased (-1.1%).⁵⁴ This finding reminds clinicians that their index of suspicion must be high for their patients with skin of color. Study findings have suggested that underdiagnosis is a substantial problem. An incidence study from California showed an annual increased MM incidence of 1.8% between 1988 and 2001 in Hispanic males. Of particular importance was that thick invasive lesions (>1.5 mm) increased by 11.6% annually in Hispanic males and 8.9% in Hispanic females.⁵⁵ This increase in thicker lesions implies delayed diagnosis and a lower than appropriate index of suspicion in this group. One retrospective chart review of 649 African American patients treated for MM showed that African Americans were more likely to present with stage III or stage IV disease and that their 5-year survival rate was 59% versus 85% for white patients, underscoring the necessity for greater physician and patient education. The same study found that MM in African Americans tended to present in locations that were unusual for white patients, such as the plantar and palmar surfaces, mucous membranes, and nail beds.⁵⁶

The Role of Sunscreens

There has been controversy as to whether the use of sunscreens offers protection from MM. The Nambour Skin Cancer and Actinic Eye Disease Prevention Trial was a community-based clinical trial of 1621 adults who were randomized in 1992 to either 4.5 years of daily application of a broad-spectrum sunscreen with SPF 17 to the head, neck, forearms, and hands, or 4.5 years of discretionary sunscreen use.⁵⁷ Between 1993 and 2005, 21 cases of MM were diagnosed (8 in the intervention treatment group vs 13 in the discretionary-use control group) for a melanoma incidence rate of 70 and 113 cases per 100,000 person-years in the intervention group and control group, respectively. Thus, the daily use of sunscreen led to a 39% reduction in relative risk for melanoma. Late benefits shown in this study included a 25% relative risk reduction for basal cell carcinomas and a 51% reduction in relative risk for squamous cell carcinomas in 2001-2004.⁵⁷ A similar study in Australia found that squamous cell carcinomas decreased by almost 40% in those subjects who used sunscreen regularly versus sporadic application of sunscreen over 8 years.⁵⁸

Despite findings that show sunscreen use does help reduce the rates of skin cancers, sunburn prevalence is increasing. Cross-sectional data from 1999, 2003, and 2004 showed an increase in sunburn prevalence in adults in the United States from 31.8% in 1999 to 33.7% in 2004.⁵⁹ A survey of more than 1500 African Americans found that 6% reported skin that was extremely sensitive to the sun. An additional 9% reported developing mild sunburn after one hour of exposure. Thus, sun protection is not merely for fair-skinned individuals. Black skin can and does burn.⁶⁰

Among the reasons for decreasing sunscreen use are confusing messages regarding the need for sun exposure for vitamin D synthesis and questions as to whether sunscreens offer real protection or permit people to remain outdoors longer, assuming that they are protected. Another issue is the rate of sensitivity to sunscreens that may prevent patients from using them. In a study of 402 subjects with suspected allergic or photoallergic reactions to sunscreen, 20% tested positive to 4 UVA and 6 UVB protective agents.⁶¹

Sunscreen vehicles frequently present problems for individuals with sensitive skin. In a study of 603 subjects randomized to apply either sunscreen or vehicle for 7 months, 19% developed reactions. Most reactions were from the vehicle, while less than 10% were from the sunscreen agents.⁶² Thus, individuals with self-described sensitive skin may limit their sunscreen use due to irritant reactions. The sunscreen agent most commonly associated with sensitivity was sulisobenzone, which is in some newer formulations.⁶³

Traditional Sunscreen Shortcomings and Some Solutions

When sunscreens are underapplied or not re-applied frequently enough, they do not deliver the levels of sun protection claimed by their SPF number. The SPF number represents the level of protection offered by an application of 2 mg/cm² versus the reported real-life use of 0.5 mg/cm².^{64,65} The wide variations in adequacy of application suggest why sunscreens fail and why their use has been reported as a risk factor for melanoma.⁶⁶ It has been shown that underapplication of sunscreens reduced the expected SPF by 50% to 80%.⁶⁷ Another study showed that sunscreen with SPF 30 applied at the rate of 2 mg/cm² resulted in 100% of rated protection; however, at an application rate of 1 mg/cm², rather than being halved to SPF 15, as might be expected, the SPF actually falls as the square root to an SPF of approximately 5.

Moreover, if the recommended amount applied is doubled, the SPF increases exponentially.⁶⁸

Underuse of sunscreen also may be due to formulations that lack cosmetic elegance.⁶⁴ However, increasing the SPF requires additional sunscreen ingredients, which increases formulation challenges. The findings of a 1-week double-blinded sunscreen-use test comparing consumer application of SPF 15 to SPF 30 products revealed that higher SPF products, which felt heavier on the skin, were used more sparingly, whereas those with a lower SPF were used more consistently.⁶⁹ These findings suggest that a lower SPF product that is applied correctly will offer more protection than underapplication of SPF 30 products.

Photostability has been a problem with initial generations of sunscreens. All sunscreens are unstable by definition because their function is to absorb UV energy. Photodegradation occurs over hours and is particularly an issue with UVA radiation.⁷⁰ New technology has led to improvements in UVA protection and photostability. Combinations of organic filters such as octocrylene and avobenzone have better photostability, and several new complexes are available.

Ecamsule is a stable filter that provides broad-spectrum short- and long-wavelength UV protection. Ecamsule protects against UVA wavelengths in the 320- to 340-nm range. The filter is combined with octocrylene and avobenzone. Active photobarrier complex includes avobenzone that is photostabilized with the solvent diethylhexyl 2,6-naphthalate⁷¹; oxybenzone as a secondary UVA filter and stabilizer; and the UVB sunscreens octisalate, homosalate, and octocrylene. Several active natural ingredients may be added, including natural soy to improve skin tone, texture, and pigmentation, as well as vitamins C and E to add antioxidant photoprotection.^{64,72}

The benefits of photostabilized UVA protection were demonstrated in a study of high-altitude golfers who received one minimal erythema dose of natural sunlight after applying the active photobarrier sunscreen with SPF 45.⁷³ After 2 hours, each golfer reapplied sunscreen to one side of the body (randomly chosen by each golfer). After another 2 hours of play, none of the subjects could be differentiated by the amount of erythema on either side, suggesting that the formulation was both highly protective and photostable over 4 hours of exposure.⁷³

The Benefits of Active Natural Ingredients in Sun Protection

The addition of natural plant-derived antioxidants to sun protection products is an important way of

conferring added photoprotection. Topical application of plant flavonoids has been shown to provide potent photoprotection and add to the skin's physiologic antioxidant reservoir to increase protection against direct (induction of mitogen-activated protein kinase) and indirect (inflammatory) free radical damage.⁶⁴

The small soy proteins, soybean trypsin inhibitor and Bowman-Birk inhibitor, from whole fresh soy (total soy) have been shown to inhibit the protease-activated receptor 2 pathway, which decreases the transfer of melanosomes to keratinocytes, thus lightening the skin.⁷⁴ A recent randomized, 12-week, placebo-controlled study enrolled 63 women aged 30 to 55 years with moderate skin roughness, mottled hyperpigmentation, lentigines, blotchiness, and/or skin dullness.⁷² The subjects used either a total soy and broad-spectrum moisturizer with SPF 30 or a placebo moisturizer with SPF 30. At week 12, improvements in skin tone, texture, and radiance were visible to the eye and by enhanced photography. A significant increase in skin luminosity and a decrease in the yellow coordinate was demonstrated by colorimeter ($P < .05$). Significant improvements also were demonstrated in facial skin hydration throughout the study ($P < .05$). These findings suggested that total soy may be helpful in maintaining the skin barrier in all skin types but may be especially useful in helping to guard against the development of PIH and to minimize blotchy hyperpigmentation and skin dullness that is a frequent complaint of individuals of color.⁷²

Green tea polyphenols repeatedly have been shown to afford substantial photoprotection with topical use. This protection includes the ability to quench reactive oxygen species generated by UV radiation, modulation of inflammatory pathways and transcription factors, inhibition of *c-fos* expression and UVB radiation-induced activator protein-1 activation, prevention of UVB radiation-induced erythema, and reduction of UV radiation-related Langerhans cell depletion.^{75,76} Another interesting effect of green tea may be the inhibition of angiogenesis, which is thought to influence growth of skin cancers. Topical application of one of the green tea polyphenols, (-)-epigallocatechin-3-gallate, to UV radiation-induced tumors in hairless mice was found to inhibit not only protein expression and activity of matrix metalloproteinases but also CD31, a cell surface marker of vascular endothelial cells and endothelial growth factor, which is necessary for angiogenesis.⁷⁷

Feverfew PFE has been shown to inhibit UV radiation-induced erythema.⁷⁸ Thus, in addition to

the skin-calming properties it offers to individuals with sensitive skin, feverfew PFE also offers some degree of sunburn protection.

COMMENT

The prevalence of eczematous diseases is increasing, and these conditions may be underdiagnosed and undertreated. Because these dermatoses can have a serious impact on the quality of life of patients as well as their families, it is important for clinicians to recognize AD and to be aware of the new options for both treatment of acute flares and maintenance therapy. Many of the gentle barrier-enhancing treatments discussed here are particularly appropriate for the sensitive skin of individuals of color with eczema who have a tendency to develop hyperpigmentation or scarring following irritation, inflammation, or sun exposure.

Once AD flares are controlled, it is important to consider other agents that may be safer for long-term use. It is clear that abnormalities in the skin's hydrolipid film lead to increased TEWL and dryness and initiation of the itch-scratch-itch cycle, which leads to further damage to the barrier through excoriations. Ceramides in particular appear to be deficient in the epidermis of patients with AD, and the ceramide-cholesterol ratio is abnormal.

Over many years, colloidal oatmeal, with its beneficial mixture of appropriate lipids and polysaccharides, has been shown to be helpful in restoring and maintaining the skin barrier in a variety of conditions. Recently, a new class of oat fractions, the avenanthramides, has been discovered. In vitro and in vivo studies have established their activity against irritation, inflammation, and erythema, as well as itching and histamine release in the skin. It is likely that many of the anti-inflammatory effects that have been seen with colloidal oatmeal are actually because of the avenanthramide fraction of the oat grain. New products that add avenanthramides to colloidal oatmeal greatly enhance the utility of the oatmeal for the management of dermatoses such as AD.

Other natural anti-inflammatory options include feverfew PFE and licorice extracts. Both are gentle enough for sensitive or uncomfortable skin as well as skin of color. Licorice extract also has some depigmenting activity, which makes it a good choice for patients of color whose sensitive skin, sun exposure, or AD sequelae have led to pigmentary issues.

A final message is the necessity of sun protection for all skin types. UV radiation exposure can exacerbate barrier issues for patients with AD. Statistics have clearly demonstrated that the incidence

of MM is increasing throughout the US population, including individuals with skin of color. In addition to underapplication, reasons that sunscreens may be less than fully effective include a lack of photostability in the sun, particularly for UVA filters; sensitivity to active and vehicle ingredients; and aesthetic issues, especially with the higher SPF products. The newest generation of sunscreens promises to correct many of these deficiencies through the addition of better photostabilizers and combinations of filters that extend protection against a wider spectrum of wavelengths. The addition of botanical agents extends photoprotection and aids the skin in defending itself against free radical damage and inflammation.

This summary of emerging research has been gathered in the hope of increasing the means at physicians' disposal to manage their patients with sensitive or atopic skin.

REFERENCES

1. National Institute for Allergy and Infectious Disease. Significant items in House and Senate Appropriations Committee Reports. 2005. Available at: http://www3.niaid.nih.gov/about/overview/pdf/fy06_reports.pdf. Accessed September 25, 2007.
2. National Institute of Arthritis and Musculoskeletal and Skin Diseases, National Institutes of Health. Atopic dermatitis (a type of eczema). Available at: http://www.niams.nih.gov/Health_Info/Atopic_Dermatitis/atopic_dermatitis_hoh.pdf. Accessed September 19, 2007.
3. Hanifin JM, Reed ML, Eczema Prevalence and Impact Working Group. A population-based survey of eczema prevalence in the United States. *Dermatitis*. 2007;18: 82-91.
4. Hanifin JM, Rajka G. Diagnostic features of atopic dermatitis. *Acta Derm Venereol Suppl (Stockh)*. 1980;92: 44-47.
5. Williams HC. On the definition and epidemiology of atopic dermatitis. *Dermatol Clin*. 1995;13: 649-657.
6. Eichenfield LF, Hanifin JM, Luger TA, et al. Consensus conference on pediatric atopic dermatitis. *J Am Acad Dermatol*. 2003;49:1088-1095.
7. Beattie PE, Lewis-Jones MS. A comparative study of impairment of quality of life in children with skin disease and children with other chronic childhood diseases. *Br J Dermatol*. 2006;155:145-151.
8. Absolon CM, Cottrell D, Eldridge SM, et al. Psychological disturbance in atopic eczema: the extent of the problem in school-aged children. *Br J Dermatol*. 1997;137: 241-245.
9. Leung DY, Boguniewicz M, Howell MD, et al. New insights into atopic dermatitis. *J Clin Invest*. 2004;113: 651-657.

10. Allam JP, Bieber T, Novak N. Recent highlights in the pathophysiology of atopic eczema. *Int Arch Allergy Immunol.* 2005;136:191-197. Epub February 8, 2005.
11. Leung D, Eichenfield L, Boguniewicz M. Atopic dermatitis. In: Wolff K, Goldsmith LA, Katz SI, et al, eds. *Fitzpatrick's Dermatology in General Medicine.* 7th ed. New York, NY: McGraw-Hill Professional; 2007: 1180-1193.
12. EczemaNet. The where, how and why of eczema. Available at: http://www.skincarephysicians.com/OLD/eczemanet_old_2004/april.html. Accessed September 7, 2007.
13. Imokawa G. Lipid abnormalities in atopic dermatitis. *J Am Acad Dermatol.* 2001;45(suppl 1):S29-S32.
14. Cork M, Robinson D, Vasilopoulos Y, et al. New perspectives on epidermal barrier dysfunction in atopic dermatitis: gene-environment interactions. *J Allergy Clin Immunol.* 2006;118:3-21. Epub June 9, 2006.
15. Seguchi T, Cui CY, Kusuda S, et al. Decreased expression of filaggrin in atopic skin. *Arch Dermatol Res.* 1996;288:442-446.
16. Weidinger S, Illig T, Baurecht H, et al. Loss-of-function variations within the filaggrin gene predispose for atopic dermatitis with allergic sensitizations [published corrections appear in *J Allergy Clin Immunol.* 2006;118:724 and *J Allergy Clin Immunol.* 2006;118:922]. *J Allergy Clin Immunol.* 2006;118:214-219. Epub June 9, 2006.
17. Werner Y, Lindberg M. Transepidermal water loss in dry and clinically normal skin in patients with atopic dermatitis. *Acta Derm Venereol.* 1985;65: 102-105.
18. Imokawa G, Abe A, Jin K, et al. Decreased level of ceramides in stratum corneum of atopic dermatitis: an etiologic factor in atopic dry skin? *J Invest Dermatol.* 1991;96:523-526.
19. Di Nardo A, Wertz P, Giannetti A, et al. Ceramide and cholesterol composition of the skin of patients with atopic dermatitis. *Acta Derm Venereol.* 1998;78: 27-30.
20. Sator PG, Schmidt JB, Honigsmann H. Comparison of epidermal hydration and skin surface lipids in healthy individuals and in patients with atopic dermatitis. *J Am Acad Dermatol.* 2003;48:352-358.
21. Lebwohl M, Herrmann LG. Impaired skin barrier function in dermatologic disease and repair with moisturization. *Cutis.* 2005;76(suppl 6):7-12.
22. Loden M. The skin barrier and use of moisturizers in atopic dermatitis. *Clin Dermatol.* 2003;21:145-157.
23. Berger TG, Duvic M, Van Voorhees AS, et al. The use of topical calcineurin inhibitors in dermatology: safety concerns. report of the American Academy of Dermatology Association Task Force. *J Am Acad Dermatol.* 2006;54:818-823.
24. Halder RM, Grimes PE, McLaurin CI, et al. Incidence of common dermatoses in a predominantly black dermatologic practice. *Cutis.* 1983;32:388, 390.
25. Sanchez MR. Cutaneous diseases in Latinos. *Dermatol Clin.* 2003;21:689-697.
26. Stephens TJ, Oresajo C. Ethnic sensitive skin: a review. *Cosmet Toiletries.* 1994;109:75-80.
27. Stamatas GN, Kollias N. Blood stasis contributions to the perception of skin pigmentation. *J Biomed Opt.* 2004;9:315-322.
28. Taylor SC. Skin of color: biology, structure, function, and implications for dermatologic disease. *J Am Acad Dermatol.* 2002;46(suppl 2):S41-S62.
29. Grimes PE, Hunt SG. Considerations for cosmetic surgery in the black population. *Clin Plast Surg.* 1993;20: 27-34.
30. Food and Drug Administration, HHS. Skin protectant drug products for over-the-counter human use; final monograph. final rule. *Fed Regist.* 2003;68: 33362-33381.
31. Grais ML. Role of colloidal oatmeal in dermatologic treatment of the aged. *AMA Arch Derm Syphilol.* 1953;68: 402-407.
32. Wallo W, Nebus J, Nystrand G, et al. Agents with adjunctive therapeutic potential in atopic dermatitis. Poster presented at: 65th Annual Meeting of the American Academy of Dermatology; February 2-6, 2007; Washington, DC. P712.
33. Hart J, Polla C, Hull JC. Oat fractions. *Cosmet Toiletries.* 1998;113:45-52.
34. Data on file. Warhol J. Biological activity of oat compounds: a review of the scientific and medical literature. Skillman, NJ: Johnson & Johnson Consumer Companies; 2000.
35. Zhou M, Robards K, Glennie-Holmes M, et al. Oat lipids. *J Am Oil Chem Soc.* 1999;76:159-169.
36. Nebus J, Wallo W, Fowler J. Evaluating the safety and tolerance of a body wash and moisturizing regimen in patients with atopic dermatitis. Poster presented at: 65th Annual Meeting of the American Academy of Dermatology; February 2-6, 2007; Washington, DC. P714.
37. Data on file. Nebus J. Statistical report. Skillman, NJ: Johnson & Johnson Products Worldwide; 2006.
38. Smith G. Ashy skin. Skin of Color Scientific Council; June 27, 2004; Philadelphia, Pa.
39. Nebus J, Smith G, Miller D, et al. Alleviating dry, ashen skin in patients with skin of color. Poster presented at: 62nd Annual Meeting of the American Academy of Dermatology; February 6-11, 2004; Washington, DC. P294.
40. Schmaus G, Herrmann M, Joppe H, et al. Oat avenanthramides: new actives to reduce itch sensation in skin. Paper presented at: 23rd Congress of the International Federation of Societies of Cosmetic Chemists; October 24-27, 2004; Orlando, Fla.
41. Douglass J, Dhimi D, Bulpitt M, et al. Intradermal challenge with interleukin-8 causes tissue oedema and neutrophil accumulation in atopic and non-atopic human subjects. *Clin Exp Allergy.* 1996;26:1371-1379.

42. Nakamura H, Aoki M, Tamai K, et al. Prevention and regression of atopic dermatitis by ointment containing NF- κ B decoy oligodeoxynucleotides in NC/Nga atopic mouse model. *Gene Ther.* 2002;9:1221-1229.
43. Liebel F, Southall M, Oddos T, et al. Topical formulation containing parthenolide-free extract of feverfew is highly effective in clinically reducing erythema induced by irritation or barrier disruption of the skin. Poster presented at: 63rd Annual Meeting of the American Academy of Dermatology; February 18-22, 2005; New Orleans, La. P1047.
44. Nebus J, Wallo W, Smith G, et al. Evaluating topical preparations in sensitive skin patients. Poster presented at: 63rd Annual Meeting of the American Academy of Dermatology; February 18-22, 2005; New Orleans, La. P1027.
45. Yokota T, Nishio H, Kubota Y, et al. The inhibitory effect of glabridin from licorice extracts on melanogenesis and inflammation. *Pigment Cell Res.* 1998;11:355-361.
46. Dieck K, Ceilley R, Immeyer J, et al. Anti-inflammatory properties of licochalcone A from *Glycyrrhiza inflata* on various human skin cells. Poster presented at: 63rd Annual Meeting of the American Academy of Dermatology; February 18-22, 2005; New Orleans, La.
47. Chamlin SL, Kao J, Frieden IJ, et al. Ceramide-dominant barrier repair lipids alleviate childhood atopic dermatitis: changes in barrier function provide a sensitive indicator of disease activity. *J Am Acad Dermatol.* 2002;47:198-208.
48. Ebner F, Heller A, Rippke F, et al. Topical use of dexampanthenol in skin disorders. *Am J Clin Dermatol.* 2002;3:427-433.
49. Ashida Y, Denda M. Dry environment increases mast cell number and histamine content in dermis in hairless mice. *Br J Dermatol.* 2003;149:240-247.
50. Denda M, Sato J, Tsuchiya T, et al. Low humidity stimulates epidermal DNA synthesis and amplifies the hyperproliferative response to barrier disruption: implication for seasonal exacerbations of inflammatory dermatoses. *J Invest Dermatol.* 1998;111:873-878.
51. Conti A, Rogers J, Verdejo P, et al. Seasonal influences on stratum corneum ceramide 1 fatty acids and the influence of topical essential fatty acids. *Int J Cosmet Sci.* 1996;18:1-12.
52. Jiang SJ, Chen JY, Lu ZF, et al. Biophysical and morphological changes in the stratum corneum lipids induced by UVB irradiation. *J Dermatol Sci.* 2006;44:29-36.
53. National Cancer Institute. Surveillance epidemiology and end results: melanoma of the skin. Available at: <http://seer.cancer.gov/statfacts/html/melan.html>. Accessed: September 9, 2007.
54. Ries LAG, Melbert D, Krapcho M, et al, eds. *SEER Cancer Statistics Review, 1975-2004*. Available from: National Cancer Institute, Bethesda, Md. Available at: http://seer.cancer.gov/csr/1975_2004/. Accessed September 9, 2007.
55. Cockburn MG, Zadnick J, Deapen D. Developing epidemic of melanoma in the Hispanic population of California. *Cancer.* 2006;106:1162-1168.
56. Byrd KM, Wilson DC, Hoyler SS, et al. Advanced presentation of melanoma in African Americans. *J Am Acad Dermatol.* 2004;50:21-24.
57. Jancin B. Less skin ca with daily sunscreen use. *Skin & Allergy News.* 2007;38(7):1, 9.
58. van der Pols JC, Williams GM, Pandeya N, et al. Prolonged prevention of squamous cell carcinoma of the skin by regular sunscreen use. *Cancer Epidemiol Biomarkers Prev.* 2006;15:2546-2548. Epub November 28, 2006.
59. Centers for Disease Control and Prevention (CDC). Sunburn prevalence among adults—United States, 1999, 2003, and 2004. *MMWR Morb Mortal Wkly Rep.* 2007;56:524-528.
60. Hall HI, Rogers JD. Sun protection behaviors among African Americans. *Ethn Dis.* 1999;9:126-131.
61. Schauder S, Ippen H. Contact and photocontact sensitivity to sunscreens. review of a 15-year experience and of the literature. *Contact Dermatitis.* 1997;37:221-232.
62. Foley P, Nixon R, Marks R, et al. The frequency of reactions to sunscreens: results of a longitudinal population-based study on the regular use of sunscreens in Australia. *Br J Dermatol.* 1993;128:512-518.
63. Hughes TM, Stone NM. Benzophenone 4: an emerging allergen in cosmetics and toiletries? *Contact Dermatitis.* 2007;56:153-156.
64. Pinnell S. Cutaneous photodamage, oxidative stress, and topical antioxidant protection. *J Am Acad Dermatol.* 2003;48:1-19; quiz 20-22.
65. Wulf HC, Stender IM, Lock-Andersen J. Sunscreens used at the beach do not protect against erythema: a new definition of SPF is proposed. *Photodermatol Photoimmunol Photomed.* 1997;13:129-132.
66. Huncharek M, Kupelnick B. Use of topical sunscreens and the risk of malignant melanoma: a meta-analysis of 9067 patients from 11 case-control studies. *Am J Public Health.* 2002;92:1173-1177.
67. Stokes R, Diffey B. How well are sunscreen users protected? *Photodermatol Photoimmunol Photomed.* 1997;13:186-188.
68. Faurschou A, Wulf HC. The relation between sun protection factor and amount of sunscreen applied in vivo. *Br J Dermatol.* 2007;156:716-719.
69. Grosick T, Tanner P. Efficacy as used, not as tested, is true measure of sunscreen performance. Poster presented at: 62nd Annual Meeting of the American Academy of Dermatology; February 6-11, 2004, Washington, DC. P121.
70. Data on file. Chu M. Skillman, NJ: Johnson & Johnson; 2006.

71. Bonda C, Steinberg DC. A new photostabilizer for full spectrum sunscreens. *Cosmet Toiletries*. 2000;115:37-45.
72. Nebus J, Wallo W, Smith G, et al. Clinical improvements in skin tone and texture using a facial moisturizer with a combination of total soy and SPF 30 UVA/UVB protection. Poster presented at: 64th Annual Meeting of the American Academy of Dermatology; March 3-7, 2006; San Francisco, Calif. P1106.
73. Rigel D, Cole C. Protection at high altitude in extreme sun conditions: sunscreen effectiveness and reapplication need evaluation. Poster presented at: 64th Annual Meeting of the American Academy of Dermatology; March 3-7, 2006; San Francisco, Calif. P2625.
74. Paine C, Sharlow E, Liebel F, et al. An alternative approach to depigmentation by soybean extracts via inhibition of the PAR-2 pathway. *J Invest Dermatol*. 2001;116:587-595.
75. Elmetts CA, Singh D, Tubesing K, et al. Cutaneous photoprotection from ultraviolet injury by green tea polyphenols. *J Am Acad Dermatol*. 2001;44:425-432.
76. Katiyar S, Elmetts CA, Katiyar SK. Green tea and skin cancer: photoimmunology, angiogenesis and DNA repair. *J Nutr Biochem*. 2007;18:287-296. Epub October 17, 2006.
77. Mantena SK, Roy AM, Katiyar SK. Epigallocatechin-3-gallate inhibits photocarcinogenesis through inhibition of angiogenic factors and activation of CD8⁺ T cells in tumors. *Photochem Photobiol*. 2005;81:1174-1179.
78. Tierney N, Liebel F, Kurtz E, et al. Daily use of a topical formulation containing parthenolide-free extract of feverfew clinically reduces the appearance of erythema due to ultraviolet exposure. Poster presented at: 63rd Annual Meeting of the American Academy of Dermatology; February 18-22, 2005; New Orleans, La. P1020.

NATURAL ADVANCES IN
ECZEMA CARE

