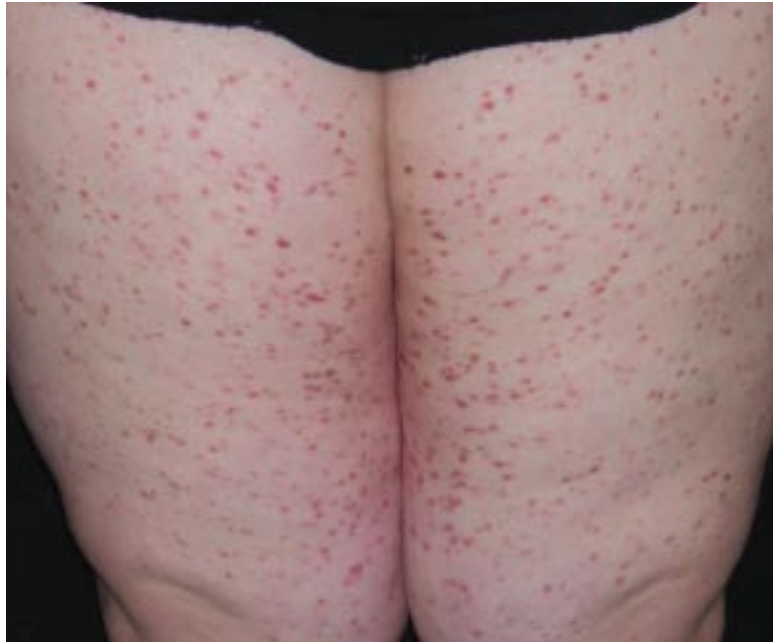

## What Is Your Diagnosis?



An 18-year-old woman presented with an erythematous maculopapular eruption that became progressively worse, distributed over the proximal upper and lower extremities. Onset was approximately 4 years prior to presentation. The patient had no other physical symptoms but did report her gallbladder had been removed 15 months prior due to abdominal pain.

PLEASE TURN TO PAGE 403 FOR DISCUSSION

Ryan P. Johnson, MPH, Ohio State University College of Medicine and Public Health, Columbus.

Brad Johnson, MD, Affiliated Dermatology, Dublin, Ohio.

Dwight A. Scarborough, MD, Affiliated Dermatology, Dublin, and the Department of Internal Medicine, Division of Dermatology, Ohio State University Medical Center, Columbus.

Joan C. Moad, MD, Dermatopathology Laboratory of the Central States, Dayton, Ohio.

The authors report no conflict of interest.

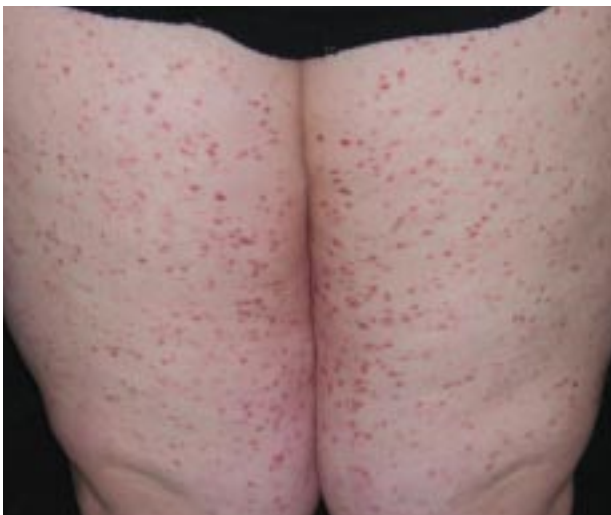## The Diagnosis: Cutaneous Mastocytosis (Urticaria Pigmentosa)

The patient presented with typical morphologic lesions of urticaria pigmentosa (Figure 1). The number of lesions can range from few to innumerable. She demonstrated typical urtication when a lesion was stroked (positive Darier sign). A biopsy specimen from a representative lesion on the left leg revealed an unremarkable epidermis with scattered spindle cells within the papillary and mid dermis (Figure 2). Examination with Giemsa stain revealed that the spindle cells were mast cells (Figure 3).

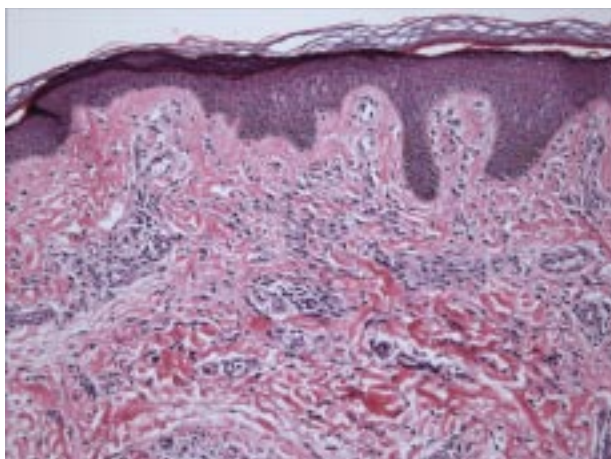
Mastocytosis is an overgrowth of mast cells in the bone marrow, skin, and lymphatic system. This abnormal proliferation can lead to the increased

release of mast cell mediators, including histamine, eicosanoids, cytokines, tryptase, heparin, leukotrienes, and prostaglandin D<sub>2</sub>. These mediators are responsible for the cutaneous and systemic manifestations of mastocytosis.<sup>1,2</sup> Cutaneous manifestations of mastocytosis are variable. The most common presentation is urticaria pigmentosa, pruritic tan-brown macules and papules on the trunk and proximal extremities that urticate when stroked (Darier sign). Frequently, presentation occurs in infants younger than 6 months.<sup>1</sup> In approximately half of these patients, the condition will resolve before their teenaged years.<sup>2</sup> In adults, urticaria pigmentosa presents as red-brown papules and Darier sign is more difficult to elicit, likely due to lower mast cell load. In addition to urticaria pigmentosa, other forms of cutaneous mastocytosis include solitary mastocytoma, bullous mastocytosis, erythrodermic mastocytosis, and telangiectasia macularis eruptiva perstans.<sup>1</sup>

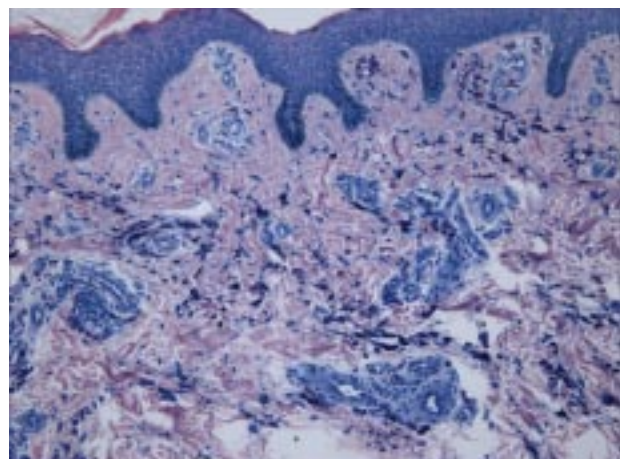
While most forms of mastocytosis are limited to the skin, systemic involvement can occur. Mast cells can accumulate in the bone marrow.<sup>3</sup> This indolent form of mastocytosis has a favorable prognosis and can present with pruritus, flushing, palpitations, tachycardia, headaches, syncope, gastrointestinal symptoms, cognitive dysfunction, and osteoporosis.<sup>1,3</sup> Ten percent of patients with systemic mastocytosis may develop non-mast cell lymphoma or leukemia. Mast cell leukemia rarely occurs and represents the most severe variant of mastocytosis.<sup>3</sup>



**Figure 1.** Patient's legs reveal typical morphologic lesions of urticaria pigmentosa.



**Figure 2.** Skin biopsy of the left leg (H&E, original magnification  $\times 100$ ).



**Figure 3.** Skin biopsy of the left leg (Giemsa, original magnification  $\times 100$ ).

An imbalance of apoptosis and proliferation may be the underlying pathogenic factors in mastocytosis.<sup>4</sup> The *c-kit* protooncogene expresses KIT, a tyrosine kinase receptor, which helps induce cell growth and prevent apoptosis. Stem cell factor is the ligand to KIT and works as a mast cell growth factor.<sup>1</sup> Certain mutations of the *c-kit* gene, particularly codon 816 mutation, can cause constitutive activation of KIT. This mutation presents in many adults with mastocytosis and may explain why some children with mastocytosis continue to have disease into adulthood.<sup>2,5</sup>

Treatment of mastocytosis is symptomatic, as no cure exists.<sup>6</sup> The patient was advised to avoid triggers of mast cell degranulation. Common triggers include rubbing, physical exertion, elevated temperature, alcohol ingestion, nonsteroidal anti-inflammatory drugs, general anesthesia, intravenous dye, and Hymenoptera and jellyfish stings. Occasionally, widespread degranulation of mast cells may result in anaphylaxis, requiring prompt access to emergency medications, such as epinephrine. Antihistamines and/or disodium cromoglycate are first-line treatment for symptomatic disease.

Corticosteroids, psoralen plus UVA, interferon alfa, and cyclosporine also have been effective in some cases. Unfortunately, inhibitors of *c-kit* and KIT have not been proven successful. By working to decrease mast cell mediators, leukotriene inhibitors are promising treatments for mastocytosis.<sup>6</sup>

## REFERENCES

1. Tharp MD. Mastocytosis. In: Bologna JL, Jorrizo J, Rapini RP, eds. *Dermatology*. St. Louis, MO: Mosby-Year Book Inc; 2003:1899-1906.
2. Soter NA. Mastocytosis and the skin. *Hematol Oncol Clin North Am*. 2000;14:537-555.
3. Brockow K. Urticaria pigmentosa. *Immunol Allergy Clin North Am*. 2004;24:287-316.
4. Hartmann K, Hermes B, Rappersberger K, et al. Evidence for altered mast cell proliferation and apoptosis in cutaneous mastocytosis. *Br J Dermatol*. 2003;149:554-559.
5. Brockow K, Scott LM, Worobec AS, et al. Regression of urticaria pigmentosa in adult patients with systemic mastocytosis: correlation with clinical patterns of disease. *Arch Dermatol*. 2002;138:785-790.
6. Almahroos M, Kurban AK. Management of mastocytosis. *Clin Dermatol*. 2003;21:274-277.