

Initial Studies Support Ablative Fractional Laser

BY DAMIAN McNAMARA
Miami Bureau

LAS VEGAS — Ablative fractional resurfacing shows promise for skin resurfacing and tightening, according to the first studies conducted on use of the technology.

Considered a more intense treatment than nonablative fractional devices, the ablative fractional laser could hypothetically mitigate the risks that are traditionally associated with ablative laser resurfacing.

“Will this ablative resurfacing really be the middle ground?” Dr. Zakiya Rahman asked at an international symposium on cosmetic and laser surgery.

Nonablative fractional resurfacing devices such as Fraxel were developed to produce results similar to those of ablative laser resurfacing with less downtime for patients. With ablative fractional resurfacing, there is more downtime, although it is still less than with ablative laser treatments, noted Dr. Rahman, who is with Stanford (Calif.) University.

Initial *ex vivo* studies of ablative fractional resurfacing on human skin revealed the degree of skin tightening possible at different energy settings: 20 mJ produced 10% area shrinkage, 32 mJ produced 18% shrinkage, and 40 mJ yielded 23% shrinkage.

“This is really significant to me,” Dr. Rahman said. At a high energy setting, 90 mJ, there was a reproducible 37% area shrinkage in the excised human tissue, she added.

Compared with nonablative devices, ablative fractional resurfacing devices increase depth of penetration. The width of the thermal treatment zones increases as the energy of the laser treatment increases. Histologic slides show annular

coagulation of dermal collagen and treatment zones that get smaller as they go deeper, Dr. Rahman said.

Results might be comparable to ablative laser outcomes. “At 19 mJ you definitely get immediate tightening, similar to what you would have with a CO₂ laser,” Dr. Rahman said.

Dr. Rahman also treated the forearms of 24 patients with an ablative fractional laser at settings that varied from 5 mJ per microablative zone (MAZ) to 40 mJ per MAZ. Two investigators assessed results at 1 week, 1 month, and 3 months after treatment to gauge safety and efficacy.

Further assessment consisted of full face and neck treatments at settings from 5 mJ per MAZ to 20 mJ per MAZ in 30 participants. Ten of these patients were studied at Stanford as part of this multicenter investigation.

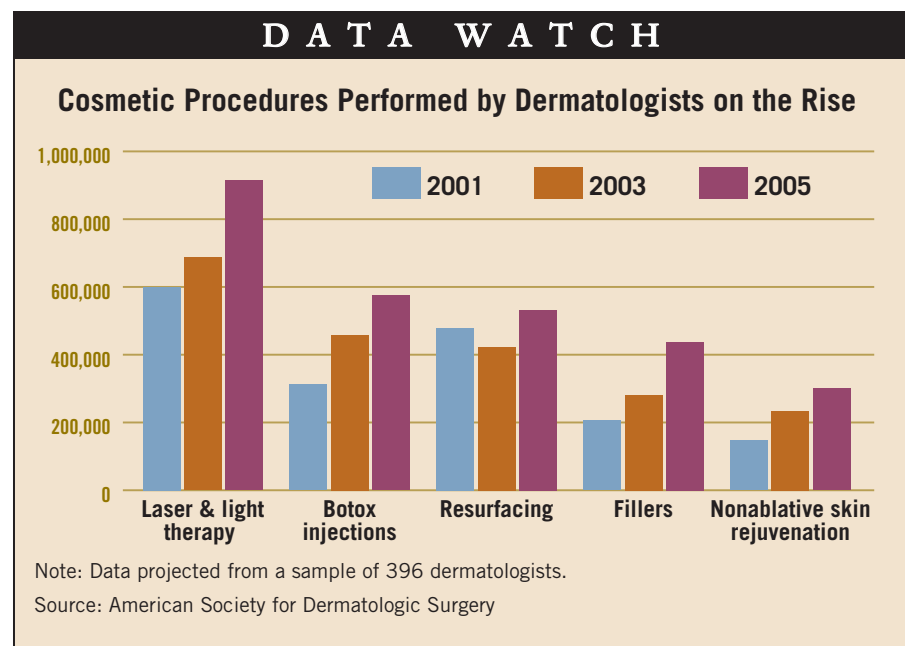
All participants in the forearm, face, and neck assessments had subjective and objective improvement of rhytides, pigmentation, and tissue laxity, Dr. Rahman said. Another patient showed significant improvement of the perioral area.

Improvements were sustained at a follow-up assessment at 3 months. Erythema resolved by this time and no adverse effects were reported. Most participants have been followed out to 6 months in this ongoing study.

The wound-healing response that was seen represents a significant improvement over traditional ablative resurfacing, said Dr. Rahman, who is a consultant for Reliant Technologies Inc., developer of the device.

In response to a meeting attendee’s question about the next step in development, Dr. Rahman said, “We are going to [a] higher energy setting now, 30 mJ, to see if we can get sustained and greater results.”

Results might be comparable to ablative laser outcomes. ‘At 19 mJ you definitely get immediate tightening, similar to what you would have with a CO₂ laser.’



Recognizing Postsurgical Red Flags Reduces Complications

BY MARY ELLEN SCHNEIDER
New York Bureau

NEW YORK — The severity of postsurgical complications can be mitigated by knowing the warning signs and best management techniques, Dr. James M. Spencer said at a meeting on medical and surgical dermatology sponsored by Mount Sinai School of Medicine.

Some bruising, for example, is very common after dermatologic surgery. If it’s performed in the periocular region, patients can expect to have a black eye. “This can obviously be very alarming to patients, but generally reassurance is all that’s necessary,” said Dr. Spencer of the department of dermatology at Mount Sinai in New York.

In the case of minor bleeding, advise patients to try direct pressure for 10-15 minutes and apply ice. If the bleeding can’t be controlled easily from home, the patient will have to come back in. He advised using lidocaine alone when numbing the wound area because epinephrine causes vasoconstriction and will make it hard to recognize bleeding problems.

A hematoma puts pressure on the wound and is an excellent growth medium for bacteria. Initially, the clot will be gelatinous and generally can be easily evacuated through a small opening, but once it organizes, it will be difficult to remove. Wait 7-10 days for the clot to liquify and reabsorb, Dr. Spencer said.

Like a hematoma, a seroma puts pressure on the wound. This generally can be evacuated

with an 18-gauge needle, he said.

A wound infection usually manifests 3-4 days after surgery and the classic signs include pain, redness, and swelling. Although gram-positive infection is most likely in dermatology, there are certain areas of the body where other infections also are likely. Pseudomonas should be considered on the ear and gram-negative infections in the groin and lower leg, Dr. Spencer said.

Contact dermatitis can mimic infection, though if the area is red and itchy, that’s a clue that it could be contact dermatitis. Patients may have an allergic reaction to either the topical antibiotic or to the glue of the bandage. Remove the offending agent and put the patient on a short course of topical steroids, he said.

When there is dehiscence, there are two choices—either resuture or allow the wound to heal by second intention. “Second intention, I think, is underutilized. You can get terrific results,” he said. If the wound is resutured, wash it, but don’t debride the wound edges excessively.

One of the worst postsurgical complications is necrosis. If the flap or graft is blue, then blood is going in but is not getting back out. In that case, try nitroglycerin cream to increase venous return. However, if the flap or graft becomes black, adherent, and crusted, that is necrosis. The physician should do nothing and wait for it to slough on its own. Since it’s not apparent how deep the necrosis goes, there could be a viable dermis underneath it. Debriding it just creates a large open wound, Dr. Spencer said.

Questions Raised About Efficacy of LED Photomodulation Treatments

BY ALICIA AULT
Associate Editor, Practice Trends

TORONTO — Available data suggest that light-emitting diode devices are of questionable utility for skin rejuvenation, Dr. Ranella Hirsch said at the annual fall meeting of the American Academy of Facial Plastic and Reconstructive Surgery.

Light-emitting diode (LED) photomodulation devices use nonablative technology—low-intensity light therapy—to nonthermally modulate the activity of living cells, said Dr. Hirsch, who is in private practice in Cambridge, Mass. The devices are used primarily to treat wrinkles, hyperpigmentation, redness, roughness, and pore size, she said.

The most prevalent unit, which has been approved by the Food and Drug Administration, is the GentleWaves LED photomodulation device from Light BioScience.

There is histologic evidence that LED devices stimulate collagen growth and do so without harming the skin’s surface, but most of that data have been generated by Light BioScience or investigators with close ties to that manufacturer or other LED makers, Dr. Hirsch said.

The company also submitted data to the

FDA that showed some potential clinical benefit after eight patient visits, she said.

LEDs offer an advantage over higher-powered lasers in that they can treat larger areas with lower energy.

It’s not certain, however, that there is no benefit at all. Some studies have indicated that LED technology may be useful for wound healing. A literature review published in 2005 found some studies showing improvements in surgical wound healing with low-level laser therapy, but those studies involved a rodent model and would need to be duplicated in pigs and then humans, the authors said (*Dermatol. Surg.* 2005;31:334-40).

The technology appears to be safe, said Dr. Hirsch, but is “by no definition a home run. I would put it in the same basket as microdermabrasion—by and large, there is no huge benefit, but there is no harm.”

Dr. Hirsch expressed other doubts about the technology, including the fact that a physician is not required to administer the therapy. Patients generally sit in front of the units for 10-15 minutes, once a week, for 8-10 weeks.

Dr. Hirsch is a clinical investigator for Candela Corp., Palomar, Cynosure, and Hoya ConBio.