

# Image-Enhanced Endoscopy Has 'Come of Age'

BY DOUG BRUNK  
San Diego Bureau

In the not-so-distant past, endoscopists always sought the input of pathologists when diagnosing gastrointestinal cancers.

Now, thanks to the maturation of image-enhanced endoscopy, endoscopists are sometimes able to make a diagnosis on the spot.

"The time for endoscopic diagnosis has come of age because now we have increased accuracy—sensitivity and specificity—in terms of diagnosing diseases, especially for the early tumors," Dr. Roy Soetikno, chief of the gastroenterology section at Veterans Affairs Palo Alto (Calif.) Health Care System, said in an interview.

"This technology is now hand in hand with the much-improved optics of the endoscopes. This allows more things to be done during endoscopic assessment, such as cutting tumors at time of assessment rather than going back in, so it's increasing efficiency and reducing costs."

In an effort to assist clinicians in the appropriate use of such technology, Dr. Soetikno and his associates assembled the guidelines, "Technology Assessment on Image-Enhanced Endoscopy," based on a Medline search performed through June 2007. The guidelines are the first of their kind (*Gastroenterology* 2008;134:327-40).

One reason that the researchers assembled these guidelines is to promote the use of image-enhanced endoscopy (IEE) outside of specialized academic centers, where it has been used almost exclusively. For many clinicians, using dye for image enhancement was a cumbersome process, requiring preparation of the solution, spraying it on, and interpretation.

"It added more time," Dr. Soetikno explained. "It was not just 'turn the key,' so to speak. Today, though, by changing the properties of the lights that go through the endoscope, we can mimic what could have been achieved by the dye. Either the endoscopy lights have changed, or we're using some kind of computer software to process the image, so in the end you highlight the gland or the abnormality, and you get a better diagnosis."

According to the guidelines, available data support the use of IEE in the detection and treatment of early squamous cell carcinoma of the esophagus, early gastric cancer, and superficial colorectal lesions.

The guidelines also state that the use of Lugol's solution "may improve the endoscopic visualization of high-grade dysplasia and early squamous cell carcinoma of the esophagus, and thus may be considered [for use] in high-risk patient populations."

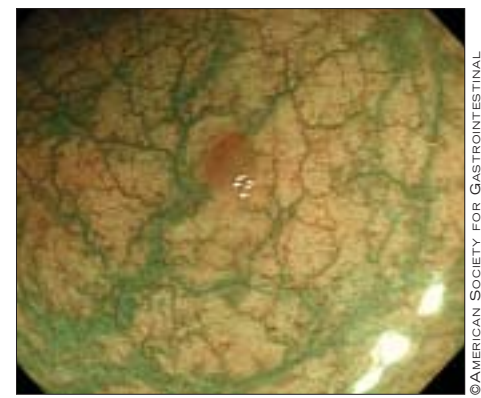
Diluted indigo carmine solution can be helpful in the diagnosis and treatment of early gastric cancer because it "pools at the

border of the lesion and thus enhances visualization of these lesions, which are most often nonpolypoid. By pooling into the depression or ulceration of the lesion, the solution aids in the classification of the morphology, which in turn is important in the medical decision making of treatment strategy."

Equipment-based advances in endoscopic imaging continue to evolve and enhance visualization, including devices that use manipulations of the light source or captured light.

Other approaches being studied include narrow-band imaging, which uses a narrow light source to enhance visualization of the surface microvessels; spectral estimation technologies, which use computerized processing to convert standard RGB (red, green, blue) signals from the endoscope's charged-coupled device; and autofluorescence imaging, which uses changes in concentrations of endogenous fluorophores.

The researchers also noted that high-resolution or high-definition endoscopes provide "a more detailed image of gastrointestinal mucosa, and high-magnification endoscopy enlarges the image up to 100×," compared with 30× in standard endoscopy, which uses a 20-inch monitor. "At higher magnification with IEE, the visualized surface patterns of the gastrointestinal mucosa have been suggested to



A brownish polypoid adenoma is clearly visualized with narrow-band imaging.

correlate well with the underlying histology.

"Proposed uses for high magnification used in conjunction with IEE include distinguishing neoplastic and nonneoplastic lesions, assessing depth of invasion in early colorectal carcinoma, and detecting minute tumor residue after endoscopic mucosal resection," the authors said.

Potential barriers to the dissemination of IEE "include perceptions of its inefficiency and [high] cost, inadequate mechanism for reimbursement, lack of standardized training in techniques, and deficiency of high-quality comparison studies," the researchers wrote.

Dr. Soetikno said that neither he nor his associates have any relevant financial relationships to disclose. ■

## Diabetes Tied to Colorectal Cancer Risk in Women

BY KERRI WACHTER  
Senior Writer

Diabetes may significantly increase a woman's risk of developing colorectal cancer, based on the findings of a study involving more than 45,000 women across the United States.

"There was about a 50% increased risk of colorectal cancer in women with diabetes," said Andrew Flood, Ph.D., a professor of epidemiology and community health at the University of Minnesota in Minneapolis.

Dr. Flood presented study findings at a press briefing held in conjunction with the annual international conference of the American Association for Cancer Research. He and his colleagues prospectively analyzed data from the Breast Cancer Detection Demonstration Project follow-up cohort study.

From 1987 to 1989, 45,519 women without a history of colorectal cancer completed a series of questionnaires that assessed dietary and other health and lifestyle risk factors for colorectal cancer. The average age at the time of the interview was 62 years. On average, the time between the baseline and follow-up was 9 years, during which time 489 women developed colorectal cancer. After the researchers controlled for age, physical activity, energy intake, alcohol consumption,

hormone therapy, smoking, multivitamin use, education, ethnicity, NSAID use, calcium supplementation, and calcium intake from diet, women with diabetes at baseline had an adjusted hazard ratio (HR) of 1.50 for developing colorectal cancer.

The researchers hypothesized that the elevated levels of insulin typically seen in people with type 2 diabetes may play a central role. Insulin stimulates the growth of normal colonic and carcinoma cells. Insulin also modulates insulin-like growth factor 1 (IGF-1) and its binding proteins, creating a prometotic environment for colonic epithelial cells.

When the researchers conducted a second analysis that included women who were likely prediabetic at baseline, according to self-reports at the 1993-1995 follow-up, the multivariate adjusted HR for developing colorectal cancer was slightly lower (1.36) in this population of women.

Among the prediabetic women, the degree of hyperinsulinemia may not have been of a sufficient magnitude or duration to increase the risk of colorectal cancer, the researchers speculated. Or there may be some factor related to diabetes, independent of hyperinsulinemia, that is driving the observed increase in colorectal cancer risk among the diabetic women. ■

## Laparoscopic-Assisted Colonoscopy Useful for Treating Difficult Polyps

BY ROBERT FINN  
San Francisco Bureau

SAN FRANCISCO — A combined laparoscopic-endoscopic approach can be effective in treating difficult colonic polyps, Dr. Morris E. Franklin Jr. said at the annual meeting of the Society of Laparoendoscopic Surgeons.

In a case series of 144 patients from whom 190 polyps were removed during laparoscopically monitored colonoscopic polypectomy (LMCP), only 4% required conversion to full-thickness resection, said Dr. Franklin of the Texas Endosurgery Institute, San Antonio.

The patients resumed eating an average of 6 hours after the surgery, stayed in the hospital an average of 1.1 days, and returned to full activity in an average of 2 days. In all, 10% of the patients experienced minor complications and none had major complications.

During an average of 74 months of follow-up, no patients experienced a recurrence and only three needed reoperation, in each case because of a new polyp in a different segment.

"Our gastroenterologists now selectively send patients that have difficult polyps for this procedure," Dr. Franklin said. The best candidates for LMCP are patients whose polyps are difficult to remove with a colonoscope alone. Removal may be difficult because of the size, location, or number of polyps.

Common indications include sessile broad-based polyps, very large polyps, or polyps that are difficult to reach, either because they are behind a fold or at a difficult angle. Dr. Franklin

also finds the technique useful in cases of redundant sigmoid colon, which can make it difficult to get to polyps on the right side.

In performing the procedure, the laparoscopist works alongside the colonoscopist. To properly coordinate the procedure, it is crucial that each physician can see both monitors.

The laparoscopist begins by lysing the adhesions and mobilizing the colon. "We found that if we could straighten out the sigmoid, it makes passage of the colonoscope very rapid and therefore cuts down on the time for this procedure," Dr. Franklin said.

The next step is to clamp the proximal bowel prior to the colonoscopy with polypectomy under microscopic guidance.

The laparoscopist monitors the serosal surface during the polypectomy, and sutures the polypectomy site if necessary. Occasionally the laparoscopist will perform a colotomy for a very large polyp that can't be removed with the colonoscope alone. Sometimes the laparoscopist will perform a full-thickness or segmental resection, particularly if the polyp appears likely to be cancerous. Frozen section evaluation is obtained on each specimen.

Dr. Franklin noted that the one disadvantage of LMCP is that the surgeon is reimbursed at a higher rate for segmental resections, but "if we're doing something good for the patients, that probably it's beneficial to all."

Dr. Franklin disclosed receiving research funds, serving as a consultant, and serving on the speaker's bureau for several manufacturers of medical devices. ■