

# MRI, CT Compete to Assess Bone Quality

BY SHERRY BOSCHERT

SAN FRANCISCO — Advances in imaging techniques are providing new insights into trabecular and cortical bone structure and may help assess bone quality, a key component of bone strength identified by a 2001 National Institutes of Health consensus panel.

Recent studies suggest that high-resolution MRI (hrMRI), multidetector CT, and high-resolution peripheral quantitative CT (hr-pQCT) each may be useful in assessing bone quality. But each brings different advantages and disadvantages, and it's unclear which imaging modality will be best for identifying osteoporotic fractures and monitoring treatment-related changes in bone structure.

The three imaging modalities can produce significantly different absolute numbers compared with each other when assessing trabecular or cortical bone structure, yet all correlate reasonably well with micro-CT as a standard of reference, Dr. Thomas M. Link said at a conference sponsored by the International Society for Magnetic Resonance in Medicine. Because of differences in acquisition and analysis of the images, bone structure data from the three imaging modalities are not directly comparable.

Trabecular and cortical bone structure are key components of bone quality, which was deemed to be an important component of bone strength, according to NIH (JAMA 2001;285:785-95).

In one randomized, double-blind study, for example, 51 postmenopausal women with osteopenia were treated with alendronate or placebo and followed over a 2-

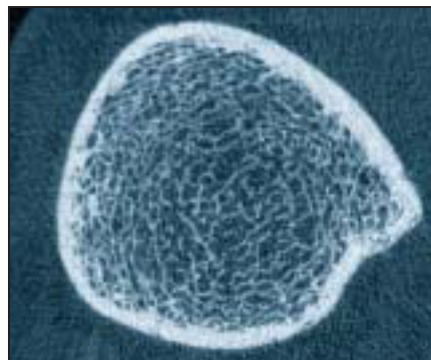
year period by 3T MRI of the radius, tibia and femur, hr-pQCT of the radius and tibia, and dual x-ray absorptiometry measures of bone mineral density. Both 3T MRI and hr-pQCT results for trabecular bone showed moderate but significant correlation with bone density as a reference, even though there was a twofold to fourfold difference between 3T MRI and hr-pQCT in parameter values such as trabecular number, thickness, or separation (J. Bone Miner. Res. 2008;23:463-74).

In earlier studies, hrMRI showed that salmon-calcitonin nasal spray helped maintain trabecular microarchitecture, compared with placebo (J. Bone Miner. Res. 2005;20:1548-61) and that testosterone replacement may improve trabecular architecture in hypogonadal men (J. Clin. Endocrinol. Metab. 2003;88:1497-502).

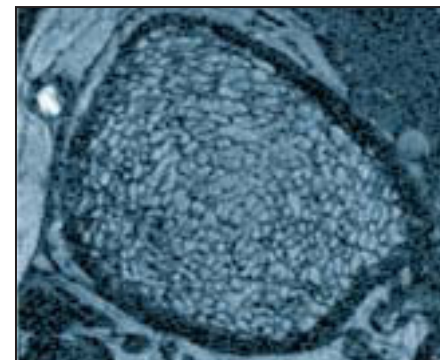
Another study of 106 postmenopausal women found no difference in conventional bone mineral density measurements between the 35 women with a history of fractures and the fracture-free women in the rest of the cohort, but hr-pQCT imaging showed significant differences in trabecular structure (J. Clin. Endocrinol. Metab. 2005;90:6508-15).

Multidetector CT was used in a separate study showing significant increases in trabecular microstructure in 65 postmenopausal women who were treated for 12 months with teriparatide for osteoporosis (J. Bone Miner. Res. 2007;22:1426-33).

For cortical bone imaging, a newer area of research, two 2008 studies using hr-pQCT showed substantial differences between postmenopausal women with



Trabecular and cortical bone architecture of the distal tibia is seen here with hr-pQCT.



High-resolution 3T MRI of the distal tibia shows trabecular and cortical bone architecture.

IMAGES COURTESY DR. THOMAS M. LINK

hip or wrist fractures, compared with fracture-free women, said Dr. Link, professor of radiology at the University of California, San Francisco.

Both hrMRI and hr-pQCT are being used experimentally to assess cortical bone porosity, which affects bone stability. One recent study using hr-pQCT found significant differences between normal premenopausal women, normal postmenopausal women, and postmenopausal women with renal osteodystrophy. "This is quite exciting to see these changes in cortical bone porosity. We don't really know what they mean yet, but they're clearly associated with fracture risk," said Dr. Link, who has received research funding and support from Merck, which markets medication to treat osteoporosis.

MRI or hr-pQCT provide high spatial resolution and produce no or relatively little radiation, compared with high-radiation exposure from multidetector CT. Multidetector CT has the advantage of allowing imaging of more central skeletal

sites such as the spine or proximal femur, he said. The hr-pQCT scanners image only peripheral sites such as small areas of the radius and tibia and possibly the calcaneus, while hrMRI covers larger areas of the radius, tibia, and possibly the femur.

The CT techniques provide measures of bone densitometry. Although hrMRI gives no densitometric data, some studies suggest it may be used to analyze bone marrow composition through spectroscopy in order to assess bone stability. The three techniques appear to have similar rates of reproducibility.

MRI is expensive, and the time needed for imaging results in motion artifacts. In comparison, hr-pQCT requires a dedicated scanner. Although the exam time is shorter with hr-pQCT, motion artifacts remain a problem. Multidetector CT is widely available and requires less time for a scan. Postimage processing requires very sophisticated techniques with MRI, but also is technically challenging with hr-pQCT. ■

## TZD Use Is Linked to Increased Risk of Bone Fracture

BY MITCHEL L. ZOLER

NEW YORK — Treatment with a thiazolidinedione, either pioglitazone or rosiglitazone, was linked to an increased rate of bone fractures, particularly in women, in several recently published reports.

Although a definitive link between these drugs and an increased fracture risk has not yet been proved, the evidence amassed so far is suggestive enough to prompt caution in the treatment of patients with a thiazolidinedione (TZD), Dr. Robert G. Josse said at a meeting sponsored by the American Diabetes Association.

"In those with a higher fracture risk, consider other hypoglycemic therapy," advised Dr. Josse, professor of medicine and nutritional sciences at the University of Toronto and medical director of the department of medicine at the osteoporosis center at St. Michael's Hospital in Toronto. In addition, "if us-

ing a TZD, consider therapy to prevent TZD-induced osteoporosis." Standard therapies for osteoporosis are effective in patients with diabetes—including those with diabetes who develop steroid-induced osteoporosis—but no data now exist on the efficacy of antiosteoporosis treatments for countering the possible effects of TZDs, he noted.

Reasonable steps to reduce the fracture risk in patients who must take a TZD include optimizing calcium intake and the supply of vitamin D, encouraging adequate exercise, and taking precautions to prevent falls. Administration of antiresorptive drugs, such as raloxifene and the bisphosphonates, seems to be effective in patients with diabetes, but the effects of bone anabolic drugs such as teriparatide in these patients isn't known.

The idea that treatment with pioglitazone (Actos) or rosiglitazone (Avandia) may cause osteoporosis and produce an increased rate of bone fractures is biologically plausible, and has been suggested in the results from some studies.

Perhaps the most persuasive evidence so far is a meta-analysis



The evidence so far is suggestive enough to prompt caution in the treatment of patients with a thiazolidinedione.

DR. JOSSE

published in January that compiled adverse-event data from 10 randomized, controlled studies with a total of more than 13,000 patients, and also reviewed two observational studies with a total of more than 31,000 patients (Can. Med. Ass. J. 2009;180:32-9). In the 10

randomized trials, patients treated with a TZD had a statistically significant 45% increased risk for bone fracture, compared with patients in the control groups. When the analysis broke the study population down by sex, a statistically significant 2.2-fold increased fracture risk was seen in women treated with a TZD, but absolutely no increased risk was seen in men. Additional analysis by sex showed that, in women, TZD treatment was linked with significant reductions of bone mineral density in the lumbar spine and hip. The two observational studies also showed a significant link between TZD use and fracture risk in women, but not in men.

The two short-term, randomized studies included a study with 50 healthy postmenopausal women without osteoporosis or diabetes who were randomized to treatment with 8 mg rosiglitazone daily or placebo for 14 weeks. Despite the brief period

of treatment, the women in the rosiglitazone-treated group had a statistically significant reduction in their total hip bone mineral density, compared with the placebo group (J. Clin. Endocrinol. Metab. 2007;92:1305-10). A second study, published last May, randomized 30 postmenopausal women with polycystic ovary syndrome but without diabetes to treatment with either 30 mg pioglitazone daily or placebo. After 16 weeks, the women treated with pioglitazone had significantly lower lumbar spine and femoral neck density, compared with the controls (J. Clin. Endocrinol. Metab. 2008;93:1696-701). The TZD-treated women also showed significantly decreased blood levels of bone-turnover hormones and enzymes.

Dr. Josse reported receiving research support from, and serving on the speakers bureau and advisory panel for, several companies including Amgen Inc., Eli Lilly & Co., Procter & Gamble Co., and Sanofi-Aventis. ■