

Radiation Helpful for Some Melanoma Patients

Consider treatment for those with recurrent disease, large nodal size, or extracapsular extension.

BY DOUG BRUNK
San Diego Bureau

CORONADO, CALIF. — Radiation therapy is underused as a treatment for malignant melanoma, Dr. Ray Lin said at a melanoma update sponsored by the Scripps Clinic.

"The reasons are traced back to in vitro studies which showed that melanomas are more radioresistant," explained Dr. Lin of the department of radiation oncology at the clinic in La Jolla, Calif.

Most studies actually show that malignant melanoma responds to high doses of radiation per fraction, but this approach raises concern about late effects of radiation toxicity.

"The more fractionated the treatments are, the lower the risk for late toxicity," he said. "For instance, delivering higher doses of radiation in fewer fractions for a tumor near the spinal cord could lead to late spinal cord injury. For skin cancers, late tissue injury usually involves the soft tissues, bones, and normal structures underneath the skin irradiated."

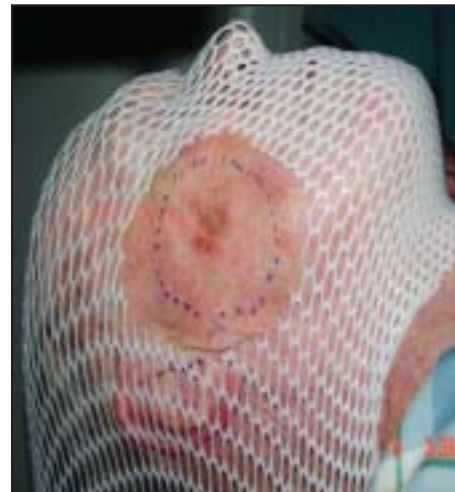
One recent study demonstrated that melanoma patients treated with conventional fractionation had similar rates of local control, compared with those who were treated with hypofractionation (*Int. J. Radiat. Oncol. Biol. Phys.* 2006;66:1051-5).

Results from this and other studies "really take out the concern for late toxicity," Dr. Lin said. "Approximately 17% of patients with locoregional disease and 51% of patients with metastatic disease will benefit from radiation therapy."

Current studies show a wide range of response to radiation therapy, sometimes with similar sensitivities to other epithelial cancers. Most melanomas "are easily seen and have a high chance of cure with surgical excision alone," he said. "Locally advanced melanomas have a propensity for local and distant recurrences with surgery alone, and local control is associated with longer survival."

One use of radiation therapy in melanoma includes treating lentigo maligna, particularly for large cancers on the face, which could be difficult to remove surgically. Radiation therapy is delivered for 3 weeks, and it takes 18-24 months before most of the pigmentation resolves. Recurrences can be easily salvaged with surgery.

Radiation therapy may also be indicat-



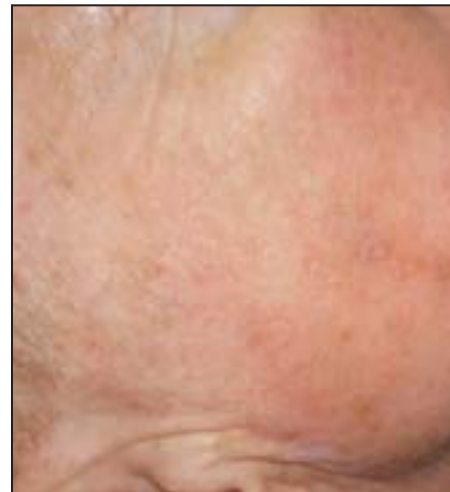This patient with lentigo maligna is about to begin radiation therapy.

ed after biopsy of primary melanoma for high-risk patients, including those with close or positive margins, rapid or multiple recurrences, extensive perineural invasion, and large primary tumors.

For patients with stage I-III melanoma, surgery alone without radiation therapy "is usually fine, because these patients have a higher risk of distant relapse," Dr. Lin said. "However, for these patients it's important to assess local failure risk, including margin status, head and neck site, thickness of 4 cm or greater, and history of recurrence or desmoplasia."

One trial of radiation therapy in 174 patients with head and neck melanoma found that the 5-year local regional control was 88%. The patients ranged in age from 16 to 89 years and they received a total of 30 Gy of hypofractionated radiotherapy delivered in five fractions over 2.5 weeks (*Int. J. Radiat. Oncol. Biol. Phys.* 1994;30:795-8).

The 5-year survival rate correlated with



Three weeks after therapy, the treated area is back to normal coloration.

lymph node status. Only 23% of patients who had more than three involved lymph nodes survived, while 39% of those who had one to three involved lymph nodes survived.

The 5-year survival rate also correlated with the thickness of the tumor. The rate of survival in patients with a tumor up to 1.5 mm thick was 100%, but it dropped to 72% for those with tumors 1.5-4 mm thick and 30% for those with tumors greater than 4 mm thick.

"Unfortunately, most patients with high-risk features have poor survival," Dr. Lin commented. "There is some controversy on whether there is a clear survival advantage with radiation therapy, but [it] should be considered for certain high-risk features," he suggested. These include melanoma patients with recurrent disease, large nodal size (3 cm or greater), multiple lymph node involvement, and extracapsular extension.

Radiation therapy also is offered to stage IV melanoma patients who have brain, bone, or skin metastases. It is used on brain metastases to prevent further growth, shrink tumors, and control neurologic defects, and on bone metastases to control pain and prevent pathologic fracture. "After several treatments, patients usually experience significant pain relief," he said.

Complete response in patients with primary malignant melanoma ranges from 14% to 57%.

Sequelae from skin irradiation "depend on size, dose, and fractionation scheme," Dr. Lin said. "Usually there's some pruritus, hair loss, and desquamation. Late reactions may include telangiectasia, hyperpigmentation, hypopigmentation, and local hair loss." ■

Mohs for Melanoma Limited to 1 mm

BY TIMOTHY F. KIRN
Sacramento Bureau

SAN DIEGO — The use of the Mohs technique for melanoma is probably limited to those with a Breslow thickness of 1 mm, because in melanomas thicker than that, sentinel node biopsy takes precedence, Dr. Kenneth Gross said at a meeting sponsored by the American Society for Mohs Surgery.

Much of the important work establishing the safety of the Mohs approach in melanoma has been done by Dr. John Zitelli of Pittsburgh, said Dr. Gross, who practices surgical dermatology in San Diego.

In studies with 5-year follow-up on patients, Dr. Zitelli has shown that recurrence rates and mortality using a Mohs technique are equivalent to, or better than, those of historical controls treated with conventional surgery using recommended margins.

However, for those melanomas

with a Breslow thickness of between 1 mm and 3.5 mm, surgical oncologists like to know the results of a sentinel node biopsy, Dr. Gross noted. The reason they do is that the Multicenter Selective Lymphadenectomy Trial showed that this could be very important in intermediate thickness lesions. Five-year survival among those individuals in the trial who were found to have positive nodes was 72% when patients had immediate lymphadenectomy, but only 52% when the lymphadenectomy was delayed (*N. Engl. J. Med.* 2006;355:1307-17).

Dr. Gross said when he performs Mohs on a patient with melanoma he is careful to obtain a detailed consent from the patient. He also uses a Wood's lamp and magnification before and during the procedure to be sure he is seeing all it is possible to see.

When removing and sectioning a melanoma, Dr. Zitelli often takes the tumor plus about a 3-mm margin in the first stage, and

he takes the specimen all the way down to the fat, Dr. Gross said.

Dr. Gross said he takes sections slightly larger than standard, and once he believes he has a clear margin, he removes another 4-5 mm which is sent for permanent sectioning. He also has a pathologist reading his slides with him.

What constitutes a clear margin has been defined by Dr. Zitelli as a margin that does not have three or more unusual melanocytes or melanocytes above the dermal-epidermal junction.

Dr. Gross said that he often uses Mohs zinc chloride paste, applying the escharotic agent to the lesion the night before the surgery is to be performed, and that he also often uses the MART-1 (melanoma antigen recognized by T-cells 1 staining) immunostain.

Because he takes a fairly large margin around the melanoma lesion when he makes his first Mohs excision, 90% of his melanoma cases are cleared on the first stage, Dr. Gross said. ■

Selection of Devices to Implant May be Aided by Patch Testing

WASHINGTON — Presurgical patch testing may prompt surgeons to change devices to prevent allergic reactions in patients, Kurtis Reed said at the annual meeting of the American Contact Dermatitis Society. To evaluate the clinical impact of a positive patch test before and after surgery, Mr. Reed, a third-year medical student at Mayo Medical School, Rochester, Minn., and his colleagues reviewed data from 22 patients who were patch tested before receiving an orthopedic device or pacemaker and 22 patients who were referred for patch testing after receiving their devices.

Five of the 22 patients who were tested prior to surgery tested positive to at least one component of the prospective device. In four of the five cases, the surgeon changed the device. In the fifth case, the

surgeon proceeded as planned because the odds of an adverse reaction were low, and that patient has reported no complications, Mr. Reed said.

The surgeon proceeded as planned in 16 of the 17 patients whose patch tests were negative. The device was changed in one case based on the patient's allergy history, he said.

By contrast, the clinical value of patch testing was unclear in patients who were referred following surgery. Reasons for referral included 13 cases of unexplained rash at the device site, 8 cases of chronic joint pain, and 1 case of joint loosening.

Only 1 of the 22 patients (one of the cases of unexplained rash) tested positive to an orthopedic device component, but the device could not be confirmed as the source of the rash, Mr. Reed noted.

—Heidi Splete