

# Chest Radiographs May Be Overused in Severe CAP

BY BRUCE K. DIXON  
Chicago Bureau

CHICAGO — Routine follow-up chest radiography may not be appropriate for patients with severe community-acquired pneumonia who clinically respond to initial antibiotic therapy, according to a multicenter study presented at the Interscience Conference on Antimicrobial Agents and Chemotherapy.

"In addition, chest radiographs obtained prior to hospital discharge, as advised by the American Thoracic Society in their 1993 guideline, seem to be unnecessary," according to the authors, whose study was published shortly after the conference (*Clin. Infect. Dis.* 2007;45:983-91).

The use of follow-up chest x-rays of patients hospitalized for severe community-acquired pneumonia (CAP) has become common clinical practice, and the absence of guidelines leaves physicians reliant on recommendations derived from grade D evidence, said lead author and presenter Dr. Anke H.W. Bruns, a research fellow in the Department of Internal Medicine and Infectious Diseases at the University Medical Center Utrecht in the Netherlands. "The timing of those follow-up chest x-rays is difficult, in part because we know little about time-to-resolution of findings related to infection on a film. So, follow-up radiographs probably are ordered unnecessarily."

To address this question, the researchers studied 288 patients enrolled between July 2000 and June 2003 from a prospective randomized trial on the cost-effectiveness of an early switch from parenteral to oral therapy for severe CAP.

The mean age of the patients was 70 years, and two-thirds were men. The mean pneumonia severity index at admission was 113, half the patients had comorbidities, and virtually all patients had been placed on a  $\beta$ -lactam (82%) or  $\beta$ -lactam-macrolide combination (14%).

Of the 140 cases with proven microbiological etiology, 44% had *Streptococcus pneumoniae*. Another 20% had atypical pathogens, including *Mycoplasma pneumoniae*, *Chlamydia pneumoniae*, and *Legionella pneumophila*. The remaining 36% were in-

fectured with unidentified pathogens, Dr. Bruns explained.

Patients were observed for a maximum of 28 days, and those who were still hospitalized on day 7 underwent follow-up chest radiography. After hospital discharge, all patients were asked to return to the outpatient clinic for clinical evaluation, blood chemistry analysis, and a chest radiograph at day 28. Scores for clinical improvement on day 7 and for clinical cure on day 28 were calculated for each patient. The cu-

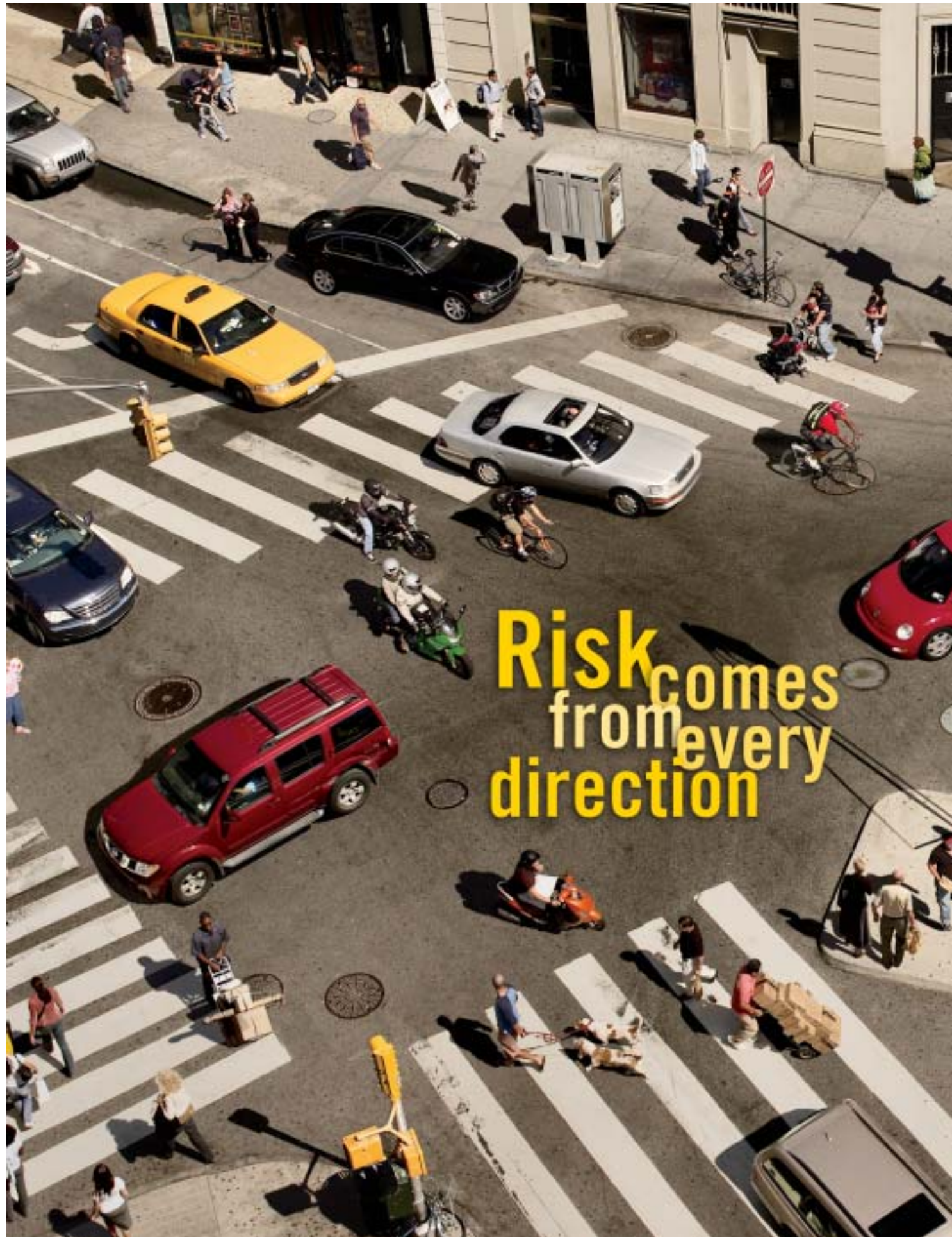
mulative dropout rate for radiographs was 21% at day 7 and 32% at day 28.

Radiologists reviewed the radiographs for the presence of pulmonary infiltrates, pleural fluid, atelectasis, pulmonary edema, and other findings. During follow-up, clearance of pulmonary infiltrates and resolution of chest radiograph abnormalities were established.

At 1 week, 33% of the patients had clearance of pulmonary infiltrates, and only 25% demonstrated resolution of

chest radiograph abnormalities. At 1 month, 62% of the patients had clearance of infiltrates, and 53% had resolution of radiograph abnormalities. Resolution occurred more slowly in patients with proven *S. pneumoniae* pneumonia, the investigators reported.

Resolution of radiograph abnormalities lagged behind clinical improvement: At 1 week, clinical improvement was observed in more than half of patients, while resolution of chest radiograph abnormal-



## Database for RSV

A redesigned Web site from the Centers for Disease Control and Prevention now provides data that has been gathered on respiratory syncytial virus (RSV) in the U.S., thus allowing parents and physicians to track the locations of virus outbreaks in their own state and region. The site is located at [www.cdc.gov/surveillance/nrvss](http://www.cdc.gov/surveillance/nrvss).