

# Shock May Dominate Presentation of Kawasaki

BY BRUCE JANCIN

VAIL, Colo. — Patients with severe Kawasaki disease can present in shock.

This was the thrust of two recent studies of severe Kawasaki disease conducted in Denver and San Diego. In both studies, patients with Kawasaki disease who were ill enough to be admitted to the ICU were less likely to have an admitting diagnosis of Kawasaki disease than were less severely ill patients admitted to the wards, Dr. Marsha Anderson said at a conference on pediatric infectious diseases sponsored by the Children's Hospital, Denver.

Severe Kawasaki disease presenting with shock was often mistaken for septic or toxic shock. As a result, ICU patients with Kawasaki disease were treated with intravenous immunoglobulin

(IVIG)—the first-line therapy—a median of 2 days later than were Kawasaki disease patients on the general wards.

"I think we have to consider Kawasaki disease in our differential diagnosis in patients who present in shock," said Dr. Anderson of the University of Colorado, Denver.

In the Denver study, on which she was a coauthor, patients with severe Kawasaki disease as defined by ICU admission constituted 3.3% of a consecutive series of 423 Kawasaki disease patients (Pediatrics 2008;122:e786-90).

In San Diego, severe Kawasaki disease was defined as systolic hypotension un-

responsive to fluids, with resultant ICU admission. Severely affected patients accounted for 7% of 187 consecutive Kawasaki disease patients (Pediatrics 2009;123:e783-9).

**Severe Kawasaki often was mistaken for septic or toxic shock, which delayed the correct treatment.**


DR. ANDERSON

In both studies, patients with severe disease were significantly more likely to be female, with low platelet counts and high levels of C-reactive protein and band counts. In San Diego, patients with severe Kawasaki disease had significantly lower hemoglobin levels than did less ill patients; however, in Denver this wasn't the case. On the other hand, in Denver (but not San Diego) severely affected patients had low-

er serum albumin levels than did those on the wards. In both studies, patients with severe Kawasaki disease were more likely to have IVIG resistance and to require a second dose of IVIG or a second-line therapy. This was the case for 64% of ICU patients in Denver, compared with 5% on the wards. Similarly, 46% of severely affected patients in San Diego were IVIG resistant, as were 18% of those on the wards.

Coronary artery abnormalities, mitral regurgitation, and left ventricular systolic dysfunction were significantly more common in patients with severe Kawasaki disease than in controls in the San Diego study.

In Denver, there was a strong trend for more coronary artery abnormalities in the ICU patients, but it didn't quite achieve statistical significance. ■



# High Suspicion Can Be Key to Pediatric Lupus Diagnosis

BY SUSAN LONDON

SEATTLE — The clinical features of lupus in children may be subtle and easily overlooked, Dr. David Sherry said.

Vasculitis, the pathologic hallmark of lupus, can produce a challenging clinical picture with a wide differential diagnosis, noted Dr. Sherry, who is a pediatric rheumatologist at the Children's Hospital of Philadelphia.

When a child presents who is sick and is not getting better, who continues to have a fever, to lose weight, to have an elevated sedimentation rate, and the "virus" still isn't going away, it's time to consider the diagnosis of a vasculitic condition, he commented at a meeting sponsored by the American Academy of Pediatrics.

Multiorgan disease can also be a tip-off that a child has vasculitis. "Why should a kid be peeing blood and coughing up blood?" he said. "That's two different organs."

Seeing an unusual patient for the symptom, such as a teenager with a heart attack, also should raise a suspicion of vasculitis.

Finally, there is the vasculitic rash, which can have a variety of appearances.

In describing the malar rash of lupus, textbooks often show photos of a vivid, contiguous red rash in the classic butterfly distribution on the cheeks and nose, according to Dr. Sherry. But what is actually seen clinically may instead mimic rosacea, wind chapping, sunburn, or even acne. In addition, in black children, the rash may be subtle and especially hard to identify.

Key features that can help identify a malar rash of lupus include its distribution (typically with crossing over the bridge of the nose and spreading onto the cheeks) and a well-defined border between the affected skin and normal skin. Children with malar rashes usually, but not always, have other symptoms or clinical findings, too.

Additional clues to the presence of lupus can often be found on parts of the body that are easily overlooked on examination, according to Dr. Sherry. For example, children may have a vasculitic rash on their hands or feet, or a painless ulcer on their hard palate. "You need to look up to see the hard palate," he pointed out. "If you look at the back of the throat, you will miss this."

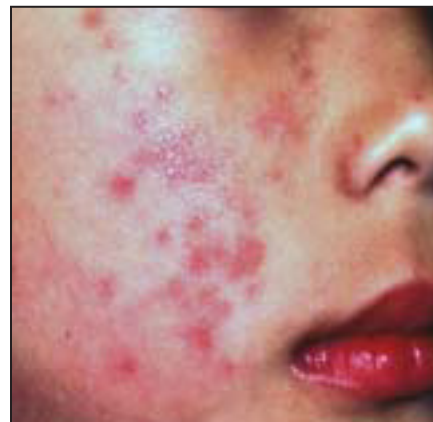The discoid rash of lupus is less common and causes crusts or scabs that scar. "If you lift up these crusts or scabs, you see what's called carpet tacking—little pinpoint of bleeding underneath," he said. "Discoid lupus especially likes the helix of the ear."

Children also may have so-called lupus hairs, which are fragile and break easily. "You pull on their hair, you get three, four, or five hairs, even if they just brushed it," he explained. The breakage is accompanied by the presence of short hairs resulting from regrowth.

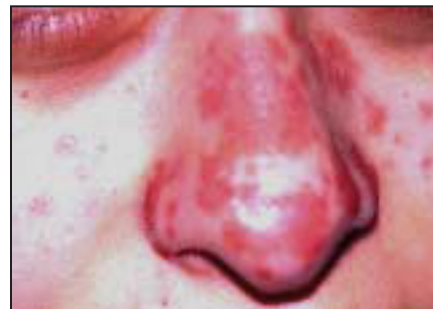When lupus is first suspected in children, Dr. Sherry recommended that physicians obtain a complete blood cell count, an erythrocyte sedimentation rate (ESR), a C-reactive protein (CRP) level, a urinalysis, a comprehensive metabolic panel, and an antinuclear antibody (ANA) titer. Lupus has the unique property of producing a high ESR and a normal CRP level—unless the child also has an infection.

An ANA panel can be deferred unless suspicion of the disease is high, he said. Related tests should be guided by symptoms, such as rheumatoid factor assessment in a child with pronounced joint symptoms, creatine kinase assessment in a child with muscle weakness, and coagulation studies in a child with deep vein thrombosis.

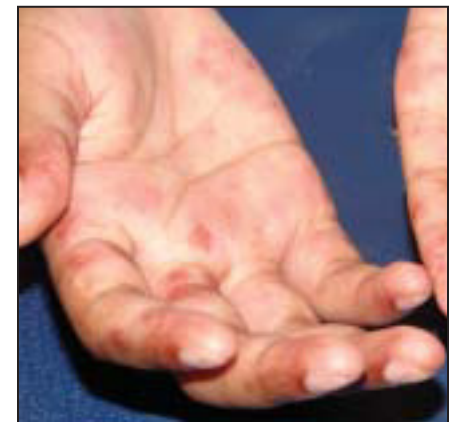Dr. Sherry noted that to be classified as having lupus, children must meet at least 4 of the 11 clinical and laboratory criteria of the American College of Rheumatology, of which a positive ANA titer is merely one.



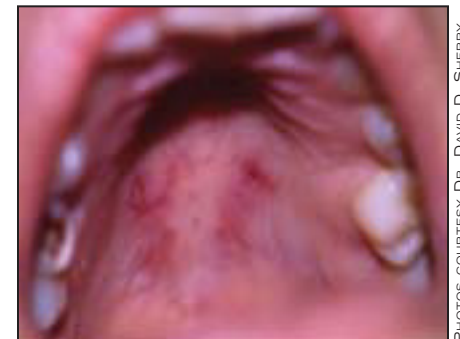**Spotty malar rash may mimic rosacea instead of having the butterfly shape.**



**The classic malar rash crosses the nose of the young affected patient.**



**Vasculitic rash on the hands may be overlooked in a child with lupus.**



**Painless oral ulcer of the hard palate may be the only outward sign of lupus.**

In fact, he cautioned, 12%-20% of normal children have a positive ANA titer.

If the ANA result is positive but at a titer of only 1:80 or 1:160, the child is unlikely to have lupus; if it is higher, the ANA panel should be done. "If the panel is negative, you can cool your jets and cool the mom's jets," he said. "The child doesn't have lupus."

Management in children with lupus, in addition to antirheumatic therapy, includes counseling about sun protection because of photosensitivity, antihypertensive therapy when blood pressure is elevated, and attention to calcium and vitamin D status, both because steroid therapy adversely affects bone health and because lower levels of vitamin D have been linked to increased disease activity. "We give these kids calcium and,

if they are low in vitamin D, we certainly can give them that too," he said.

"More than 90% of our kids do very well and have long-term survival." In fact, "now that we are saving these kids, we have to worry about the side effects of treatment." Hence, where possible, treatment strategies have been modified to reduce long-term toxicity.

Importantly, he concluded, as children with lupus increasingly survive into adulthood, their providers will need to be aware of risks related to the disease and its treatment that may emerge over time, including hyperlipidemia, heart attack, and complicated pregnancy.

Dr. Sherry reported that he had no conflicts of interest in association with his presentation. ■