

Study: 5 Years of Anastrozole More Effective Than Tamoxifen in Breast Ca

BY BRUCE JANCIN
Denver Bureau

SAN ANTONIO — Five years of the aromatase inhibitor anastrozole has now replaced tamoxifen as the endocrine therapy of choice for primary adjuvant therapy of women with hormone receptor-positive early-stage breast cancer, Anthony Howell, M.D., said at a breast cancer symposium sponsored by the Cancer Therapy and Research Center.

He presented the updated results of the Arimidex, Tamoxifen Alone or in Combination (ATAC) trial, which at a mean follow-up of 68 months continues to show superior efficacy for anastrozole (Arimidex), as has consistently been the case since the first year of follow-up.

ATAC is an AstraZeneca-sponsored, randomized, double-blind trial for which data are available on 9,366 postmenopausal women with early-stage breast cancer treated at 381 sites in 21 countries. Participants were randomized to 5 years of tamoxifen, anastrozole, or both, although the combination treatment arm was halted early because of clearly inferior results, explained Dr. Howell of the University of Manchester, England.

At 68 months, 16% of hormone receptor-positive patients in the anastrozole arm had died or developed recurrent breast cancer, compared with 19% of tamoxifen-treated patients. The anastrozole group also had significant relative advantages of 26% in time to local recurrence,

16% in time to distant recurrence, and a 53% lower rate of contralateral breast cancer. Among hormone receptor-positive patients, there were 152 breast cancer deaths in the anastrozole arm and 172 in the tamoxifen arm, a trend that didn't reach significance but may do so with several more years of follow-up, he said.

The incidences of endometrial cancer, thromboembolic events, and ischemic stroke were significantly lower in the anastrozole group. However, the rates of osteoporosis, fractures, and arthralgias



The incidences of endometrial cancer and ischemic stroke were lower in the anastrozole group.

DR. HOWELL

were significantly greater with anastrozole than with tamoxifen.

Despite Dr. Howell's call for anastrozole to be considered the agent of choice for first-line initial endocrine therapy, many oncologists indicated that they—and large numbers of their patients—remain unwilling to do so routinely for now.

That reservation is reflected in a recent American Society of Clinical Oncology technology assessment, which advised that adjuvant therapy for postmenopausal women with hormone receptor-positive breast cancer "should include an aro-

matase inhibitor in order to lower the risk of tumor recurrence," without specifying whether the agent should be used as initial therapy or after tamoxifen. The ASCO report cited as reservations the still limited data regarding the late consequences of aromatase inhibitor therapy and how best to utilize these agents.

ASCO took a conservative stance—and appropriately so, Hope S. Rugo, M.D., said at a satellite symposium sponsored by Merck and Co.

In her own practice, she favors using an aromatase inhibitor from the beginning in women at increased risk for osteoporosis or thromboembolism, and in those with higher-risk breast cancer as defined by a human epidermal growth factor receptor 2 (HER2)-positive and/or estrogen receptor-positive/progesterone receptor-negative (ER+/PgR-) tumor.

"For the average woman, though, I do tend to think that maybe a couple of years of tamoxifen isn't a bad thing. I discuss the data with each patient. And I have to say, many patients are still very enthusiastic about taking tamoxifen. It's kind of gone in reverse: Whereas before nobody wanted to take tamoxifen and everybody thought it was an evil drug, now many people are saying, 'No, I want to take tamoxifen; I'm worried about the long-term side effects of the aromatase inhibitors,'" said Dr. Rugo, codirector of the breast oncology clinical trials program at the University of California, San Francisco, Comprehensive Cancer Center. ■

Regression of LSIL High in Young Women

BY CHRISTINE KILGORE
Contributing Writer

Most low-grade abnormalities on Pap smears spontaneously regressed within 36 months in a cohort study of adolescents and young women, and study investigators say the finding lends support to the practice of monitoring these lesions with regular cytology.

Colposcopy is "unwarranted and leads to unnecessary intervention, morbidity, and cost," said Anna-Barbara Moscicki, M.D., and her associates at the University of California, San Francisco.

Of 187 patients aged 13-22 years who developed low-grade squamous intraepithelial lesions (LSIL), 61% were free of LSIL after 1 year, and 91% were free of LSIL at 3 years' follow-up.

Progression to high-grade disease occurred in 3% of the patients (Lancet 2004;364:1678-83).

The patients were part of a larger 10-year longitudinal study of human papilloma virus (HPV) infection.

The women were examined every 4 months by cytology, colposcopy, and HPV DNA status. Both prevalent and incident LSIL cases were included in the study, and regression was defined as

having at least three consecutive normal Pap smears.

The investigators found no associations between LSIL regression and HPV status at baseline (time of the first LSIL), age, sexual behavior, contraceptive use, substance or cigarette use, or incident sexually transmitted infection.

Nor did they find any significant differences in rates or timing of regression between patients who underwent biopsy and those who didn't, nor between patients whose LSIL status was confirmed by histology and those with LSIL confirmed by a normal biopsy.

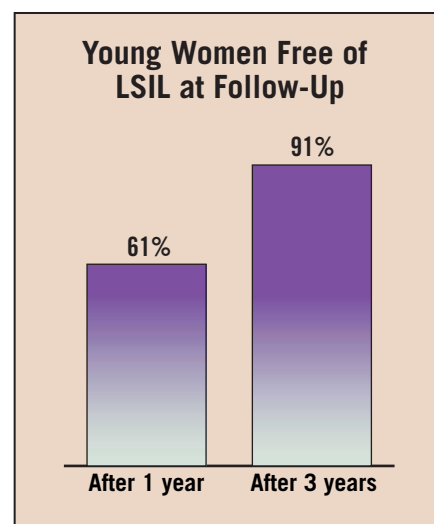
The investigators did find that patients' current HPV status—rather than their baseline status—was important. A negative HPV test at a subsequent visit "shows a good likelihood that LSIL has regressed," which suggests that HPV testing "could be helpful in monitoring LSIL," they said.

In addition, the findings suggest that the persistence of multiple HPV types slows rates of regression, but this needs to be examined more closely. More study is also needed to better define appropriate screening strategies, Dr. Moscicki and her associates said.

The findings are similar to those of a smaller study from Brazil, published in 2003 in the Journal of the National Can-

cer Institute, in which an estimated 92%-95% of cases regressed within 24 months, and 5%-6% progressed, according to Anne Szarewski and Peter Sasieni of Cancer Research UK.

"It is becoming increasingly clear that LSIL is a transient manifestation of HPV infection that will only rarely progress to HSIL," they wrote in an accompanying editorial (Lancet [in press]). "Since there is no point in treating LSIL in young women ... we see absolutely no role for colposcopy in adolescents as part of routine management," they concluded. ■



Autonomic Neuropathy Tied To Metronidazole

BY MICHELE G. SULLIVAN
Mid-Atlantic Bureau

SAVANNAH, GA. — Brief metronidazole treatment has been associated with a case of reversible autonomic neuropathy in a 15-year-old girl, Lisa Hobson-Webb, M.D., reported in a poster at the annual meeting of the American Association of Electrodiagnostic Medicine.

"This has never been reported in the literature," said Dr. Hobson-Webb of Wake Forest University, Winston-Salem, N.C. "There are cases of motor or sensory neuropathies after a large dose or an extended treatment period but not any reports of autonomic involvement."

Dr. Hobson-Webb presented a case study of a 15-year-old black girl who had taken a 3-day course of metronidazole for bacterial vaginitis; she had been unresponsive to a prior course of trimethoprim-sulfamethoxazole. Within 2 weeks of initiating metronidazole treatment, the girl developed such a severe, burning pain in the soles of her feet that she found relief only by keeping her feet and lower legs submerged in buckets of ice water at all times. "She was even sleeping like this," said Dr. Hobson-Webb.

The patient did not respond to pain medication, including oxycodone.

Examination revealed pitting edema and erythema to the mid-calf bilaterally. When removed from the ice water, the lower legs and feet rapidly became hot and erythematous. Her perception of temperature was reduced to the upper third of the shin bilaterally.

Deep tendon reflexes and strength were maintained. The patient's past medical history was unremarkable, and an examination showed no medical cause for her pain.

Nerve conduction studies showed reduced sensory nerve and compound muscle action potential. Reproducible sympathetic skin potential responses could not be obtained in the right foot, and only diminished responses were seen in the right hand.

"Based on these results, she was diagnosed with a severe sensorimotor and autonomic neuropathy, which was suspected to be a toxic reaction to the metronidazole," Dr. Hobson-Webb said at the meeting.

The patient was placed on gabapentin and carbamazepine for pain control, and improved over several weeks. After 3 months, her neuropathy had clinically resolved and conduction studies showed normalization of autonomic function.

The mechanism underlying neurotoxicity of metronidazole is unclear. However, Dr. Hobson-Webb said, it's thought to be related to decreased protein synthesis in the nerve.

"We think the drug binds to RNA and decreases protein synthesis. All the case reports on this showed neuropathies with axon loss in myelinated fibers. Why it affected only the autonomic system in this case is hard to say," she said. ■