

Preclinical Clues May Speed Parkinson's Diagnosis

BY NANCY WALSH
New York Bureau

NEW YORK — The recognition that Parkinson's disease is systemic, with identifiable prodromal features, is providing hope for early detection and possible early therapeutic intervention, Dr. Matthew Stern said at a meeting sponsored by the Parkinson's Disease Foundation.

"By the time the diagnosis [of Parkinson's disease] is made, the synuclein pathology is already fairly widespread, and much of the damage is done. We can't begin to think about preventing this damage until we've learned more about the preclinical phase," said Dr. Stern, the Parker Family Professor of Neurology and director of the Parkinson's disease and movement disorder center, University of Pennsylvania, Philadelphia. This early phase is called Parkinson's disease-associated risk syndrome (PARS). It is divided into stages:

► **Prephysiologic.** The first phase represents genetic predisposition. "There has been a tremendous amount of work in the last 10-15 years in identifying genes that are associated with familial Parkinson's disease, and by studying those we are finding some clues as to the mechanisms of nerve degeneration," said Dr. Stern.

► **Preclinical.** In this next phase, brain changes can be detected with neuroimaging, including single-photon emission computed tomography (SPECT) using ^{123}I -CIT as a dopamine transporter ligand, as well as with transcranial ultrasound.

► **Premotor.** During this phase, nonmotor features like olfactory dysfunction emerge.

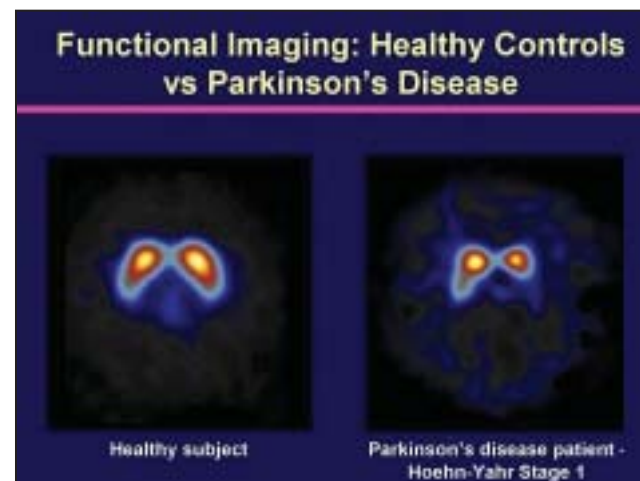► **Prediagnostic.** This final stage before a diagnosis is typically made is characterized by subtle progressive motor features.

"It is an increased understanding of the premotor phase that is changing our view of Parkinson's disease from a brain disorder to its being a systemic illness," he said. About 75% of patients with early Parkinson's disease (PD) do poorly on the UPSIT (University of Pennsylvania Smell Identification Test), which is a simple "scratch and sniff" test. The olfactory loss is significant and begins with the degeneration of extranigral neurons in the olfactory bulb and anterior olfactory nucleus (Lancet Neurol. 2006;5:235-45).

Dr. Stern and colleagues are investigating tools like UPSIT for early screening. In a study in which 361 asymptomatic first-degree relatives of PD patients were screened with UPSIT, 40 had olfactory defects. Over the next 2 years, four of the 40 developed PD, and an additional five showed significant declines on SPECT imaging, he said. No patients in a control cohort among the relatives who were normosmic at baseline developed PD. The study concluded idiopathic olfactory dysfunction in family members of PD patients is associated with at least a 10% increased risk of the disease (Ann. Neurol. 2004;56:173-81).

Moreover, the olfactory defect seems to be specific for PD, and is not a feature of other parkinsonian syndromes. "Also, importantly, if your olfaction is intact, it significantly lowers the risk of developing Parkinson's disease," he said.

Constipation is another common finding during premotor PD, as shown by the lon-



Imaging can detect asymptomatic neurologic changes. A SPECT scan of a patient with early PD shows reduced dopamine transporter binding on the as-yet unaffected side.

gitudinal Honolulu-Asia Aging Study. Late-life bowel movement frequency was assessed in 245 men aged 71-93 years. Though none had clinical PD, those with fewer bowel movements per day were more likely to have incidental Lewy bodies on post-mortem examinations of the substantia nigra and locus ceruleus (Mov. Disord. 2007;22:1581-6). The presence of incidental Lewy bodies is common in the disease prodrome, suggesting GI tract involvement may be an early PD feature, he said.

A further possible early marker is rapid eye movement (REM) sleep behavior disorder (RBD), in which patients thrashing and call out during REM sleep. In a study of 54 polysomnographically confirmed cases of RBD and 54 age- and sex-matched controls, olfactory impairment was ob-

served in 33 of the RBD group, versus 9 controls (Brain Res. Bull. 2006;70:386-90).

Subtle visual and cardiac abnormalities also have been identified in patients in the prodromal phase of PD, "which brings us to where we are today: in the process of designing the first large-scale screening study of PARS," at UPenn and the Institute for Neurodegenerative Disorders in New Haven, Conn., Dr. Stern said.

The study will recruit thousands of patients and first-degree relatives for olfactory function testing and SPECT neuroimaging. "We will also look at some of these other preclinical markers and follow the patients over time. If, in fact, we can identify several hundred individuals who go on to develop Parkinson's disease, the next phase of the study will be to actually test an intervention for slowing or perhaps even preventing the onset of disease. Ultimately, we hope this will enable us to think about Parkinson's disease in the way we think about heart disease, as a condition that can be diagnosed before it becomes clinically manifest and disabling."

Dr. Stern is a consultant for Novartis, Boehringer Ingelheim Pharmaceuticals Inc., Valeant Pharmaceuticals International, and Vernalis Pharmaceuticals Inc. ■

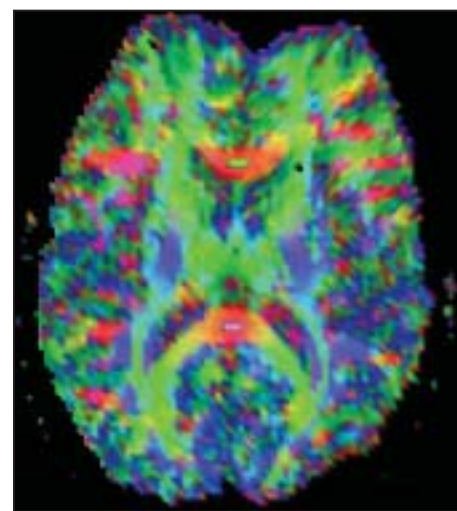
Diffusion Tensor Imaging Links White Matter Lesions, Poor Gait

CHICAGO — Poor gait and balance in the elderly correlated with white matter abnormalities in the genu of the corpus callosum, according to data presented at the American Society of Neuroradiology meeting. This was independent of age, arthritis, neuropathy, stroke, or brain atrophy.

Dr. Rafeeqe A. Bhadelia studied 166 elderly individuals (123 females, mean age 74 years). Using diffusion tensor imaging (DTI), he found highly significant links between fractional anisotropy (FA) in the genu of the corpus callosum and Tenetti scores of gait ($r = 0.31$) and balance ($r = 0.27$). There were no correlations between FA in the splenium of the corpus callosum and gait or balance scores. "This is not surprising," said Dr. Bhadelia, clinical operations chief in neuroradiology at Beth Israel Deaconess Medical Center, Boston. That's because the genu of the corpus callosum connects both frontal lobes; other studies show ties between gait, balance, and frontal lobe function.

MR DTI gives a detailed view of white matter fiber tracts and direction. FA reflects directional brain organization, which is influenced by the magnitude and orientation of white matter tracts.

Since gait and balance dysfunction can be caused by other factors (deconditioning,



On DTI, white matter fibers are green, red, or blue, depending on their direction.

arthritis, degenerative disease, stroke, etc.), a multivariate analysis was performed. Correlations between FA in the genu and gait ($r = 0.24$) and balance ($r = 0.30$) were still highly significant independent of age, gender, arthritis, neuropathy, stroke, or brain atrophy. DTI can therefore distinguish individuals whose balance problems derive from white matter dysfunction from those whose poor mobility has other causes.

—Amy Rothman Schonfeld

Caution Required in Use of Dopamine Agonists, Given Known Cardiac Risks

BY KATE JOHNSON
Montreal Bureau

Following warnings in Britain and the United States about the cardiac risks of dopamine agonists Parkinson's disease management, the British Society of Endocrinology recommends continuing the agents for the treatment of pituitary disorders, but with caution.

"Dopamine agonists remain the first-line agents for the management of hyperprolactinaemia and a useful adjunct in the management of acromegaly," noted a statement released Oct. 9 by the society. However, the lowest effective dose, or even withdrawal of dopamine agonists, should be considered when appropriate.

In response to studies showing an increased risk of mitral, tricuspid, and aortic valve regurgitation associated with the dopamine agonist pergolide, the Food and Drug Administration announced the voluntary withdrawal of pergolide products by manufacturers in March. The United Kingdom's regulatory agency imposed restrictions on the use of another dopamine agonist, cabergoline, in treating Parkinson's disease, but did not make reference to pituitary disease, noted the Society of Endocrinology statement.

While endocrine disorders require considerably lower doses of cabergoline compared with Parkinson's disease, endocrine patients are treated for longer durations. "As the published data indicate that the risk of valve disease relates to the cumulative dose, there is need for vigilance in patients with pituitary disease," it said. The society recommends screening echocardiograms for patients treated for longer durations, or with high doses of cabergoline. "Bromocriptine has not been implicated as a cause of cardiac fibrosis and remains an effective alternative to cabergoline," it advised.

The society stated its support for a recommendation in the British National Formulary from the Committee on Safety of Medicines. "Before starting treatment with these ergot derivatives it may be appropriate to measure the erythrocyte sedimentation rate and serum creatinine and to obtain a chest x-ray. Patients should be monitored for dyspnoea, persistent cough, chest pain, cardiac failure and abdominal pain or tenderness. If long-term treatment is expected, then lung-function tests may also be helpful."

To date, there are no reports of cardiac valve fibrosis tied to dopamine agonist treatment of endocrine disorders. ■