

## MASTER CLASS

## The Ultimate Microsurgical Procedure



CHARLES E. MILLER, M.D.

For this current excerpt of Master Class in Gynecologic Surgery, I have solicited the expertise of Dr. Antonio Rosario Gargiulo. Dr. Gargiulo is an assistant professor of obstetrics, gynecology, and reproductive biology at Harvard Medical School, Boston. He is also the director

of robotic surgery at the Center for Infertility and Reproductive Surgery at Brigham and Women's Hospital in Boston. After completing his subspecialty training in reproductive endocrinology and infertility at Brigham and Women's Hospital, Dr. Gargiulo rapidly built a busy reproductive surgery practice and has become a well-known expert in minimally invasive gynecologic surgery. Since 2007, Dr. Gargiulo has worked in robot-assisted reproductive surgery, and he performed the first robotic tubal anastomosis in New

England. It is a pleasure to watch such a young and gifted surgeon successfully and safely pushing the envelope in gynecologic robot-assisted microsurgery.

In 1999, Dr. Tommaso Falcone and his Cleveland Clinic team published the first report on robot-assisted tubal anastomosis. Using the Zeus robotic surgical system (Computer Motion Inc.), a far less sophisticated tool than the currently available da Vinci surgical system (Intuitive Surgical), the procedure lasted more than 5 hours.

Only a decade later, Dr. Martin Caillet presented a study on robot-assisted laparoscopic microsurgical tubal reanastomosis at the First European Symposium in Robotic Gynecological Surgery in Milan, Italy (Fertil. Steril. 2010;94:1844-7). In 97 patients who underwent robot-assisted microsurgical tubal reanastomosis, using the da Vinci surgical system, the overall pregnancy and birth rates were 71% and 62%, respectively. Not surprisingly, pregnancy and delivery rates were age related. In patients less than 35 years of age, 91% be-

came pregnant and 88% delivered. By the time a patient reached 36-39 years of age, pregnancy and delivery rates were 75% and 66%, respectively, while patients aged 40-42 years had a 50% pregnancy rate and 43.8% delivery rate. Importantly, the success rate is similar to rates reported in the most successful studies using the open microsurgical tubal reanastomosis technique.

Dr. Gargiulo will discuss his technique in this Gynecologic Surgery Master Class. ■

DR. MILLER is clinical associate professor at the University of Chicago and the University of Illinois at Chicago, immediate past president of the AAGL ([www.aagl.org](http://www.aagl.org)), and vice president of the International Society for Gynecologic Endoscopy. He is a reproductive endocrinologist in private practice in Schaumburg, Ill., and Naperville, Ill.; the director of minimally invasive gynecologic surgery at Lutheran General Hospital in Park Ridge, Ill.; and the medical editor of this column. Dr. Miller said he had no disclosures.



ANTONIO R. GARGIULO, M.D.

## Robot-Assisted Laparoscopic Tubal Reanastomosis

Surgery has an important role in the management of a patient's regret following tubal sterilization. While assisted reproductive technologies (ART)

have made great strides in efficacy and patient acceptability, reanastomosis of the tubal segments remains an attractive option for couples who have no other fertility issues and who find the risk of multiple pregnancies unacceptable or the extensive medical treatment of ART impractical or undesirable. The re-establishment of some degree of reproductive tract function also can have important psychological and/or religious implications.

As with all gynecologic operations, there has been a trend toward the development and diffusion of minimally invasive (laparoscopic) versions of the classic microsurgical tubal reanastomosis.

The biggest problem with conventional laparoscopic tubal reanastomosis is that it is one of the most technically challenging gynecologic operations ever conceived. Before the full introduction of robotics at our institution, I have observed the struggle of skilled reproductive surgeons with every step of this operation.

It is no surprise, therefore, that laparoscopic tubal reanastomosis was among the first gynecologic operations for which robotic assistance was described. In fact, a feasibility study for tubal reanastomosis using the da Vinci surgical system (Intuitive Surgical Inc.) was published in 2000 by Dr. Michel Degueldre and colleagues in Belgium – 5 years before the Food and Drug Administration approved this surgical platform for gynecologic applications in the United States (Fertil. Steril. 2000;74:1020-3).

Two more recent case series compared robot-assisted tubal reanastomosis performed with the da Vinci surgical system to the “gold standard” of microsurgical re-

anastomosis by minilaparotomy. In a 2007 case-control study by Dr. Allison K. Rodgers and colleagues at the Cleveland Clinic, surgical times were significantly longer, and costs were higher, for the robot compared with open surgery. Hospitalization times were not significantly different, as patients undergoing minilaparotomy were discharged home on the day of surgery. Pregnancy rates also were similar (61% for robotic vs. 79% for minilaparotomy), as were ectopic pregnancy rates. Complications occurred less frequently in the robotic group, however, and the return to normal activity was shorter in this group by approximately 1 week (Obstet. Gynecol. 2007;109:1375-80).

A 2008 prospective cohort study by Dr. Sejal P. Dharia Patel and colleagues confirmed that surgical times are significantly longer for the robot group. This team did not practice outpatient minilaparotomy as did Dr. Rodgers' team, and patients undergoing robot-assisted laparoscopic surgery were discharged on the day of surgery. Hence, hospitalization times were significantly shorter in the robot-assisted group. Time to recovery was also significantly shorter. Pregnancy rates (62.5% for robotic vs. 50% for open) and ectopic pregnancy rates were not significantly different. Cost per delivery was similar between the two

procedures (Fertil. Steril. 2008;90:1175-9).

These data indicate that robot-assisted tubal reanastomosis is safe and that its results are comparable to those obtained by classic tubal microsurgery performed by trained subspecialists. In terms of cost, it appears that even at the current high operating costs for the robot, open surgery is cost effective only if patients are sent home on the day of surgery, but not if they are admitted to the hospital.

Our robotic team performed the first successful robot-assisted tubal reanastomosis (with post-operative delivery) in New England in February 2007, and has since completely converted to the robotic approach. In our 4 years of experience, we have successfully completed approximately 350 robot-assisted reproductive surgeries, including robot-assisted tubal reanastomosis.

## Setup

As in all laparoscopic procedures, patient positioning and port placement are vital. Robotic tubal reanastomosis is performed with the patient in dorsal lithotomy position on Allen stirrups. Preferably, all four robotic arms of the da Vinci patient-side cart are employed. The camera port is always placed within the umbilicus. The three 8-mm da Vinci ports are positioned as follows: Port 1 is 8-10 cm to the right of the camera port, port 2 is 8-10 cm to the left of the camera port, and port 3 is 8-10 cm to the left of port 2 (Figure 1).

Ports 1 and 2 are safely located in an area of the abdominal wall that is between the epigastric vessels (superficial and inferior) and the superficial circumflex vessels, making injury of any of these vessels extremely unlikely. Port 3 is located in the left lateral portion of the anterior abdominal wall. In women with a smaller abdomen, it is necessary to slide port 3 about 15-30 degrees caudal to port 2, while keeping the distance of 8-10 cm.

Optimal placement of robotic port 3 is undoubtedly the most challenging of the three 8-mm ports. Due to the obtrusive nature of the da Vinci patient-side cart, external interference between robotic arms 2 and 3 and between robotic arm 3 and the patient arm support systems (such as arm toboggans) is common during the learning curve of this operation. Moreover, internal interference between instruments

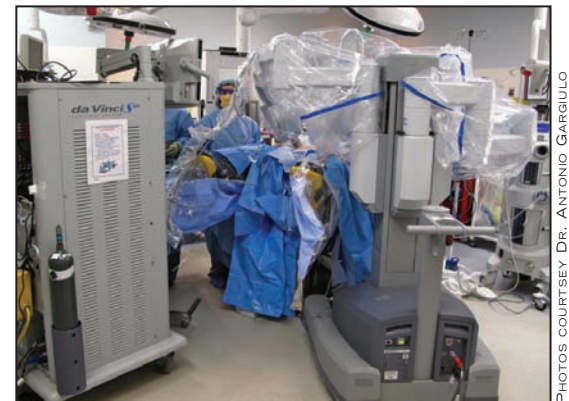

Figure 2 shows the laparoscopic tower with main computer at the foot of the operating table, and the patient-side cart with four robotic arms positioned lateral to the left Allen stirrup at a 45-degree angle to the longitudinal axis of the table.

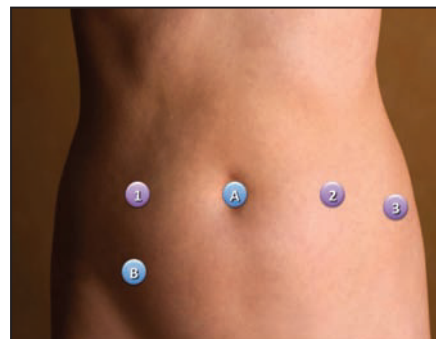


Figure 1 shows port placement for robot-assisted laparoscopic tubal reanastomosis. A and B are for disposable 12-mm trocars. 1, 2 and 3 are for da Vinci 8-mm nondisposable cannulas.

in port 2 and port 3 is also possible (particularly if the degree of caudal shift of port 3 is excessive and the instrument crosses the pelvis transversely).

One also should be cognizant of the fact that placement of robotic port 3 in the lateral abdominal wall introduces the risk of a rarely observed complication of gynecologic laparoscopy: injury of the deep circumflex artery and vein (stemming from the external iliac artery and vein). The course of these vessels is significantly lateral to that of the inferior as well as superficial epigastric vessels, and is usually lateral to typical port sites in gynecologic surgery. Therefore, at the end of any robotic case employing a third instrument port in such a lateral location, all port sites (particularly the site of robotic port 3)

Continued on following page

Continued from previous page

should be re-evaluated laparoscopically for possible occult vessel injury after removal of the trocars, since the release of tamponade from the trocar may allow reactivation of bleeding.

To help prevent injury to the deep circumflex vessels, we also recommend exclusive use of blunt nondisposable robotic trocar obturators (instead of semisharp single-use obturators) for all robot-assisted procedures employing lateral placement of the third instrument arm.

Placement of the bedside surgical assistant port in robotic surgery has traditionally been high in the abdominal wall at either side of the umbilicus. However, we feel strongly that for the main reproductive surgery applications (namely, tubal reanastomosis and uterine myomectomy), the assistant port must be placed in one of the lower quadrants. Such placement is based on considerations of patient safety, assistant safety, and surgical ergonomics.

Reproductive microsurgery is suture intensive, and needle exchanges should never occur beyond the visual field of the console surgeon; loss of a 6.0 or an 8.0 needle between loops of bowel in the upper abdomen can turn an elegant procedure into a surgical nightmare.

In terms of assistant safety, placement of the assistant port as the most lateral port (instead of between the robotic camera arm and a robotic instrument arm) avoids the possibility that the assistant's hand could be caught between colliding robotic arms.

Finally, placing the assistant port in the lower quadrant allows for an overall port configuration that is compatible with any advanced conventional laparoscopic maneuvers that may be needed during the case (approximating the "ultralateral" port placement previously described for conventional laparoscopy).

Our right lower quadrant assistant port is always a 12-mm port. Even though it may be tempting to use a small-caliber assistant port in a microsurgical case like this, we have experienced problems with micro-needles becoming stuck in the plastic valve of assistant ports smaller than 12 mm in diameter. Ideally, a valve-free assistant port should be used for these cases.

Tubal reanastomosis is often performed best with the uterus in anteversion, so it is essential to employ a manipulator that allows the uterus to be fixed in any desired position between 0 and 90 degrees of anteversion. Such a manipulator should provide reliable chromopertubation. Several nondisposable devices work perfectly for this application, such as the Hayden Uterine Manipulator (Hayden Medical Inc.), the Pelosi Uterine Manipulator (Apple Medical Corp.), the Valtchev Uterine Mobilizer (Conkin Surgical Instruments Ltd.), and the RUMI Uterine Manipulator (CooperSurgical Inc.).


In our experience, the degree of anteversion provided by these devices is more than enough to complete a reanastomosis procedure without the need for an assistant to actively support the manipulator. Clearly, a vaginal delineator is never required for this procedure, and all of these manipulators can be assembled

without the delineator.

As in all robot-assisted reproductive surgery techniques, we prefer lateral docking of the patient-side cart: This allows ample space for access to uterine positioning devices (Figure 2).

### Surgical Technique

Our philosophy in transitioning from the gold-standard minilaparotomy approach to the laparoscopic approach has been that three essential aspects of the operation could not be compromised: 1) Reanastomosis should occur over a tubal stent; 2)



**Figure 3 shows tips of microsurgical instruments for da Vinci robotic platforms. A. Black Diamond microforceps; B. Micro-bipolar cautery; C. Potts scissors; D. ProGrasp forceps.**

secure orientation should be achieved by applying more than two reanastomosis sutures per tube; and 3) the thinnest safely employable suture should be chosen. At this point, our surgical protocol for robot-assisted laparoscopic tubal reanastomosis is identical to the one that we used for minilaparotomy.

The robotic microinstruments employed in this operation are shown in Figure 3. The first stage of the procedure involves the preparation of the tubal stumps and the placement of the tubal stent (Figure 4, A and B). Typical instrument configurations for this stage include Potts scissors in port 1 or 2, micro-bipolar forceps in port 1 or 2, and ProGrasp forceps in port 3.

The choice of whether to use the Potts scissors in port 1 (right-sided) or port 2 (left-sided) depends on how important it is for the surgeon to have the opportunity to use two graspers at the same time for tissue manipulation. With the robotic arm configuration described here (one robotic port on the patient's right, and two robotic ports on the patient's left), the surgeon has to toggle between instruments 2 and 3 on the left side. By keeping the scissors on the left side, the surgeon can have the ProGrasp and the micro-bipolar forceps at his disposal at the same time when needed. This means, however, that most surgeons would have to operate the robotic Potts scissors with the nondominant hand. In our experience, the accuracy of operation is not compromised as long as the robotic console scaling setting is at very fine (1:3) or ultrafine (1:5) (the latter is preferred for this operation but is not available at this time on the latest version of the da Vinci system).

A dilute solution of vasopressin is injected into the mesosalpinx in order to decrease blood loss during mobilization of the proximal and distal tubal segments. Potts scissors and micro-bipolar graspers are used to mobilize tubal segments and

to deperitonealize the edges of the mesosalpinx. Even though we have bipolar electrocautery (micro-bipolar forceps) at our disposal, we employ it sparingly to avoid occult thermal damage to the tubal epithelium.

A graduated-tip ERCP (endoscopic retrograde cholangiopancreatography) cannula (Contour 3-4-5 Tip ERCP Cannula, Boston Scientific, Natick, Mass.) is inserted through the fimbriated end of the distal tubal segment; it exits through the newly opened proximal lumen of this distal segment and enters the newly created opening of the proximal tubal segment. This stent provides anatomic orientation and helps to identify the tubal lumen.

Preparation of the tubal edges and placement of the ERCP cannula are performed with the assistance of chromopertubation. It is particularly important to note abundant spillage of indigo carmine solution when the proximal tubal stump is opened.

From this point in the operation, the main role of the robotic ProGrasp operated through port 3 is to hold the ERCP cannula in place, thereby providing a steady and reliable stent.

The second stage of the procedure involves the suturing of the proximal and distal tubal stumps together (Figure 4, B and C). This stage employs Black Diamond forceps in ports 1 and 2 and keeps the ProGrasp forceps in port 3. All sutures are passed on 1/2-inch by 1/2-inch surgical patties to minimize the risk of dropping a needle. The mesosalpinx is reapproximated using figure-of-eight sutures of 6-0 Vicryl. We leave the suture closest to the tube untied until a later time, so as to not completely eliminate the gap between the segments: This facilitates placement of the tubal sutures. Four sutures of 7-0 Vicryl or 8-0 Prolene are used for the reanastomosis of the tubal lumen at 12 o'clock, 3 o'clock, 6 o'clock, and 9 o'clock. Our preferred approach is to place three untied tubal sutures before starting to tie the knots, so that perfect alignment can be achieved. The fourth tubal suture, which tends to be the suture on the lateral aspect of the tube, is placed after the other three are already tied. Occasionally, serosal sutures are necessary to reinforce the reanastomosis line, due to retraction of the serosa.

Once the reapproximation is complete, the ERCP catheter is removed from the tube and immediately removed from the abdominal cavity, and prompt fill and spill of indigo carmine is observed, indicating patency. The same procedure is performed on the contralateral side, with great care taken to avoid inadvertently damaging the delicate reanastomosis line in the first tube.

This procedure invariably involves minimal or no blood loss. We gently irrigate the pelvis at regular intervals during the case to avoid desiccation, and carefully remove any small blood clots that may form. We do not employ any other adhesion-prevention strategies.

Patients leave the hospital within 3 hours of surgery and expect complete recovery within 2 weeks. Pelvic rest is recommended for the first month after surgery, and contraception is recom-

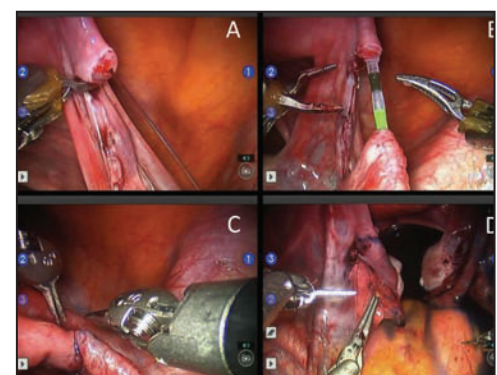
mended until after their hysterosalpingogram 2 months after surgery.

### A 'Swift Learning Curve'

Robotic assistance allows easy performance of classic microsurgical reanastomosis through laparoscopic access. Aside from shorter recovery time and a lower chance of complications, the robotic approach does not provide major clinical advantages over classic minilaparotomy. However, having performed and taught all three types of tubal reanastomosis (classic microsurgical, laparoscopic, and robot-assisted laparoscopic), I have been impressed by a unique quality of robotic reanastomosis: its eminent reproducibility and swift learning curve.

The enabling nature of robotic technology makes tubal reanastomosis a perfect example of an operation that is more safely learned and performed robotically. At our institution, we have developed a protocol for fast-track teaching of robot-assisted laparoscopic tubal reanastomosis that involves several hours of inanimate training at the console to get familiar with microrobotic instruments and sutures, as well as a chance to assist on these cases at bedside.

This is followed by an intensive use of Telestration, a technology specific to the da Vinci surgical system that greatly improves communication between the teacher and apprentice during surgery. The apprentice sits at the console while the attending surgeon remains by his/her side and communicates precise instructions by direct verbal cues and by drawing on a dedicated monitor that shows the operator's right field of vision. The drawings



**Figure 4 shows A. Preparation of the proximal stump with flow of dye from the transected tubal lumen. B. Graduated ERCP cannula set as an intraluminal stent. C. 8-0 polypropylene sutures are placed at 12, 3, 6 and 9 o'clock. D. Bilateral spill at final chromopertubation.**

are transmitted in real time to the console, where they superimpose on the operator's visual field so that he/she may incorporate them into the current surgical act.

Aside from the expected differences in speed of performance, the quality and the safety of the operations performed by the teacher and the apprentice are absolutely comparable even on the first case. Coupled with a simple teaching strategy, robotic technology thus dramatically shortens the learning curve of a complex microsurgical operation. It is hard to deny the value of a procedure that can be safely taught and reliably reproduced in a single session. ■

*Dr. Gargiulo reported that he has no disclosures relevant to this feature.*