

## Zoster Vaccine Could Have Off-Label Use

BY BRUCE JANCIN

VAIL, COLO. — Giving herpes zoster vaccine to children who are immunocompromised, or are about to become so, is an off-label use that is nonetheless worthy of strong consideration in selected cases.

That's the view of vaccine expert Dr. Myron J. Levin, who notes that herpes zoster in immunocompromised children tends to be extremely severe.

"It makes sense to give the vaccine to children who've had chicken pox and are going to have a transplant. Maybe you can protect them from zoster down the road by giving them the zoster vaccine up front. It's a new thought," he said at a conference on pediatric infectious diseases sponsored by the Children's Hospital, Denver.

As for children who are already immunocompromised, it is important to look for safe opportunities in which to administer the herpes zoster (HZ) vaccine, which contains 14-fold higher titers of varicella zoster virus than the childhood varicella vaccine.

"It's probably going to be safe wherever it's safe to give the varicella vaccine to immune-compromised kids. That's where I would start. The reason I can say that is because they already have some preexisting immunity. You're not giving this vaccine to a naive person, you're giving it to someone who has a history of varicella. So it's unlikely they're going to have serious side effects unless they're very, very immunocompromised," explained Dr. Levin, professor of pediatrics and medicine at the University of Colorado at Denver.

Thus, HZ vaccination is to be avoided in situations of severe immune compromise because it could result in a fulminant case of zoster, he added.

In contrast, circumstances in which giving varicella vaccine—and, by extension, HZ vaccine—appears to be safe and beneficial include HIV-infected patients with more than 15% CD4 cells, particularly if highly active antiretroviral therapy is on board; recipients of a solid organ transplant 6 months or more before without complications or need for rejection therapy; lymphoma patients who successfully completed treatment at least 3 months earlier; and individuals who are 18-24 months post-stem cell transplant with no rejection episodes or other problems, good cell counts, and who are off immunosuppressive therapy, according to Dr. Levin.

The HZ vaccine is licensed for immune-competent individuals aged 60 years and older. It is now in large clinical trials looking at enlarging the recipient pool to include 50- to 59-year-olds, he said.

Dr. Levin disclosed that he is a consultant to, on the speakers bureau for, and receives royalties from Merck. ■

## Propranolol Effective for Infantile Hemangiomas

BY MICHELE G. SULLIVAN

The beta-blocker propranolol appears almost 100% effective in treating severe infantile hemangiomas, according to a French case series of 32 patients.

The group, led by Dr. Véronique Sans of Children's Hospital in Bordeaux, France, found that even life-threatening hemangiomas responded dramatically to propranolol treatment, with overnight

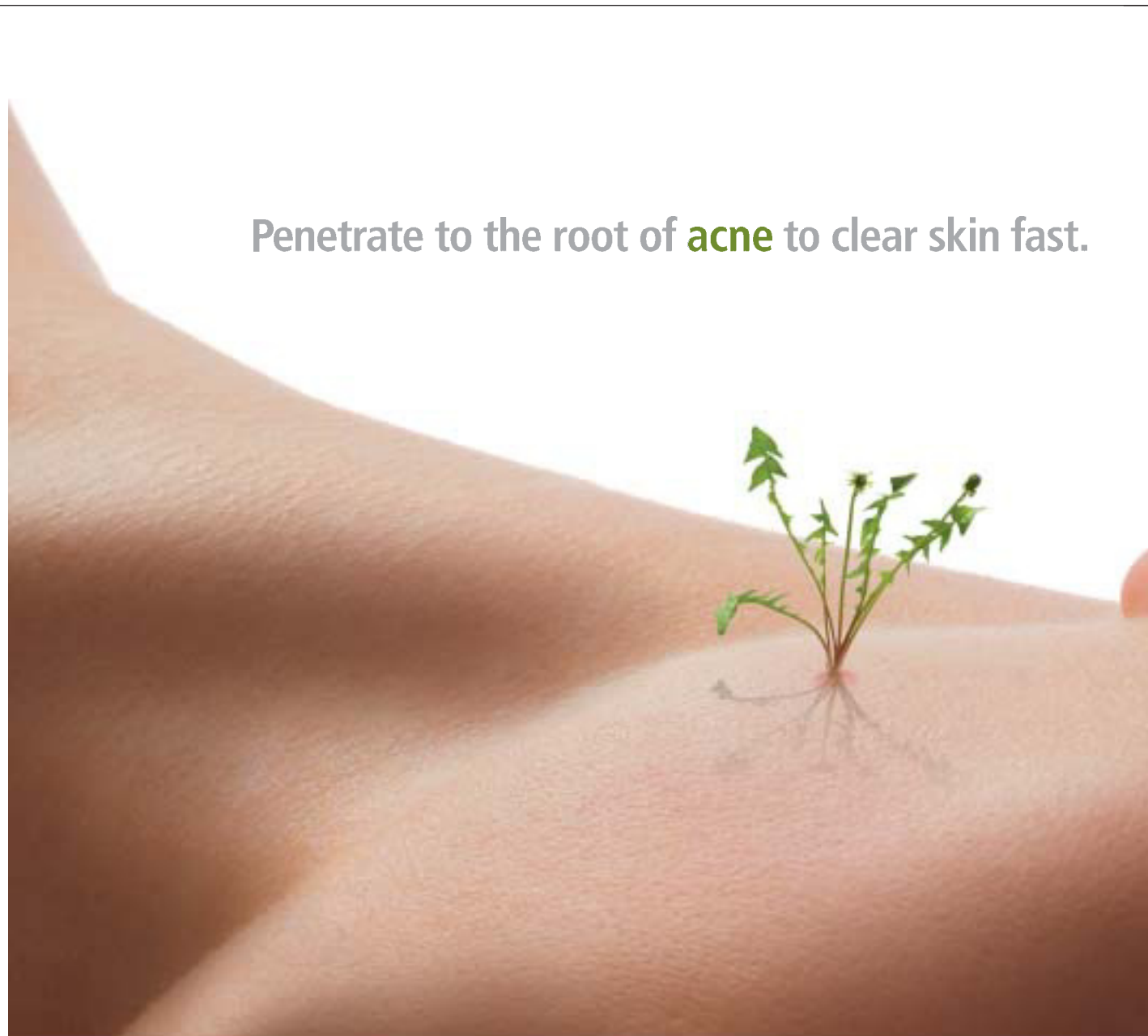
color change and lesion softening after the first dose (2-3 mg/kg per day).

"Symptoms such as dyspnea and hemodynamic compromise [due to the lesions] regressed within 48 hours, and spontaneous ocular opening [in children with periorbital lesions] was possible within 7 days," wrote Dr. Sans and her colleagues (DOI: 10.1542/peds.2008-3458). After 2-14 months of treatment, all hemangiomas had become nearly flat, with residual telangiectasias. There

was mild recoloration in four cases and mild regrowth in three cases.

The observations in the paper are a fairly accurate representation of propranolol's remarkable effect on these lesions, Dr. Bernard Cohen said in an interview. Last July, after Dr. Sans' colleagues made an initial public report of their experience, Dr. Cohen began using propranolol as the first-line treatment for serious infantile hemangiomas in the pediatric vascular lesions clinic at Johns

Penetrate to the root of **acne** to clear skin fast.



Acne starts deep in the follicle, but traditional benzoyl peroxide products remain primarily on the surface of the skin. Only Obagi® CLENZiderm M.D. Acne Therapeutic Systems™ use a solubilized 5% BPO to penetrate deep and clear acne in as little as two weeks. In fact, it's proven to deliver greater\* *P. acnes* kill rates and rapid lesion reduction compared to a leading topical prescription BPO/clindamycin combination. Treat acne at the root, and don't let it grow to see the light of day.

Available in two prescription-strength formulations for skin that's normal to oily or normal to dry. To order CLENZiderm M.D., please contact your Obagi Sales Representative or call 1.800.636.7546.

To see data from a study showing the benefits of solubilized 5% BPO technology, go to [Obagi.com/BPO](http://Obagi.com/BPO)

\*Evaluation of *in-vivo* antimicrobial efficacy of three formulations containing benzoyl peroxide on *P. acnes* (at 3 and 8 hours post application). CLENZiderm M.D. and CLENZiderm M.D. Acne Therapeutic Systems are trademarks of OMP, Inc. Obagi is a registered trademark of OMP, Inc. © 2009 Obagi Medical Products, Inc. All rights reserved. 4/09

Hopkins Medical Center in Baltimore. "I haven't used steroids in any of these children since then," said Dr. Cohen, director of pediatric dermatology at the center. He and his colleagues have so far treated 41 children with propranolol and will soon publish their own experience. Although they have not had quite the 100% success rate that the French group claims, Dr. Cohen said the drug is very effective, extremely safe, and can be given without the concerns for growth and immune response that come with steroid therapy.

"I think it works better than oral

steroids, but it doesn't work for everyone," he said, adding that lesions on infants responded better to the treatment than lesions on children who were older than 1 year. "If lesions are causing a lot of [functional problems], propranolol does seem to shut them down, but it did not make a dramatic difference in every one of our patients. However, it is very safe—especially compared to oral steroids."

The French team observed serendipitously that beta-blockers used for hypertension in infants positively affected the growth of hemangiomas. In 2008, fol-

lowing that observation, they described their index case and 10 additional cases (N. Engl. J. Med. 2008; 358:2649-51).

The current report comprises 32 children (mean age 4 months) with severe hemangiomas. All of the lesions imposed either life-threatening symptoms or the risk of severe disfigurement.

Treatment consisted of a course of oral propranolol at a dose of 2-3 mg/kg per day, initiated in an inpatient setting so that clinicians could observe the child's reaction. Blood pressure and heart rate were monitored every hour during the first 6 hours of treatment. If

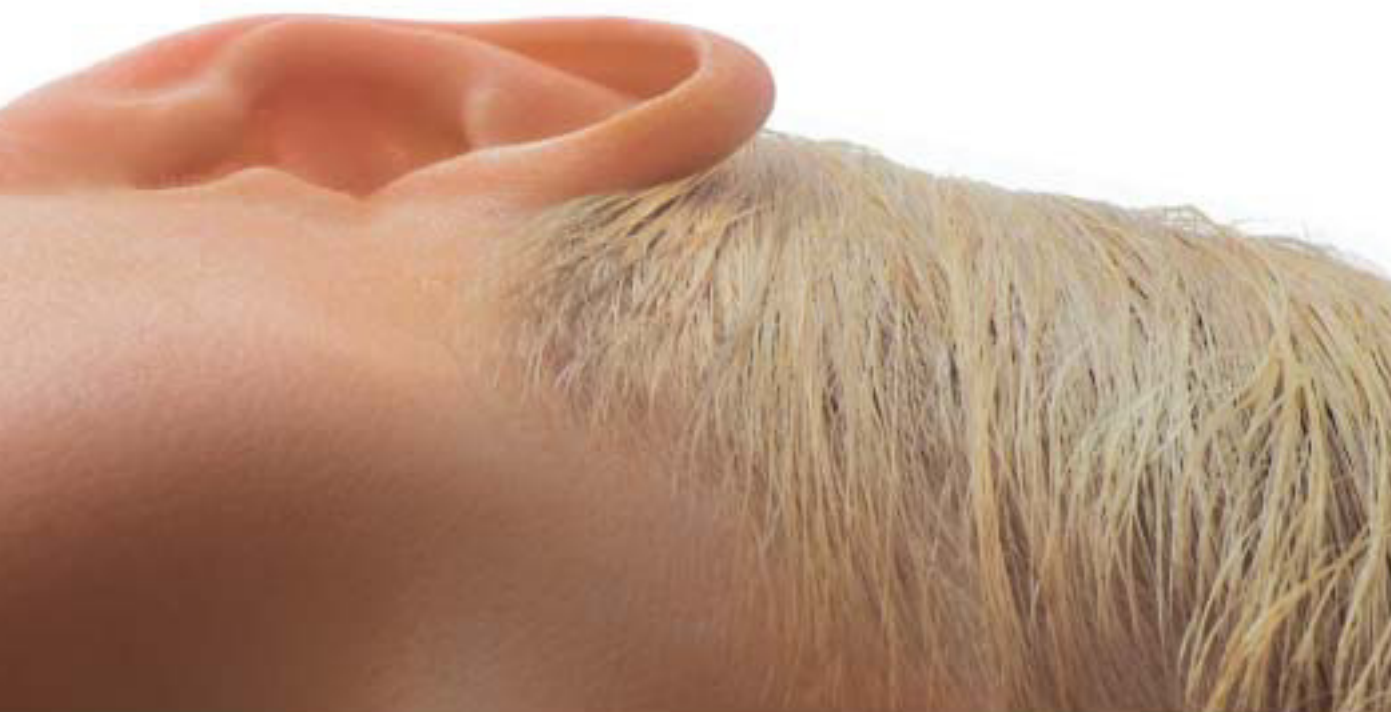no adverse events occurred, the child was sent home and re-evaluated after another 10 days, with monthly evaluations afterward, Dr. Sans and her associates said.

Most of the treatments (27) were early interventions on children aged 1-12 months. For these children, the goal was to decrease functional risk, serious symptoms, or cosmetic complications. The other five children were 18-48 months old; their treatment goal was functional risk or cosmetic risk. Thirteen of the children had received corticosteroids with no benefit.

Children who had ulcerated hemangiomas experienced complete healing within 2 months of therapy initiation. In the 11 children with ultrasound measurements, the 60-day exam showed a mean lesion thickness regression of



www.obagi.com



**Since switching to propranolol in July of last year, 'I haven't used steroids in any of these children.'**

DR. COHEN

40%, with a lower resistivity index, indicating decreased vascular activity.

The 13 children who were taking steroids all discontinued treatment without rebound. Propranolol was discontinued in 6-14 months for the early-intervention cases and in 2-10 months for the later-intervention cases. It was restarted in two cases because of regrowth. The 12 patients with eyelid involvement experienced resolution of astigmatism and amblyopia at the end of therapy, the investigators reported.

Dr. Sans and her associates noted two adverse events. One patient had a decrease in blood pressure while sleeping, 3 hours after the first dose. Another patient discontinued propranolol after experiencing wheezing thought to be caused by allergic asthma.

The authors suggested that the optimal therapy for early intervention would be to give propranolol throughout the hemangioma's proliferative phase, usually from 4 to 12 months of age. For treatments commenced after the proliferative phase has concluded, the therapy should continue until maximum improvement is noted.

The overnight improvements of lesion softening and color change (from intense red to purple) indicated the drug's vasoconstrictive effect on the lesions' capillaries, Dr. Christine Léauté-Labrèze, also of Children's Hospital, said in the initial 2008 report.

Although Dr. Sans and her coauthors said they had no financial conflicts with regard to their paper, Dr. Léauté-Labrèze noted in the 2008 paper that she and her colleagues had applied for a patent for the use of propranolol on infantile hemangiomas. Dr. Léauté-Labrèze and her coauthors—Dr. Franck Boralevi, Dr. Eric Dumas de la Roque, and Dr. Alain Taïeb—who are with Children's Hospital, are also coauthors of Dr. Sans' paper. ■



CLENZiderm M.D.™

