

# Anterior Rectal Resection for Endometriosis

*In 76% of rectovaginal cases, pain was either eliminated or got much better, according to a study of 37 women.*

BY KATE JOHNSON  
Montreal Bureau

LONDON — Anterior rectal resection and anastomosis for the treatment of rectovaginal endometriosis can provide significant pain relief with an acceptable level of complications, according to a study presented at the annual congress of the International Society for Gynecologic Endoscopy.

"No one knows whether you should perform a rectal resection or simply shave the disease off the surface. An anterior resection is obviously more radical, but the theory is that by doing this you are more likely to remove all of the disease, includ-

ing microscopic and multifocal disease, and there will be less chance of recurrence," said Nicholas Kenney, M.D., a clinical fellow at Worthing Hospital (England).

Dr. Kenney presented a review of 37 anterior rectal resections he performed with his colleagues, including his supervisor James English, M.D., a consultant gynecologist at the same hospital.

Of the total 37 procedures, 21 were performed by laparotomy, and the remaining 16 were done by laparoscopy.

In the study, 28 patients (76%) had a primary bowel anastomosis without a stoma, 1 had a preoperative stoma, 2 required a temporary loop colostomy because of low rectal anastomosis, and 6 required a tem-

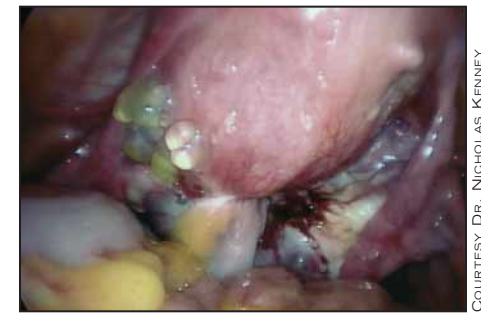porary ileostomy because they also underwent either sigmoid, ileal, or cecal resections of endometriosis.

In addition, 31 patients had ovarian preservation, and 14 had their uteri preserved. All 37 patients had positive histology for endometriosis; 21 of those patients had evidence of endometriosis in the muscularis layer of the bowel.

A postoperative survey of patients revealed that in 76% of patients, pain was either completely gone or much better.

Although there were a number of complications, the complication rate was similar to those that have been reported by other groups in association with this surgery, Dr. Kenney said.

In his series, one patient developed a uterovaginal fistula, and another patient developed a rectovaginal fistula, both of which were successfully repaired.



The rectum sticks to the posterior uterine surface in this endometriosis patient.

In addition, there were nine rectovaginal anastomotic strictures, which were all managed successfully by balloon dilation under sedation. There also were eight urinary tract infections, one deep vein thrombosis. There was one case of pelvic collection, which was settled with conservative management. ■

## Good Results, Satisfaction After Partial Colpocleisis

BY SHERRY BOSCHERT  
San Francisco Bureau

RANCHO MIRAGE, CALIF. — Three of 32 women regretted undergoing partial colpocleisis a mean of 28 months after surgery, two because of recurrent prolapse and one due to continued stress incontinence, Thomas L. Wheeler II, M.D., reported.

In follow-up interviews, none cited loss of sexual function as a reason for regret. Overall, satisfaction rates were high, he said at the annual meeting of the Society of Gynecologic Surgeons.

The surgery significantly reduced patient distress over symptoms and the impact of incontinence on their lives, compared with baseline levels, assessed by the short-form Incontinence Impact Questionnaire (IIQ) and the short-form Urogenital Distress Inventory (UDI).

There have been no published reports comparing preoperative and postoperative quality of life scores using validated instruments such as these to assess results from colpocleisis, noted Dr. Wheeler of the University of Alabama, Birmingham.

The investigators obtained records on 54 patients who had undergone partial colpocleisis during a 5-year period, but 19 patients were demented, lost to follow-up, or deceased. Three declined to participate in the study. The remaining 32 patients answered a question about regret, and 28 of them also answered a question about satisfaction with results of the surgery. The mean age of respondents was 81 years.

In the three patients (9%) who regretted the surgery, the two recurrent prolapses occurred at 5 and 7 months

after the operation. The third patient had undergone a modified Pereyra procedure at the time of colpocleisis and reported continuing incontinence.

Sixteen of the 28 patients said they were completely satisfied with their progress since the surgery, 8 were somewhat satisfied, and 4 (14%) were not satisfied, he said.

The IIQ asked seven questions about whether and how severely urine leakage affected various functions in patients' lives, emotional health, and feelings of frustration,



**Sixteen of the 28 patients said they were completely satisfied with their progress since the surgery.**

DR. WHEELER

with higher scores representing a greater impact of incontinence. Mean scores improved significantly from 41 before surgery to 14 at the last interview.

The UDI contained six questions about whether and how much patients were bothered by symptoms such as frequent urination, leakage, difficulty emptying the bladder, and pain or discomfort, with higher scores indicating worse outcomes. Mean scores improved significantly from 63 before surgery to 24 at the last interview, Dr. Wheeler said.

In previous reports, regret rates ranged from 0% to 10% in four case series, one of partial colpocleisis and three of total colpocleisis. A previous report of patient satisfaction in a series of total colpocleisis procedures reported that 5% of patients were not satisfied with results. ■

## Grafts Offer No Added Protection Against Recurrence in Pelvic Prolapse

BY SHERRY BOSCHERT  
San Francisco Bureau

RANCHO MIRAGE, CALIF. — Graft augmentation did not offer additional protection against recurrence in patients undergoing vaginal surgery for symptomatic pelvic organ prolapse and was linked to an increase in postoperative complications in a review of 312 cases.

Two specialists in the treatment of pelvic floor disorders performed the surgeries over a 5-year period and used their discretion in select cases to add graft augmentation to support the anterior vaginal wall, posterior vaginal wall, or both.

Over a median 9-month follow-up, there were no differences in recurrence of prolapse or incontinence, or in the need for additional surgery between the 32% of patients who received grafts and those women who did not, Babak Vakili, M.D., said during the annual meeting of the Society of Gynecologic Surgeons.

Patients receiving graft augmentation had higher rates of postoperative complications,

including vaginal or graft infection (18% vs. 5%) and granulation tissue (39% vs. 17%).

As a result, patients with grafts needed more postoperative visits—an average of four visits versus three visits, said Dr. Vakili of Cooper University Hospital, Voorhees, N.J.

The mean length of follow-up was 12 months in the graft group and 15 months in the other patients.

**Patients with grafts needed more postoperative visits—an average of four visits versus three.**

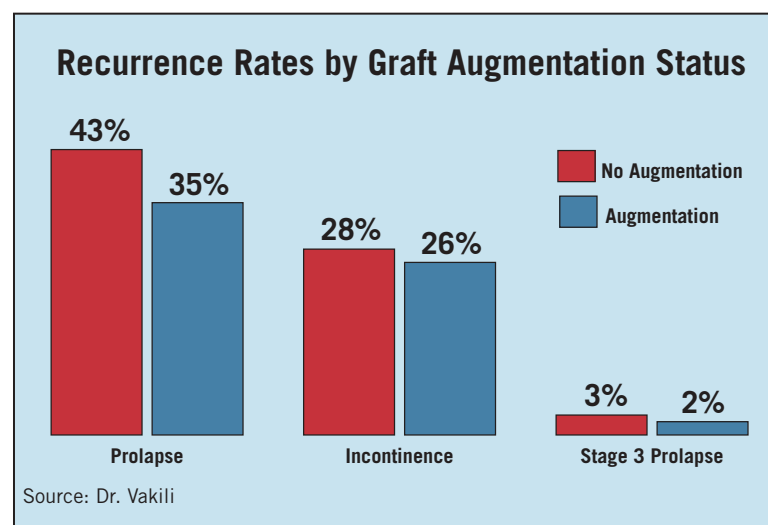
DR. VAKILI

Recurrence rates were similar in both groups. (See accompanying graphic.) Eight percent of the graft group and 9% of the nongraft group needed additional surgery for incontinence.

Women in the graft group were older than in the nongraft group (65 years vs. 61 years), were more likely to be menopausal (93% vs. 83%), and were more parous (3.3 vs. 2.9 children). After controlling for these factors, investigators still found no difference in surgical outcomes.

A subanalysis comparing the cases by the biologic and synthetic materials in the grafts also found no difference in outcomes. Another subanalysis comparing anterior vaginal wall grafts and posterior vaginal wall grafts also found no difference in the likelihood of recurrent prolapse or incontinence.

"In the early postoperative period, there was no improvement in surgical outcomes when using grafts to augment vaginal repair of either the anterior vaginal wall, posterior vaginal wall, or both," he said. ■



KEVIN FOLEY, RESEARCH/DESIGN