

# Radical, Fertility-Sparing Surgery Improves Pain

Early results are called 'encouraging' in the first study reporting treatment outcomes in adolescents.

BY KATE JOHNSON  
Montreal Bureau

LONDON — Radical, fertility-sparing excision of severe endometriosis in adolescent girls can eliminate or greatly improve pain, reported Andreas I. Stavroulis, M.D., at the annual congress of the International Society for Gynecologic Endoscopy.

"This is the first study reporting the outcome of radical excision treatment for severe endometriosis in this age-group, and early results are encouraging," reported Dr. Stavroulis of the endometriosis unit, University College London Hospitals.

Dr. Stavroulis and his colleagues re-

viewed the cases of 31 girls under age 20 years who underwent laparoscopy to investigate chronic pelvic pain, which had failed to respond to medical treatment.

No pelvic abnormalities were found in 11 patients, and endometriosis was detected in 11. Other diagnoses included four nonfunctional nonendometriotic ovarian cysts, one functional ovarian cyst, one bilateral and one unilateral hydrosalpinx, and two obstructed uterine horns.

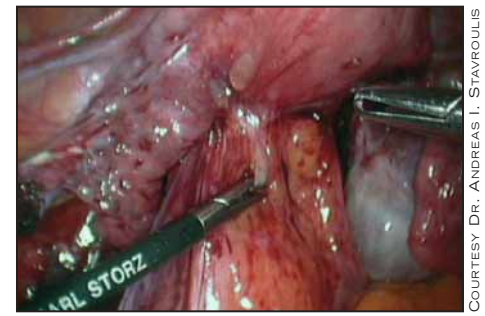
Of the 11 patients with endometriosis, 6 had severe disease that was treated with radical excision, and there were no complications. Five were rendered pain free, while one had improved symptoms, he said.

"Our follow-up is only short to medium term—up to 112 weeks—but we are going to follow them further to see if they have any future problems," he said.

Endometriosis and laparoscopy are not commonly considered in adolescent girls with chronic pelvic pain, partly because of a misconception among many generalists that the disease is rare in this age-group, Dr. Stavroulis said.

In fact, it is the most common reason for chronic pelvic pain that is nonresponsive to medical therapy, and there is evidence in the literature that endometriosis can occur as early as premenarche in some girls, he said.

However, even when the disease is recognized, many physicians hesitate to treat it surgically. "It's not an easy decision. You obviously have to make sure that the girl and her parents appreciate that these operations do have risks. But if you have



This image shows a teen with severe endometriosis.

tried all the other alternatives, like medical therapy, and if you see severe endometriosis on laparoscopy—then why not?"

Dr. Stavroulis said parents must be informed that while endometriosis itself may cause problems with infertility, radical excision may cause adhesions that could also interfere with fertility. ■

## Posterior Colporrhaphy Plus Dermal Graft Eases Bowel Dysfunction

BY SHERRY BOSCHERT  
San Francisco Bureau

RANCHO MIRAGE, CALIF. — Posterior colporrhaphy with AlloDerm graft augmentation significantly improved bowel dysfunction while causing no major complications in a prospective study of 188 women treated for symptomatic rectocele.

Symptoms of constipation, incomplete evacuation, and fecal incontinence improved significantly over a mean 18-month follow-up period. Dyspareunia rates also improved, compared with baseline, but the difference was not statistically significant, Ahsen Chaudhry, M.D., and Robert W. Lobel, M.D., both of Albany, N.Y., reported in a poster at the annual meeting of the Society of Gynecologic Surgeons.



Success rates for conventional posterior colporrhaphy of up to 75% at 1-2 years after surgery decline significantly beyond 3 years. More site-specific repair seems to cause fewer complications, with success rates of 72%-85% at 1 year after surgery, separate data suggest.

Both posterior colporrhaphy and site-specific repair can be hampered by the use of already weakened autologous endopelvic connective tissue, Dr. Chaudhry said. In particular, high rectoceles can be problematic because little or no autologous material is available for fixation.

These factors led the investigators to study the safety and efficacy of posterior colporrhaphy with AlloDerm graft augmentation. The investigators said they have no relationship with the manufacturer of AlloDerm.

The surgeries were performed over a 2-year period on patients with a mean age of 58 years and a mean body mass index of 30. Most patients (72%) were postmenopausal. The rectocele extended to or beyond the hymenal ring in 85% of patients.

The proportion of patients who said they were sexually active did not change significantly from before to after surgery (68% vs. 69%).

Previous surgeries included hysterectomy in 58% of patients, anterior colporrhaphy in 27%, posterior repair in 13%, sacrocolpopexy in 4%, and sacrospinous vaginal vault suspension in 2%.

Concomitant procedures performed at the time of posterior colporrhaphy with dermal graft augmentation included anterior colporrhaphy in 24% of patients, anterior colporrhaphy with AlloDerm graft in 6%, sacrospinous vaginal vault suspension in 59%, abdominal sacrocolpopexy in 22%, subtotal abdominal hysterectomy in 6%, total abdominal hysterectomy in 2%, anal sphincteroplasty in 2%, vaginal hysterectomy in 10%, and surgery for stress urinary incontinence in 59%.

There were no major complications perioperatively. ■

## More Cystotomies Seen When Sling Is Combined With Reconstructive Surgery

BY SHERRY BOSCHERT  
San Francisco Bureau

RANCHO MIRAGE, CALIF. — The risk of cystotomy while placing a tension-free transvaginal tape suburethral sling tripled when surgeons performed concomitant pelvic floor reconstructive surgery, according to a review of 106 sling procedures.

"I'm not sure why that was the case. It certainly has not been reported very prominently in other series" and may be related to the relative inexperience of the 14 community physicians who performed the procedures, compared with surgeons in earlier reports, Michael J. Bonidie, M.D., said during the annual meeting of the Society of Gynecologic Surgeons.

Cystotomy rates also tripled in patients whose surgeons had done fewer than 10 tension-free transvaginal tape (TVT) sling procedures, compared with physicians who had done more than 10.

Only 3 physicians performed more than 10 TVT sling procedures, and 11 physicians did fewer than 10 of the sling surgeries during the study's 3-year period, reported Dr. Bonidie and Neeka L. Sanders, M.D., both of the Western Pennsylvania Hospital, Pittsburgh.

Cystotomies occurred in 6 of 60 patients (10%) who underwent sling surgery alone and 13 of 46 patients (28%) who underwent sling and pelvic floor reconstruction surgery, said Dr. Bonidie, director of urogynecology at the hospital.

Cystotomy rates were markedly higher among the less-experienced physicians, whether placing a TVT sling alone or doing a sling plus pelvic floor reconstruction procedure.

The cystotomy rates in the current study are higher than those reported in earlier series of suburethral sling surgeries, most of which were done by a select group of specialists who were single operators in their case series, Dr. Bonidie noted during the meeting.

One series of 350 TVT sling surgeries, for example, reported a 5% cystotomy rate, significant bleeding in 1%, and postoperative voiding dysfunction in 5% of patients.

"We deemed that to be acceptable risks for this procedure," he said.

Today, several different types of slings made by different companies are marketed to general gynecologists who may have little or no experience with suburethral sling placement.

This proliferation inspired the investigators to review results in a community hospital setting, where physicians tend to place slings less frequently than their counterparts in more specialized settings.

All slings in the current series were placed vaginally using similar techniques and one of two sling products.

Dr. Bonidie is a consultant for Bard Urological and Ethicon Endosurgery, the two companies that make the slings used in this series. ■