

Adverse Event	amlodipine		Placebo	
	M=% (N=1218)	F=% (N=512)	M=% (N=914)	F=% (N=336)
Edema	5.6	14.6	1.4	5.1
Flushing	1.5	4.5	0.3	0.9
Palpitations	1.4	3.3	0.9	0.9
Somnolence	1.3	1.6	0.8	0.3

The following events occurred in $\leq 1\%$ but $>0.1\%$ of patients treated with amlodipine in controlled clinical trials or under conditions of open trials or marketing experience where a causal relationship is uncertain; they are listed to alert the physician to a possible relationship: **Cardiovascular:** arrhythmia (including ventricular tachycardia and atrial fibrillation), bradycardia, chest pain, hypotension, peripheral ischemia, syncope, tachycardia, postural dizziness, postural hypotension, vasculitis. **Central and Peripheral Nervous System:** hypoesthesia, neuropathy peripheral, paresthesia, tremor, vertigo. **Gastrointestinal:** anorexia, constipation, dyspepsia, dysphagia, diarrhea, flatulence, pancreatitis, vomiting, gingival hyperplasia. **General:** allergic reaction, asthenia, back pain, hot flushes, malaise, pain, rigors, weight gain, weight decrease. **Musculoskeletal System:** arthralgia, arthrosis, muscle cramps, myalgia. **Psychiatric:** sexual dysfunction (male and female), insomnia, nervousness, depression, abnormal dreams, anxiety, depersonalization. **Respiratory System:** dyspnea, epistaxis. **Skin and Appendages:** angioedema, erythema multiforme, pruritus, rash, erythematous rash maculopapular. **Special Senses:** abnormal vision, conjunctivitis, diplopia, eye pain, tinnitus. **Urinary System:** micturition frequency, micturition disorder, nocturia. **Autonomic Nervous System:** dry mouth, sweating increased. **Metabolic and Nutritional:** hyperglycemia, thirst. **Hematologic:** leukopenia, purpura, thrombocytopenia. The following events occurred in $\leq 0.1\%$ of patients treated with amlodipine in controlled clinical trials or under conditions of open trials or marketing experience: cardiac failure, pulse irregularity, extrasystoles, skin discoloration, urticaria, skin dryness, alopecia, dermatitis, muscle weakness, twitching, ataxia, hypertension, migraine, cold and clammy skin, apathy, agitation, amnesia, gastritis, increased appetite, loose stools, coughing, rhinitis, dysuria, polyuria, parosmia, taste perversion, abnormal visual accommodation, and xerophthalmia. Other reactions occurred sporadically and cannot be distinguished from medications or concurrent disease states such as myocardial infarction and angina. Amlodipine therapy has not been associated with clinically significant changes in routine laboratory tests. No clinically relevant changes were noted in serum potassium, serum glucose, total triglycerides, total cholesterol, HDL cholesterol, uric acid, blood urea nitrogen, or creatinine. The following postmarketing event has been reported infrequently with amlodipine treatment where a causal relationship is uncertain: gynecomastia. In postmarketing experience, jaundice and hepatic enzyme elevations (mostly consistent with cholestasis or hepatitis) in some cases severe enough to require hospitalization have been reported in association with use of amlodipine. Amlodipine has been used safely in patients with chronic obstructive pulmonary disease, well-compensated congestive heart failure, peripheral vascular disease, diabetes mellitus, and abnormal lipid profiles. **The Atorvastatin Component of CADUET:** Atorvastatin is generally well-tolerated. Adverse reactions have usually been mild and transient. In controlled clinical studies of 2502 patients, $<2\%$ of patients were discontinued due to adverse experiences attributable to atorvastatin calcium. The most frequent adverse events thought to be related to atorvastatin calcium were constipation, flatulence, dyspepsia, and abdominal pain. Clinical Adverse Experiences: Adverse experiences reported in $\geq 2\%$ of patients in placebo-controlled clinical studies of atorvastatin, regardless of causality assessment, are shown in Table 3.

Table 3. Adverse Events in Placebo-Controlled Studies (% of Patients)

Body System/ Adverse Event	Placebo N=270	atorvastatin			
		10 mg N=863	20 mg N=36	40 mg N=79	80 mg N=94
BODY AS A WHOLE					
Infection	10.0	10.3	2.8	10.1	7.4
Headache	7.0	5.4	16.7	2.5	6.4
Accidental Injury	3.7	4.2	0.0	1.3	3.2
Flu Syndrome	1.9	2.2	0.0	2.5	3.2
Abdominal Pain	0.7	2.8	0.0	3.8	2.1
Back Pain	3.0	2.8	0.0	3.8	1.1
Allergic Reaction	2.6	0.9	2.8	1.3	0.0
Asthenia	1.9	2.2	0.0	3.8	0.0
DIGESTIVE SYSTEM					
Constipation	1.8	2.1	0.0	2.5	1.1
Diarrhea	1.5	2.7	0.0	3.8	5.3
Dyspepsia	4.1	2.3	2.8	1.3	2.1
Flatulence	3.3	2.1	2.8	1.3	1.1
RESPIRATORY SYSTEM					
Sinusitis	2.6	2.8	0.0	2.5	6.4
Pharyngitis	1.5	2.5	0.0	1.3	2.1
SKIN AND APPENDAGES					
Rash	0.7	3.9	2.8	3.8	1.1
MUSCULOSKELETAL SYSTEM					
Arthralgia	1.5	2.0	0.0	5.1	0.0
Myalgia	1.1	3.2	5.6	1.3	0.0

Anglo-Scandinavian Cardiac Outcomes Trial (ASCOT): In ASCOT involving 10,305 participants treated with atorvastatin 10 mg daily (n=5,168) or placebo (n=5,137), the safety and tolerability profile of the group treated with atorvastatin was comparable to that of the group treated with placebo during a median of 3.3 years of follow-up. The following adverse events were reported, regardless of causality assessment, in patients treated with atorvastatin in clinical trials. The events in italics occurred in $\geq 2\%$ of patients and the events in plain type occurred in $<2\%$ of patients. **Body as a Whole:** Chest pain, face edema, fever, neck rigidity, malaise, photosensitivity reaction, generalized edema. **Digestive System:** Nausea, gastroenteritis, liver function tests abnormal, colitis, vomiting, gastritis, dry mouth, rectal hemorrhage, esophagitis, eructation, glossitis, mouth ulceration, anorexia, increased appetite, stomatitis, biliary pain, cheilitis, duodenal ulcer, dysphagia, enteritis, melena, gum hemorrhage, stomach ulcer, tenesmus, ulcerative stomatitis, hepatitis, pancreatitis, cholestatic jaundice. **Respiratory System:** Bronchitis, rhinitis, pneumonia, dyspnea, asthma, epistaxis. **Nervous System:** Insomnia, dizziness, paresthesia, somnolence, amnesia, abnormal dreams, libido decreased, emotional lability, incoordination, peripheral neuropathy, torticollis, facial paralysis, hyperkinesia, depression, hypesthesia, hypertension. **Musculoskeletal System:** Arthritis, leg cramps, bursitis, tenosynovitis, myasthenia, tendinous contracture, myositis. **Skin and Appendages:** Pruritus, contact dermatitis, alopecia, dry skin, sweating, acne, urticaria, eczema, seborrhea, skin ulcer. **Urinary System:** Urinary tract infection, urinary frequency, cystitis, hematuria, impotence, dysuria, kidney calculus, nocturia, epididymitis, fibrocystic breast, vaginal hemorrhage, albuminuria, breast enlargement, metrorrhagia, nephritis, urinary incontinence, urinary retention, urinary urgency, abnormal ejaculation, uterine hemorrhage. **Special Senses:** Amblyopia, tinnitus, dry eyes, refraction disorder, eye hemorrhage, deafness, glaucoma, parosmia, taste loss, taste perversion. **Cardiovascular System:** Palpitation, vasodilatation, syncope, migraine, postural hypotension, phlebitis, arrhythmia, angina pectoris, hypertension. **Metabolic and Nutritional Disorders:** Peripheral edema, hyperglycemia, creatine phosphokinase increased, gout, weight gain, hypoglycemia. **Hemic and Lymphatic System:** Echinomysis, anemia, lymphadenopathy, thrombocytopenia, petechia. **Postintroduction Reports with Atorvastatin:** Adverse events associated with atorvastatin therapy reported since market introduction, that are not listed above, regardless of causality assessment, include the following: anaphylaxis, angioneurotic edema, bullous rashes (including erythema multiforme, Stevens-Johnson syndrome, and toxic epidermal necrolysis), and rhabdomyolysis. **Pediatric Patients (ages 10-17 years):** In a 26-week controlled study in boys and postmenarchal girls (n=140), the safety and tolerability profile of atorvastatin 10 to 20 mg daily was generally similar to that of placebo (see **PRECAUTIONS, Pediatric Use**).

OVERDOSAGE: There is no information on overdosage with CADUET in humans. **Information on Amlodipine:** Single oral doses of amlodipine maleate equivalent to 40 mg amlodipine/kg and 100 mg amlodipine/kg in mice and rats, respectively, caused deaths. Single oral amlodipine maleate doses equivalent to 4 or more mg amlodipine/kg in dogs (11 or more times the maximum recommended clinical dose on a mg/m² basis) caused a marked peripheral vasodilation and hypotension. Overdosage might be expected to cause excessive peripheral vasodilation with marked hypotension and possibly a reflex tachycardia. In humans, experience with intentional overdosage of amlodipine is limited. Reports of intentional overdosage include a patient who ingested 250 mg and was asymptomatic and was not hospitalized; another (120 mg) was hospitalized, underwent gastric lavage and remained normotensive; the third (105 mg) was hospitalized and had hypotension (90/50 mmHg) which normalized following plasma expansion. A patient who took 70 mg amlodipine and an unknown quantity of benzodiazepine in a suicide attempt developed shock which was refractory to treatment and died the following day with abnormally high benzodiazepine plasma concentration. A case of accidental drug overdose has been documented in a 19-month-old male who ingested 30 mg amlodipine (about 2 mg/kg). During the emergency room presentation, vital signs were stable with no evidence of hypotension, but a heart rate of 180 bpm. Ipecac was administered 3.5 hours after ingestion and on subsequent observation (overnight) no sequelae were noted. If massive overdose should occur, active cardiac and respiratory monitoring should be instituted. Frequent blood pressure measurements are essential. Should hypotension occur, cardiovascular support including elevation of the extremities and the judicious administration of fluids should be initiated. If hypotension remains unresponsive to these conservative measures, administration of vasopressors (such as phenylephrine) should be considered with attention to circulating volume and urine output. Intravenous calcium gluconate may help to reverse the effects of calcium entry blockade. As amlodipine is highly protein bound, hemodialysis is not likely to be of benefit. **Information on Atorvastatin:** There is no specific treatment for atorvastatin overdosage. In the event of an overdose, the patient should be treated symptomatically, and supportive measures instituted as required. Due to extensive drug binding to plasma proteins, hemodialysis is not expected to significantly enhance atorvastatin clearance.

*Based on patient weight of 50 kg.

**These events occurred in less than 1% in placebo-controlled trials, but the incidence of these side effects was between 1% and 2% in all multiple dose studies.

Rx only
Manufactured by:
Pfizer Ireland Pharmaceuticals
Dublin, Ireland

© 2004 Pfizer Ireland Pharmaceuticals



Distributed by:

Pfizer Labs

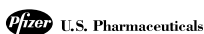
Division of Pfizer Inc., NY, NY 10017

Rev. 1 October 2004

LN233581

© 2005 Pfizer Inc.

All rights reserved.



Cognition Improved by Carotid Artery Stenting

Faster cognition after stenting is related to improved blood perfusion to the brain, imaging study suggests.

BY BRUCE K. DIXON

Chicago Bureau

CHICAGO — Carotid artery stenting appeared to improve cognitive function based on the results of what investigators said is the first study to look at perfusion and diffusion-weighted imaging before and after stenting.

“We found that stenting of the carotid artery significantly increased cognitive speed,” Dr. Iris Grunwald said at the Radiological Society of North America annual meeting. Studies of brain function following carotid endarterectomy have produced mixed results, and there is no consensus in the literature as to whether carotid intervention improves cognition.

Dr. Grunwald and her colleagues at the Saarland University Clinic in Homburg, performed carotid artery stenting on 29 patients. Mean age was 68 years and mean degree of stenosis was 90%. People were excluded from the study if they had paresis in the upper extremity, impairment in eyesight, and/or hemianopsia. Those with psychiatric disease or insufficient command of language also were excluded.

Stents were placed in the left carotid in 18 patients. All of the patients were asymptomatic and right handed. Therefore, speech-related functions were primarily left-brain functions in these patients, she explained.

Perfusion and diffusion-weighted magnetic resonance imaging was performed 24 hours before and 48 hours after intervention (see images). All patients were tested using the Mini-Mental State Examination (MMSE) and symbol digit test and subtests of the CERAD battery. Cognitive speed was assessed with the modified trail making test (ZVT) and the Stroop colored word test.

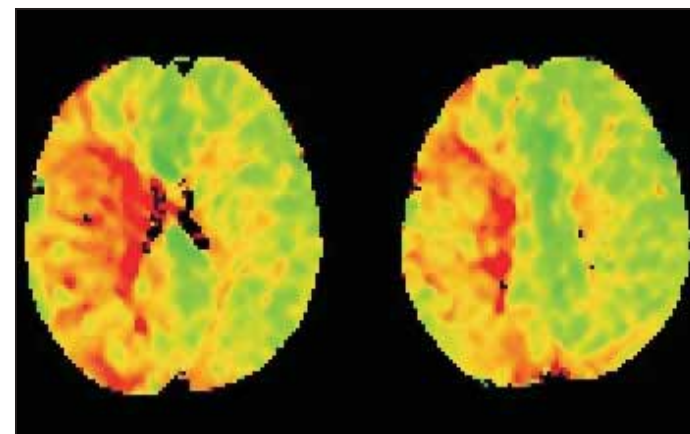
Findings from the Beck Depression Inventory showed that none of the patients suffered from depression. Mean

improvements in cognitive speed ranged from 3% on the ZVT number connection test to almost 7% on the Stroop colored word test.

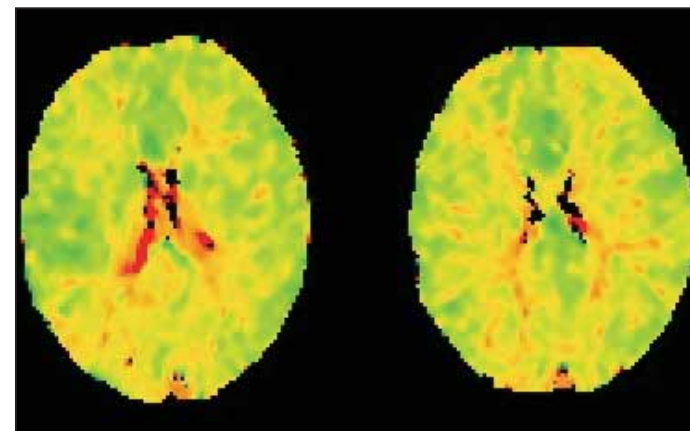
“Stenting of the internal carotid artery seems to improve functions that involve cognitive speed, regardless of the patient’s age, the side of stenosis, or the degree of stenosis,” Dr. Grunwald said. “Some patients showed [more] improvement after stent placement than others. The higher the degree of stenosis, the more marked was the perfusion deficit.

Post-stenting perfusion increased in 17 of the 18 patients, though in 9 of them the increase was described as “slight.” Increased brain perfusion correlated with increased memory function but did not quite reach statistical significance.

“Perfusion of the brain may be what improves cognitive function,” Dr. Grunwald said in an interview. “If that’s the case, other means may be taken to improve blood flow. For example, we are also doing studies with sildenafil, which can also improve blood perfusion in the brain and, it appears, improve cognitive functioning afterwards. Further studies with different time intervals and more refined testing are needed to confirm our findings.”



Perfusion and diffusion-weighted MRIs show impaired cerebral blood flow (red) in a carotid stenosis patient.



Carotid stent placement in the same patient restored cerebral blood flow to closer-to-normal (green) levels.

PHOTOS COURTESY DR. IRIS GRUNWALD