

New Drug Targets Bone Destruction Pathway

BY DIANA MAHONEY

The breakthrough fully human monoclonal antibody denosumab (Prolia) received Food and Drug Administration approval for the treatment of postmenopausal osteoporosis following the agency's fast-track review and request for resubmission of data.

The approval is based primarily on the findings of a pivotal phase III clinical trial designed and funded by the drug manufacturer (Amgen), in which denosumab treatment was associated with a reduction in vertebral, nonvertebral, and hip fracture risk in women with osteoporosis.

Specifically, of the 7,808 women with osteoporosis between the ages of 60 and 90 years enrolled in the FREEDOM (Fracture Reduction Evaluation of Denosumab in Osteoporosis Every 6 Months) trial, those who were assigned to receive twice yearly injections of 60 mg denosumab for 3 years were 68% less likely to develop a vertebral fracture and 40% less likely to develop a hip fracture than were women in the placebo group. Additionally, significantly increased bone mineral density was observed at all of the key sites measured.

By targeting the receptor activator of nuclear factor- κ B ligand (RANKL), which is the primary mediator of osteoclast formation, denosumab blocks the production of the bone-destroying osteoclasts and by so doing improves the density, volume, and strength of both cortical and trabecular bone, according to the authors (N. Engl. J. Med. 2009;361:756-65).

Among the side effects reported in the FREEDOM and other clinical trials of denosumab, the most common include back pain, musculoskeletal pain, extremity pain, hypercholesterolemia, and urinary and bladder infections, according to a statement issued by the FDA. Serious adverse reactions include hypercalcemia, dermatologic conditions, and infections.

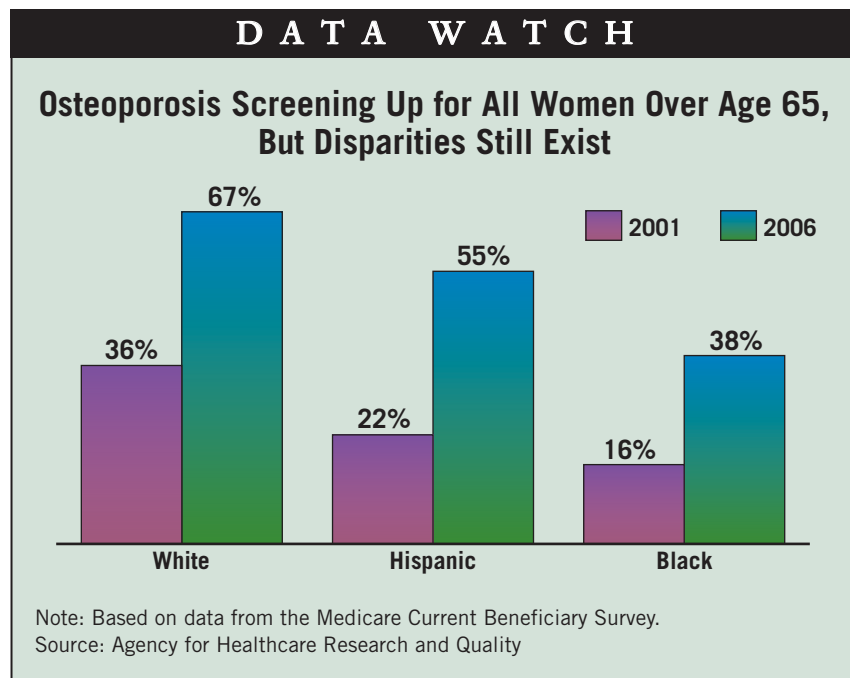
The significance of the long-term suppression of bone remodeling is unknown, according to a press release issued by Amgen.

"The long-term consequences of the degree of suppression of bone remodeling observed with [denosumab] may contribute to adverse outcomes such as osteonecrosis of the jaw, atypical fractures, and delayed fracture healing," the release stated, warning that patients should be monitored for these adverse outcomes.

The FDA approval of denosumab includes a risk evaluation and mitigation strategy comprising a medication guide for patients and communications to health care

providers explaining the risks and benefits of the drug.

The approval of denosumab was delayed in October 2009, when the FDA's Division of Reproductive and Urologic Products issued a Complete Response Letter for the biologics license application for denosumab in the treatment and prevention of postmenopausal osteoporosis, according to Amgen. ■



Patterns Emerge on Fractures From Bisphosphonate Use

BY M. ALEXANDER OTTO

EXPERT ANALYSIS FROM A
RHEUMATOLOGY SEMINAR
SPONSORED BY UCLA

MARINA DEL REY, CALIF. — As the debate unfolds over both whether bisphosphonates cause femur fractures and the degree to which the benefits of drugs still outweigh the risks, a phenomenon has emerged.

Women who have taken bisphosphonates for years are being seen with thigh pain that is easy to mistake for hip or knee arthritis. They have a unique range of radiologic findings, and they either have permanent titanium rods placed in their thigh bones or go on to full femur fractures—sometimes bilaterally—and permanent disability.

"The thinking [among colleagues] is that this is novel and specific to bisphosphonate treatment, but only time will tell," Dr. Benjamin C. Bengs, an orthopedic surgeon at the University of California, Los Angeles, said in an interview.

The possibility must be added to the hip pain differential in women with long-standing use of the drugs, according to Dr. Bengs and others who were interviewed for this story.

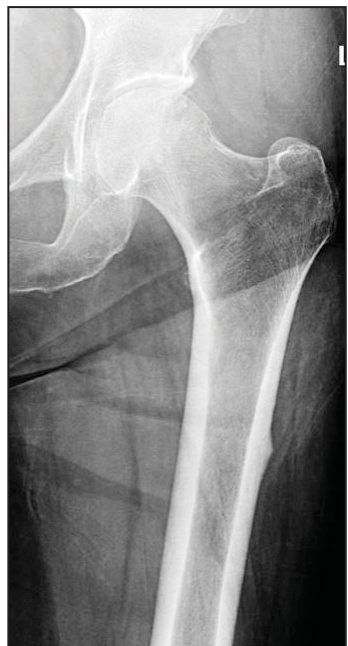
Unusual Radiology Findings

For many of the doctors who were interviewed, the question

isn't so much whether bisphosphonates cause femur fractures, but rather how to care for women with a long history of using the drugs, and how to recognize signs and symptoms of impending trouble.

Any woman with pain over the thigh and those x-ray findings is a candidate for prophylactic rodding, said Dr. Bengs.

The unique findings on x-ray are cortical thickening that is most pronounced on the lateral side of the femur, accompanied by a beaking lesion, also on the lateral side. Intrame-



Cortical thickening, beak-like stress fracture are seen here.

COURTESY UCLA

dullary edema is often present.

The beaking lesion is the start of a horizontal or oblique stress fracture. In time, there generally develops a "little, lucent, dark line extending from the beak to the middle of the bone," Dr. Joseph Robinson, a radiology fellow at Cedars-Sinai Medical Center in Los Angeles, said in an interview.

"Lateral stress fractures are unusual. In our area, they are all related to bisphosphonates," Dr. Kambiz Motamedi, a diagnostic radiologist at UCLA Medical Center.

Both Legs Must be Examined

Standard hip x-rays don't go far enough down to detect the lesion, which is closer to the knee than the typical femur fracture would be, Dr. Robinson said. When they do a hip series, Cedars-Sinai radiologists are careful to image lower down so they don't miss it, he said, noting that they are also putting markers on skin to identify the source of pain.

If the lesion is found, it is imperative to image the other femur as well, said Dr. Stuart L. Silverman, a rheumatologist in private practice in Beverly Hills, Calif. The other femur can go on to fracture, often within 18 months, he said in an interview.

Dr. Bengs noted that in most cases, rodding is the usual treat-

ment. It takes only a matter of weeks to recover from hip-to-knee rod placement, he said. It takes months to recover from a fracture, however, and older patients usually lose 10%-15% of strength and ambulation during convalescence, he added.

"The fractures are devastating," said UCLA and Cedars-Sinai rheumatologist Dr. Solomon N. Forouzes, who has seen two cases in his practice.

Who is at Risk?

Active women who have osteopenia—not osteoporosis—appear to be most at risk, Dr. Nancy Lane, a University of California, Davis, rheumatologist, said in an interview. "What I think is going on" is that bisphosphonates, by reducing bone turnover, lead to the overmineralization of cortical bone, she explained. "Over time, the bones become brittle [and] fail from too much mineralization. They cannot dissipate the load."

It's "probably best not [to use bisphosphonates] in people with low risk of fractures who are very active," she said, adding that use of the drugs might have been "too aggressive" in the past.

A Drug Holiday Is Advised

As the story unfolds, doctors are using bisphosphonates for shorter lengths of time, followed by a drug holiday and ongoing

bone-density monitoring.

The risk of fracture seems to "start at about 3 years and peaks between 5 and 6 years," Dr. Forouzes said. To be ahead of the game, he advises not waiting until the risk peaks. "Back off ahead of time. I do a drug holiday in 3 or 4 years," he said.

It's not clear at this point if the phenomenon—if it is truly real—is limited to alendronate or a bisphosphonate class effect.

Alendronate has been on the market the longest and has been the most widely used agent, Dr. Lane noted. "I am sure over time" it will emerge with other members of the class, as well, she said. ■

Disclosures: Dr. Motamedi, Dr. Robinson, and Dr. Forouzes said that they had no conflicts to disclose. Dr. Bengs disclosed he is a paid consultant for Amgen Inc. Dr. Lane disclosed research grants, royalties, consulting fees from and positions of influence and ownership interests in Amgen, Eli Lilly & Co., and Pfizer Inc. Dr. Silverman disclosed he has served as a speaker, member of a speakers bureau, advisor for Eli Lilly, Novartis Pharmaceuticals Corp., Procter & Gamble, and Roche Inc., and that he has received research support from Eli Lilly, Procter & Gamble, Roche, and Novartis.