

Anticancer Agents Causing Unbearable Skin Toxicity

BY DOUG BRUNK
San Diego Bureau

CORONADO, CALIF. — The side effects associated with epidermal growth factor receptor inhibitors can be so awful that several cancer patients have told Dr. Jonathan Cotliar that they would rather die than continue taking them.

"That's significant when you hear that from many people," Dr. Cotliar said at the annual meeting of the Pacific Dermatologic Association.

One side effect that occurs in 60%-80% of cancer patients who take epidermal growth factor receptor inhibitors (EGFRIs) is skin toxicity, mostly in the form of papulopustular lesions. Paronychia, fissures, xerosis, alopecia, eyelash trichomegaly, telangiectasias, and photosensitivity also can occur.

"I think the companies that developed these drugs underestimated the significance of cutaneous toxicity," said Dr. Cotliar, director of inpatient dermatology services in the division of dermatology at the University of California, Los Angeles.

The incidence of skin toxicity among patients who take the monoclonal antibodies cetuximab (Erbix) or panitumumab (Vectibix) is somewhat higher compared with those who take the tyrosine kinase inhibitors erlotinib (Tarceva) or gefitinib (Iressa). All of the agents cause apoptosis of keratinocytes. "That's probably the major event that allows for what we see clinically in these patients," he said.

"We also know that there is early initiation of keratinocyte differentiation. In

theory, that allows the stratum corneum to become impaired, which leads to many of these toxicities. We also know that inhibition of epidermal growth factor leads to epithelial cell production of proinflammatory mediators. That allows for the adaptive immune response to take hold," he explained.

Papulopustular lesions commonly occur on the face, chest, back, and scalp. The palms and soles are spared.

Histology reveals a thinned stratum corneum, dilated follicular infundibula, necrotic keratinocytes, and mixed inflammation in the upper dermis. "In addition, you may see acantholysis of the follicular epithelium," Dr. Cotliar said.

Ironically, skin toxicity—specifically the papulopustular lesions—is a surrogate marker for treatment efficacy of EGFRIs. "We know that this eruption is more severe and incidence is greater in responders to these medications than in those who don't respond," said Dr. Cotliar, who disclosed that he is a consultant for Amgen Inc., which manufactures panitumumab, and has received honoraria from the company.

"We also know that there is a nice correlation between survival, both overall and progression free, [and] severity of the rash. We don't know if this is an epiphenomenon or if there's something about the cutaneous toxicity that's allowing the immune response to percolate and fight the underlying cancer," he noted.

The severity of papulopustular lesions seems to be linked to the EGFR dose. "We also know that patients typically develop these lesions 1-3 weeks after their

first infusion or their first pills," he said. "The maximal toxicity occurs by weeks 3-5."

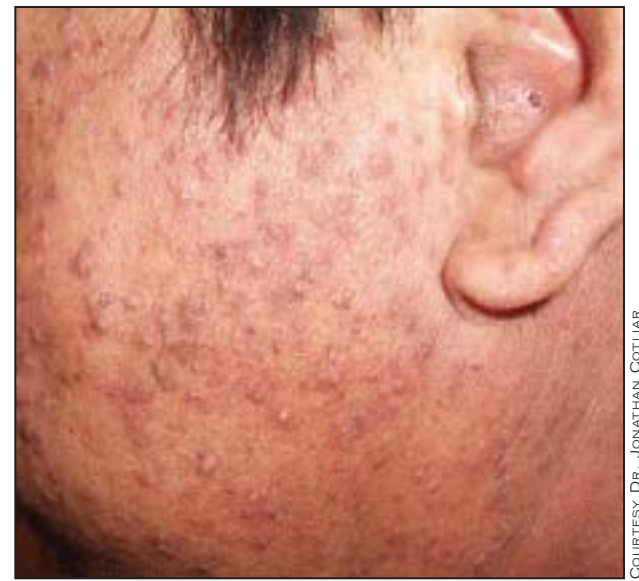
Once patients stop taking the EGFRi, the cutaneous side effects usually resolve within a couple of weeks.

There is no current standard for treating skin toxicity associated with EGFRi use. A proposed treatment algorithm was recently published (Oncologist 2007;12:610-21), but "everything we know about treating these patients is based on case reports," Dr. Cotliar said.

A first approach might involve modifying the dose of the EGFRi by following package insert instructions. Most patients referred to Dr. Cotliar and his associates are started on 1% or 2% hydrocortisone or sometimes tetracycline or doxycycline.

"A lot of times I will start patients on doxycycline 100 mg b.i.d.," he said. "I also typically start—for the first week or two—with a mid- to high-potency topical corticosteroid."

One "black hole" among possible treatment options is isotretinoin. "Nobody's sure what effect it has on tumor biology," he said. "We're also not sure of its effect on EGFRIs. We need to know more about that. We do know from case reports that 20-30 mg/day is successful in



Papulopustular lesions are commonly seen in patients who are taking epidermal growth factor inhibitors.

COURTESY DR. JONATHAN COTLIAR

helping resolve some of these lesions."

Other potential treatments for papulopustular lesions include colloidal oatmeal lotion, topical erythromycin, clindamycin, metronidazole, and topical retinoids.

Potential treatments for xerosis and pruritus triggered by the use of EGFRIs include bland emollients and antihistamines.

Potential treatments for paronychia and fissures include aluminum acetate soaks, 4% thymol, emollients, topical corticosteroids, intralesional steroids, systemic antibiotics, electrodesiccation, cryosurgery, surgical debridement, and nail plate avulsion, Dr. Cotliar said.

Lastly, pulsed dye lasers can be used to treat telangiectasias. ■

Immunostaining Helps Classify Extramammary Paget Disease

BY BRUCE JANCIN
Denver Bureau

AMSTERDAM — A panel of immunohistochemical stains, including human epidermal growth factor receptor 2/neu and CDX2, is useful in distinguishing extramammary Paget disease that is limited to the skin versus the subset of secondary extramammary Paget disease that is associated specifically with concurrent or future anogenital cancer, Dr. Jared Abbott said at the 11th World Congress on Cancers of the Skin.

Other investigators have postulated that the triad of cytokeratin 7 (CK7), CK20, and BRST-2 immunohistochemical stains is broadly useful in distinguishing extramammary Paget disease (EMPD) that is limited to the skin—known as primary EMPD—from all forms of secondary extramammary Paget disease, but Dr. Abbott did

not find this to be the case in his own large series. Indeed, caution should be exercised in relying upon the triad of immunostains for this purpose, said Dr. Abbott of the Mayo Clinic, Rochester, Minn.

EMPD is an uncommon condition occurring primarily in the elderly, with more women than men affected. It arises as a cutaneous adenocarcinoma with a proclivity for sites rich in apocrine glands. Patients with EMPD often present with a prominent solitary plaque lesion in the anogenital or vulvar region. The lesion is erythematous, eczematous, and often pruritic. The course is often locally aggressive, with frequent recurrences.

The classic histopathologic findings of EMPD consist of clusters of epithelial cells with pagetoid extension throughout the epidermis, often accompanied by a superficial lymphocytic inflammatory infiltrate, he said at the congress, which was sponsored by the Skin Cancer Foundation and Erasmus University.

The distinction between primary and secondary EMPD is important because the prognoses are entirely different. Primary EMPD, which accounts for at least three-quarters of cases, has a good prognosis, whereas secondary EMPD has a very poor prognosis because the skin disorder is often accompanied—or, in the months to come, followed—by a gastrointestinal or genitourinary malignancy. Unfortunately, primary and secondary EMPD can't be differentiated based upon histopathology.

"Their [hematoxylin and eosin stains] look exactly alike," Dr. Abbott said.

Other investigators have turned to immunohistochemical staining patterns in an effort to make the distinction. It has been reported that primary EMPD is often CK7- and BRST-2-positive and CK20-negative, whereas secondary EMPD is BRST-2-negative, CK20-positive, and equivocal in terms of CK7.

To see if he could verify this finding, and to assess the utility of some newer immunohistochemical stains, Dr. Abbott studied excisional biopsy specimens from 61 Mayo Clinic patients with EMPD. The median age at diagnosis was 73 years, and 44 patients were women. A total of 45 patients had primary EMPD. The 16 with secondary EMPD, as determined during a median 4-year follow-up, consisted of seven patients with anorectal carcinomas, four with prostate cancer, and five with urothelial cell cancer.

All patients in both the primary and secondary EMPD groups were CK7-positive, so that was of no help, he said. In addition, CK20, BRST-2, androgen receptor, and cyclin D1 did not prove to be of much assistance in distinguishing primary from secondary EMPD. (See box.)

In contrast, HER2/neu and CDX2 were quite helpful in separating primary from secondary EMPD involving anorectal malignancy. Five of the seven patients with lower GI cancer stained positive for CDX2, and all seven were HER2/neu negative. Unfortunately, no staining pattern proved useful in identifying patients with prostate or urothelial cell cancer.

The finding that more than two-thirds of patients with primary EMPD were HER2/neu-positive, and that the positivity rate was even higher among those with recurrent primary EMPD, raises the possibility that Herceptin (trastuzumab) might be effective in these individuals, although that has never been studied, Dr. Abbott said. ■

Percentage of Patients With a Positive Immunostain

	Primary EMPD (n = 45)	Secondary EMPD (n = 16)
Androgen receptor	20%	0%
BRST-2	44%	25%
CDX2	2%	31%
CK7	100%	100%
CK20	22%	56%
Cyclin D1	73%	56%
HER2/neu	69%	50%

Note: Based on a study of 61 patients with extramammary Paget disease (EMPD).
Source: Dr. Abbott