

# Approaches Vary on Ovarian Transplants

BY KATE JOHNSON  
Montreal Bureau

Two recent births made possible through maternal ovarian transplant procedures were the result of markedly different techniques and approaches.

U.S. expert Sherman Silber, M.D., of St. Luke's Hospital, St. Louis, performed an ovarian allotransplant between 24-year-old identical twins, one of whom had premature ovarian failure. The procedure restored the patient's fertility and her ability to conceive naturally (*N. Engl. J. Med.* 2005;353:58-63).

In Israel, the transplant performed by Dror Meirou, M.D., of Chaim Sheba Medical Center in Tel Hashomer, and colleagues was an autotransplant of a 28-year-old cancer patient's previously frozen healthy ovarian tissue. Conception was achieved through in vitro fertilization (*N. Engl. J. Med.* 2005;353:318-21).

In the U.S. patient, a woman who had experienced premature ovarian failure at age 14, laparoscopic examination and ovarian biopsy showed atrophic, elongated ("streak") gonads with no follicles and a small uterus with an otherwise normal reproductive tract. Her donor sister had three children who had been conceived naturally, and she had been using oral contraception in the year preceding the procedure.

The donor's ovary was laparoscopically removed, and the cortical tissue was dissected *ex vivo*. Meanwhile, the recipient underwent a minilaparotomy during which the cortex of each streak ovary was

resected, exposing the raw surface of the medulla.

Hemostasis was controlled with pinpoint microbipolar forceps and continuous irrigation with heparin-treated saline to prevent the formation of a hematoma under the graft.

One-third of the donor ovary was sutured onto the raw medulla of each recipient ovary, and the remaining third was frozen. Analysis of spare tissue from the recipient's ovaries confirmed that there was extensive fibrosis and that there were no follicles.

Both sisters returned home 1 day after the procedure.

At 71 days after transplantation, a 14-mm follicle was observed in the recipient, her serum estradiol level was 154 pg/mL, and her uterine lining was 8 mm thick. Her first postoperative menses occurred at 80 days, although it lasted only a single day. Her ovaries remained quiescent until 128 days after the procedure when another 14-mm follicle was observed. At 142 days after the procedure, she had a heavy menstrual period.

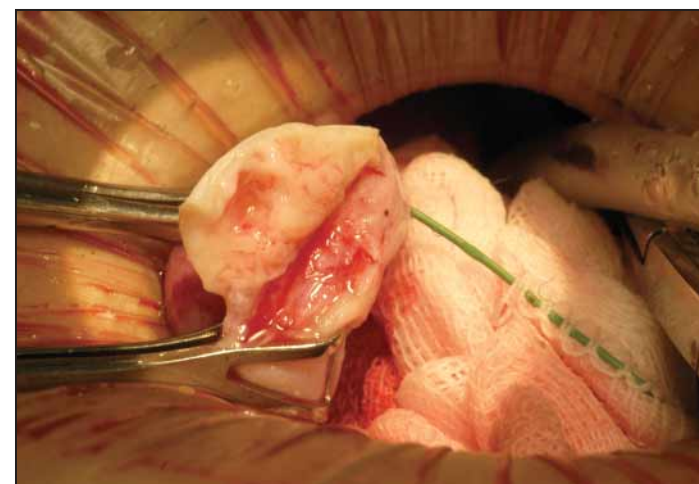
On day 26 of her second menstrual cycle, her  $\beta$ -hCG level (828 mIU/mL) indicated that she was pregnant, and 5 weeks after her second menstrual period, a normal intrauterine pregnancy was confirmed by ultrasound. She gave birth vaginally to a healthy infant at 38 weeks' gestation.

"It is extremely unlikely that the restoration of ovarian function in this patient after transplantation was due to residual follicles in the streak ovary of the recipient," Dr. Silber and his associates wrote. "She had

a decade-long history of amenorrhea with elevated gonadotropin levels on all occasions on which they were measured and no detectable follicles on pathologic examination."

The Israeli transplant patient had experienced ovarian failure after high-dose chemotherapy for non-Hodgkin's lymphoma. Ovarian tissue containing many primordial follicles was harvested and frozen before she underwent high-dose chemotherapy but after she had undergone a second-line conventional chemotherapy regimen.

The patient remained free of disease 24 months after undergoing chemotherapy, at which point she requested autotransplantation of the thawed ovarian tissue. Strips of the tissue were transplanted to the left ovary, and small fragments were injected into the right ovary. Menstruation resumed spontaneously 8 months later, and baseline levels of antimüllerian hormone, which were previously undetectable (consistent with ovarian failure), were high—consistent with the presence of active follicles in an early stage of growth. This was followed by a rise in inhibin B to levels re-



During ovarian allotransplant, one-third of the donor ovary is sutured onto the raw medulla of each recipient ovary.

WILLIAM ANDREA/ST. LUKE'S HOSPITAL

ported in ovulatory women. Ultrasonography revealed a preovulatory follicle in the left ovary.

The next month, another spontaneous menstrual period occurred, after which modified natural-cycle in vitro fertilization was performed. A single egg was retrieved and fertilized, and a four-cell embryo was transferred to the uterus. A healthy infant was delivered by cesarean section at 38 weeks' gestation.

"Although we cannot rule out the possibility that the egg was derived from the native ovary, we consider this possibility very unlikely, given the consistent evidence of ovarian failure after high-dose chemotherapy and the timing of restoration of ovarian function after transplantation," they reported. ■

## Should Ovarian Transplant Be Made More Widely Available?

BY KATE JOHNSON  
Montreal Bureau

COPENHAGEN — The recent announcement of two births made possible by ovarian transplant procedures marks a new stage in the field of fertility restoration, raising ethical questions about whether such procedures should be made more widely available, according to Anthony Rutherford, M.D.

"Is it ethical now to start storing ovarian tissue for patients? Is this still experimental research or is it established clinical practice?" Dr. Rutherford, a consultant gynecologist at Leeds (England) General Infirmary, asked during a presentation at the annual meeting of the European Society for Human Reproduction and Embryology.

Experts in the field of ovarian transplant are divided about how the technology should be applied and who should undergo the procedure.

The majority of work in this area has focused on women who are about to undergo aggressive chemotherapy, which generally leads to infertility. These patients freeze their healthy ovarian tissue before having chemotherapy. Once their cancer is in remission, they can have small pieces of their ovarian tissue transplanted into them, a procedure known as autotransplantation.

This was the case with a 28-year-old Israeli woman who gave birth at the end of June after ovarian transplantation followed by in vitro fertilization (IVF), reported Dror Meirou, M.D., of Sheba Medical Center in Ramat Gan, Israel (<http://content.nejm.org/cgi/reprint/NEJM055237v1.pdf>). (See accompanying story.)

A few weeks earlier, a baby was born to a 24-year-old U.S. woman with no history of chemotherapy (*N. Engl. J. Med.* 2005;353:58-63). This woman had experienced premature ovarian failure at age 14. Instead of receiving an autotransplant of her own ovarian tissue, she was the first recipient of an ovarian allograft, receiving tissue from her identical twin.

The choice by her surgeon, Saint Louis-based Sherman Silber, M.D., to extend fertility restoration beyond the realm of chemotherapy patients, to move from autotransplantation into allotransplantation, and to use a groundbreaking transplant technique, raises the question of opening access to such techniques to a wider population of women—and for more diverse reasons.

Until now, transplant efforts aimed at

restoring ovarian function and ovulation have required IVF to achieve a pregnancy. But Dr. Silber's technique has eliminated the necessity of that expensive procedure, achieving the world's first human orthotopic ovarian transplant that allowed natural conception.

(The birth of a Belgian baby last year following an orthotopic ovarian transplant procedure and natural conception was questioned by some experts, since it could not be confirmed that she had ovulated from the transplanted ovarian tissue [*Lancet* 2004;364:1405-10]. Since her ovaries had been left in place, spontaneous ovulation could not be ruled out.)

From the points of view of Dr. Silber's sibling patients, ovarian transplant is a minimally invasive outpatient procedure—possibly giving the recipient years of potential for spontaneous conceptions.

Dr. Silber said that he believes the appeal of this more patient-friendly ovarian transplantation could be wide reaching, extending beyond autotransplants for chemotherapy patients and even beyond allotransplants for patients with premature ovarian failure. Dr. Silber has per-

**Many physicians are hesitant to embrace ovarian transplant as a routine clinical practice, even if there is a medical reason for the procedure.**

formed two additional ovarian transplants in two other twin sets since his first success, but to date there are no pregnancies.

He has already had requests from general infertility patients for allotransplants as an alternative to egg donation. (Some couples say they have no other choice for religious reasons.)

Dr. Silber said he sees the appeal of ovarian transplant extending to the general population who might choose ovarian tissue freezing and subsequent autotransplantation in the hopes of extending their biological clocks.

Dr. Rutherford expressed caution with regard to these advances. "We certainly need to be very careful about the patients that we select," he said in an interview, adding that he feels it is premature to offer ovarian transplant for social rather than medical reasons.

And even for those patients who have medical reasons for wanting ovarian transplant, many physicians, including Dr. Rutherford, are hesitant to embrace the procedure as a routine clinical practice. "Are we giving false hope to vulnerable patients?" he asked.

Dr. Rutherford has called for the creation of a registry to keep track of all ovarian transplant cases and to follow them to assess the efficacy and safety of the procedure. ■