

End-On Dermoscopy Sheds Light on Melanonychia

BY ERIK GOLDMAN
Contributing Writer

NEW YORK — End-on dermoscopy is an invaluable tool in making an accurate diagnosis in patients who present with dark streaks in the nails of their fingers or toes, Dr. Nathaniel Jellinek said at the American Academy of Dermatology's Academy 2007 meeting.

Because the dorsal nail plate is produced by the proximal nail matrix, and the ventral plate is produced by the distal matrix, an end-on dermoscopic view of the patient's nails can provide something of a map of the nail, indicating the points from which the pigment is emanating (J. Am. Acad. Dermatol. 2006;55:512-3). This can be a helpful guide as to where and when to biopsy, said Dr. Jellinek of the department of dermatology, Brown University, Providence, R.I.

The real value of end-on dermoscopy is not so much that it leads to a definite diagnosis in and of itself, but that it can tell you where you need to look when taking a biopsy, he said. It helps you zero in on the lesion location.

Dorsal pigmentation points to a proximal matrix lesion, whereas pigmentation of the ventral aspect of the nail plate points to distal lesions. "You still have to biopsy if you are not sure what you're looking at," Dr. Jellinek said.

Nail biopsies, however, are tricky. Small biopsies in the setting of a large lesion run the risk of missing something important, but larger full-thickness biopsies (greater

than 3 mm) increase the risk of permanent dystrophy, particularly of the proximal matrix. This can lead to permanent split nails.

Dr. Jellinek outlined his published algorithmic approach for assessing and evaluating longitudinal melanonychia. If the lesion seems to be in the distal nail matrix and measures 3 mm or less, a 3-mm punch biopsy is adequate and safe. If the lesion is larger than 3 mm, however, a newer technique—the matrix shave biopsy—may be a better option (J. Amer. Acad. Dermatol. 2007;56:803-10).

Any proximal matrix lesion can be handled elegantly by the matrix shave biopsy. "Done right, there's minimal risk of nail dystrophy," he said of the shave technique. Any lesion of the lateral aspects of the nail unit should be handled by lateral longitudinal excision.

Longitudinal brown or black streaks on a nail present a diagnostic challenge. In most cases, the underlying etiology is benign, but in some, these streaks can signal the presence of nail melanoma.

The first diagnostic step is to consider the patient's age and overall cutaneous appearance, according to Dr. Jellinek. Melanomas are extremely rare in children and

younger adolescents; this is reassuring but certainly not an absolute finding, and each patient must be evaluated on a case-by-case basis. Furthermore, "always look at the patient's whole skin. It can provide a lot of clues," Dr. Jellinek added. Then, go to dermoscopy and end-on dermoscopy, preferably using a water-soluble medium.

The observable diagnostic features of melanocytic nevi on dermoscopy include brown, longitudinal pigmentation with smooth, parallel lines and consistent thickness. Brown pigmentation overlaid by longitudinal lines showing irregularity of thickness, spacing, or alignment are suggestive of melanoma (Dermatol. Ther. 2007;20:3-10).

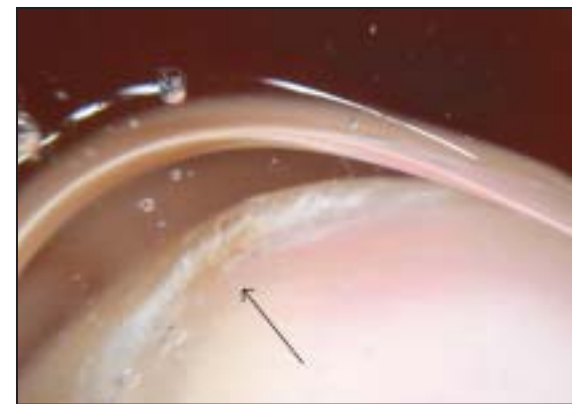
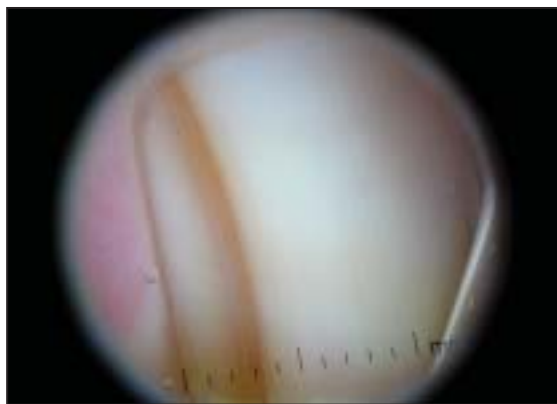
Grayish bands without any brown stripes are suggestive of lentiginos or other types of melanocytic activation, and are much less suggestive of melanoma. Round-shaped black spots are generally

blood spots under the nail plate, indicative of injury but not neoplasia. It is important to note that the presence of blood does not rule out an underlying neoplasm (J. Am. Acad. Dermatol. 2007;57:176).

Although most physicians notice brown streaks on a patient's nails, and quickly jump into a work-up to rule out malignant melanoma, many overlook cases of erythronychia, or red streaks in the nail plate. "It's underrecognized in our clinics. I'm seeing red bands in the nails at least once a week," Dr. Jellinek said.

These lesions almost always involve the distal nail matrix, and although they are usually innocuous, this is not always the case.

The real worry is squamous cell carcinoma, which is, fortunately, rare in the nail bed, he noted. If the red streak is on only one nail and is long standing, then it is probably stable and not neoplastic. ■



Dermoscopy of the left great toenail (left) shows a longitudinal band with parallel brown lines. With end-on dermoscopy, the pigment maps to the ventral surface of the nail plate's free edge (arrow).

PHOTOS COURTESY DR. NATHANIEL JELLINEK

'Fungal Fridays' and Other Onychomycosis Treatment Tips

BY DOUG BRUNK
San Diego Bureau

CORONADO, CALIF. — A patient who has abnormal-looking nails with a normal plantar and web surface is unlikely to have onychomycosis, Dr. Boni E. Elewski said at the annual meeting of the Pacific Dermatologic Association.

The presence of tinea pedis on the plantar surface or web space confirms that clinical suspicion.

"There are several exceptions, one of which is someone who has obtained an infection from a pedicure," said Dr. Elewski, professor of dermatology at the University of Alabama, Birmingham.

"You can't eliminate that. So if you have a patient with pristine feet and they have no [previous] history of tinea pedis, ask if they get regular pedicures, because you can

get a direct infection of the nail plate from a pedicure," she explained.

The other exceptions are white superficial onychomycosis and proximal white subungual onychomycosis, two subtypes in which the fungus directly attacks the nail plate rather than the skin first.

Dr. Elewski provided several other clinical pearls regarding onychomycosis:

► **A patient with abnormal fingernails and normal toenails is unlikely to have onychomycosis.** The exception is *Candida* onycholysis. "This occurs commonly in women who have Raynaud's syndrome and other patients who have collagen vascular disease, but that's a very small minority of patients," she said.

► **Fluconazole 200-400 mg once a week is effective for *Candida* onychomycosis or paronychia.** "We underuse this drug in dermatology," she said. "It is a good antifungal and it's very cheap, about 25 cents per tablet. You only need to treat for 6-8 weeks in most patients."

She usually instructs her patients to take fluconazole on Fridays and uses the term "fungal Fridays" as a catchy reminder. Some of her dermatology residents prefer Tuesdays or, as they call it, "Toesdays."

► **Know the bad prognostic factors of onychomycosis.** These include dermatophytoma, thick nail, a total dystrophic nail, predominantly lateral nail involvement, and immunocompromised and/or diabetic patients.

Physicians can improve the prognosis in patients with dermatophytoma by debriding the area as much as possible. "You can give patients antifungal cream, lotion, or gel to smear under it, and then treat it with an oral antifungal," said Dr. Elewski, a past president of the American Academy of Dermatology.

She also noted that patients with thick nails require

careful evaluation because not all of them will have onychomycosis. "Thick nails could come from trauma, from running or skiing, or from runner's toe," she explained.

In patients with lateral nail involvement, she clips away at the lateral edge, smears in antifungal cream, and continues treatment with oral antifungals.

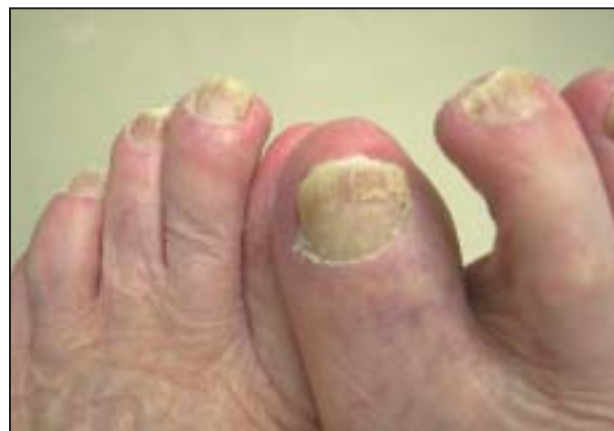Most patients with a bad prognostic factor will require treatment with oral terbinafine 250 mg daily or itraconazole 400 mg daily for 1 week per month for 4 months or longer.

► **Itraconazole is the choice in nondermatophyte mold infections of the nail.** There are two other drugs on the horizon "that may supersede itraconazole in this situation," Dr. Elewski said. These are posaconazole (Noxafil), which is not approved for this indication but is under investigation, and a drug in development called albaconazole.

► **Topical antimycotic agents may be sufficient to treat onychomycosis in certain situations.** The only topical agent that is approved by the Food and Drug Administration for onychomycosis is 8% ciclopirox olamine lacquer. Dr. Elewski said that she also finds it useful in white superficial onychomycosis and in minimal nail disease.

► **The nail can provide clues to skin disease.** To illustrate, she discussed the case of a patient who presented with a scaly dermatosis on the pretibial area. "Is this eczema? Stasis dermatitis?" she asked. "If the toes are abnormal and the patient has onychomycosis, there is a high likelihood that a scaly rash on the lower legs could be a dermatophyte infection. If the toes are normal, the patient probably does not have a dermatophyte infection on the lower legs."

Dr. Elewski disclosed that she has conducted clinical research for Novartis, Barrier Therapeutics, and Stiefel Laboratories. ■



Bad prognostic factors for onychomycosis include dermatophytoma, thick nail, and a total dystrophic nail.

COURTESY DR. BONI E. ELEWSKI