

Viability-Guided PCI After Acute MI Cuts Recurrence

BY BRUCE JANCIN
Denver Bureau

BARCELONA — Dobutamine echocardiography performed a couple of days after nonrevascularized acute MI reliably distinguishes those patients likely to benefit from percutaneous coronary revascularization prior to hospital discharge from those who don't need PCI, Dr. Gerit Veen said at a joint meeting of the European Society of Cardiology and the World Heart Federation.

The purpose of the imaging procedure in this situation is to identify patients who have viable—and therefore vulnerable—myocardium in the infarct area. They are the ones at high risk for reinfarction during the next 3-6 months during the post-MI recovery phase. Stenting their infarct-related artery as soon as possible is warranted.

On the other hand, patients without viable myocardium in the infarct zone are at little risk. They can be managed medically, added Dr. Veen of the VU University Medical Center, Amsterdam.

These were the key findings of the Viability-Guided Angioplasty After Acute Myocardial Infarction (VIAMI) trial. The 12-center Dutch randomized trial was the first-ever formal study of viability-guided revascularization in patients not undergoing primary PCI.

VIAMI involved 291 MI patients not treated by primary PCI. About half got thrombolytic therapy, while the remainder experienced spontaneous reperfusion and presented too late to be eligible for thrombolysis. All underwent dobutamine echocardiography when stabilized 2-3 days post MI.

The 216 patients who displayed viability—meaning two or more myocardial segments responded to dobutamine stimulation—were randomized to immediate PCI with stenting of the infarct-related artery, with interhospital transport if needed, or to a more conservative watchful-waiting approach with PCI reserved for those who developed ischemic symptoms. Patients



without viability in the infarct zone were followed in a registry.

The primary study end point was the 6-month combined rate of death, recurrent MI, or unstable angina. It was 6.6% in the PCI group, a 59% risk reduction relative to the 15.5% rate in the watchful-waiting arm. The difference resulted from a marked disparity in unstable angina: 2.8% in the PCI group, compared with 11.8% with watchful waiting.

In addition, 17.3% of patients in the watchful-waiting arm underwent elective revascularization in 6 months. None in the PCI group did.

"We believe viability testing should become a standard tool in the clinical evaluation of patients in the first days after thrombolysis in acute MI patients without revascularization. And in patients with viability, revascularization should be considered prior to hospital discharge," the cardiologist said.

In acute MI patients with viability, revascularization should be considered prior to hospital discharge.

DR. VEEN

The primary end point rate in registry participants lacking viable infarct-zone myocardium was low, 5.3%. "The message here is that when you don't have viability, it's not necessary to routinely do angioplasty," Dr. Veen noted.

Discussant Dr. Carlo Di Mario of Royal Brompton Hospital, London, observed that the VIAMI message is out of step with the most recent European Society of Cardiology guidelines on management of acute MI, which call for angiography with an eye toward possible PCI within 24 hours in all patients.

He voiced concern that even a 2- to 3-day delay for viability testing as in VIAMI could be sufficient to lose two-thirds of the benefit provided by a routine early invasive strategy.

But other observers were impressed with the efficiency of the Dutch strategy, which offers a more selective approach than the current popular practice of performing routine PCI in all in order to protect the 20%-30% who would otherwise develop recurrent ischemia during the post-MI recovery phase.

The VIAMI trial was funded by the Netherlands Heart Foundation, Eli Lilly, Boehringer Ingelheim, and Bristol-Myers Squibb. ■

Multislice CT Beats MRI for Diagnosis

Multislice CT had greater sensitivity, specificity, and negative predictive value, with equivalent positive predictive value, than did MRI for angiographic diagnosis of 108 patients.

Multislice CT also had less than half the rate of noninterpretable results.

Dr. Marc Dewey of Humboldt University's Charité Medical School, Berlin, and colleagues assessed patients referred to their center for conventional coronary angiography for suspected coronary artery disease (CAD). Patients were a mean of 64 years old and in sinus rhythm (Ann. Intern. Med. 2006;145:407-15).

After undergoing conventional angiography, each patient within 1 day underwent multislice CT and MRI; readers assessed the results without knowing the results of conventional angiography or other clinical data.

Multislice CT had a sensitivity of 92%, versus 74% for MRI. For specificity, CT rendered 79%, versus MRI's 75%. Negative predictive value was 90% and 84%, respectively, and positive predictive value was 95% for both instruments. Only 7% of CT results were noninterpretable, versus 18% of those produced by MRI. However, for both machines, the only findings that reached statistical significance were sensitivity and the percentage of noninterpretable images.

These findings led the investigators to conclude that in their study, CT was superior to MRI in detecting coronary artery stenoses, and its high negative predictive value "makes it potentially useful as a diagnostic tool for ruling out coronary disease in a population with a low to intermediate pretest likelihood."

—John R. Bell

Atherosclerosis Progression Accelerated in Diabetics

BY PATRICE WENDLING
Chicago Bureau

MONTREAL — Suboptimal glycemic control, elevated plasma osteoprotegerin, and presence of serum interleukin-6 were risk factors for progression of coronary artery calcification in a prospective study of asymptomatic patients with type 2 diabetes.

Despite having no known coronary artery disease, a significant proportion (30%) of the 398 patients followed in the study had atherosclerosis progression, Dr. Avijit Lahiri said at the annual meeting of the American Society of Nuclear Cardiology.

The study provides insight into the risk factors for progression of coronary calcification and establishes the role of combining cardiac CT for coronary artery calcium (CAC) imaging with simultaneous single-photon emission computed tomography (SPECT) myocardial perfusion imaging (MPI) in uncomplicated, stable, asymptomatic patients with type 2 diabetes, Dr. Lahiri said.

CAC can be used to identify patients with increased atherosclerotic burden, but it does not identify obstructive coronary artery disease, explained Dr. Lahiri, director of cardiac imaging and research at Wellington Hospital in London. Therefore, there is a need to use combined MPI to detect silent ischemia. "Interestingly, these tests had a synergistic value on prognosis," he said in an interview. "Thus, it would be cost effective to exclude those without CAC for further testing."

The original study included 510 patients, of whom 20 went on to have cardiac events, and 402 were willing to participate in the follow-up study. Four scans were technically inadequate, resulting in a cohort of 398 patients. Their mean age was 53 years; 61% were male; and their average serum glycosy-

lated hemoglobin (HbA_{1c}) was 8%.

All patients underwent CAC imaging, as well as a clinical evaluation—at baseline and about 2.5 years later—that measured HbA_{1c}; serum interleukin-6 and C-reactive protein; and plasma osteoprotegerin. Those with a CAC score of more than 100 Agatston units at baseline also underwent MPI using a 2-day stress-rest protocol with technetium-99m sestamibi and dipyridamole and maximum treadmill exercise.

At baseline, 211 (53%) of the 398 patients had coronary artery calcification. At follow-up, atherosclerosis progression was observed in 118 (30%) patients, including 22 (5.5%) who had no calcification at baseline, Dr. Lahiri said. Regres-



Age, male gender, presence of hypertension, and baseline HbA_{1c} were predictors of atherosclerosis progression.

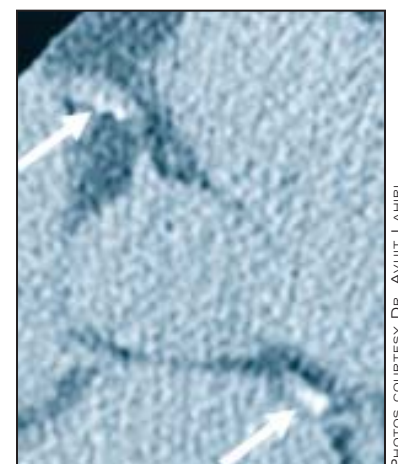
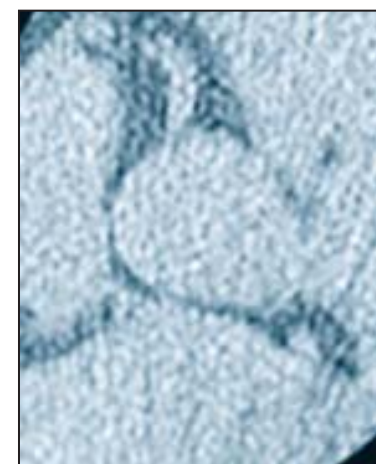
DR. LAHIRI

sion was noted in 3 (0.8%), and there was no change in 277 (70%).

At baseline, 24 patients had an abnormal perfusion scan. Progression of ischemia was seen in 14 patients, regression in 8, and no change in 2.

In a univariate analysis, age, male gender, presence of hypertension, and baseline HbA_{1c} were predictors of atherosclerosis progression. There was no significant association between calcium scores and serum levels of C-reactive protein or IL-6. Surprisingly, statin use was a negative predictor, Dr. Lahiri said.

In a multivariate logistic regression model, serum HbA_{1c} was a most important factor influencing progression. Poor glycemic control raised the risk of progression 10.5-fold; the risk increased 2.5-fold for elevated plasma osteoprotegerin and 2.1-fold for IL-6. ■



SPECT images show progression of atherosclerosis in the right coronary and left circumflex arteries (arrows) of a diabetic patient over 1.7 years.