

# Ultrasonography Underused by Rheumatologists

BY MELINDA TANZOLA  
Contributing Writer

All rheumatologists should aim to incorporate ultrasonography into their daily practice, according to the European League Against Rheumatism's Working Party on Imaging in Rheumatology.

Ultrasound provides a convenient, quick method of confirming diagnostic suspicions. "If you have a patient with hip pain that you think may have arthritis, if you put the ultrasound machine on the patient, you will see the arthritis immediately," said Dr. Nanno Swen, a rheumatologist at the Medical Center Alkmaar (the Netherlands) and a member of the ultrasonography working party.

Experts in ultrasonography discussed the practical applications of sonography and reviewed its advantages and challenges at the annual European Congress of Rheumatology in Amsterdam.

One challenge lies in standardizing the interpretation of ultrasonographic images. Interoperator variability exists even among

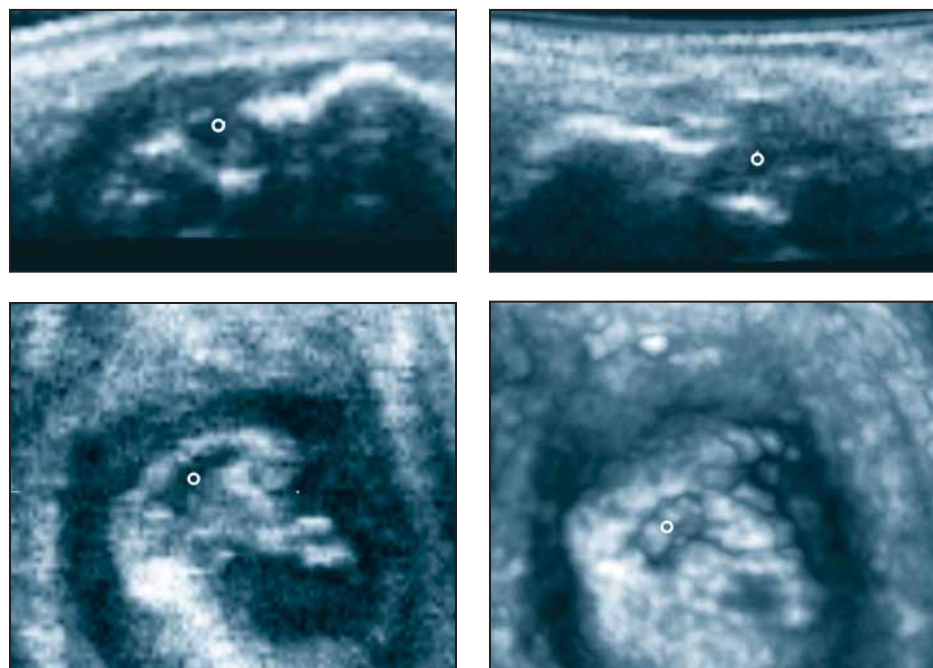
experts, said Dr. Wolfgang A. Schmidt, also a member of the working party.

In his studies of ultrasonography experts, Dr. Schmidt of the Medical Center for Rheumatology in Berlin-Buch, Germany, found that interpretations were most variable at the feet and most consistent at the knee.

Dr. Swen noted, "I can assure you that if you do the same experiment on radiologists, you will have the same problem. ... [A]ll of these imaging modalities have interobserver variability."

Cardiologists and gynecologists do their own sonography, and rheumatologists need to learn the technique. The ultrasonography working party offers 3-day training courses once or twice each year for interested rheumatologists, said Dr. Swen.

Ultrasonography is less expensive than magnetic resonance imaging or bone scans, and it can be quite sensitive, according to Dr. Walter Grassi, chairman of the sonography working party and director of the department of rheumatology at the Università Politecnica delle Marche, Ancona, Italy.



Three-dimensional ultrasound of the metacarpal head in a rheumatoid arthritis patient with a clearly evident bone erosion (°) shown on longitudinal (top left), transverse (top right), coronal (bottom left), and 3-D views (bottom right). Ultrasonography is less expensive than magnetic resonance imaging and it can be quite sensitive, according to Dr. Walter Grassi.

IMAGES COURTESY DR. WALTER GRASSI

## Enthesitis Finding on MRI Central to Psoriatic Arthritis

BY NANCY WALSH  
New York Bureau

GLASGOW, SCOTLAND — Involvement of the distal interphalangeal joint is a common feature of both psoriatic arthritis and osteoarthritis, but a new study using high-resolution magnetic resonance imaging has shown that the local microanatomical environment in psoriatic arthritis is quite distinct, according to Dr. Ai Lyn Tan.

The study included 10 patients with psoriatic arthritis (PsA), 10 with osteoarthritis (OA), and 10 normal controls. The distal interphalangeal joint structures, including ligaments, tendons, and entheses, were imaged using a 1.5-T MRI scanner with a 23-mm diameter microscopy coil and producing T-weighted spin-echo images, Dr. Tan wrote in a poster session at the annual meeting of the British Society for Rheumatology.

PsA was characterized by significant inflammation of ligaments and tendons, along with involvement of the corresponding enthesal insertions. Extracapsular enhancement and nail bed changes were striking, as was diffuse bone edema, particularly of the distal phalanx, she reported.

This condition was present in 80% of the PsA patients, often without cartilage damage.

"It appears that the ligament and extensor tendon entheses are the epicenter of the inflammatory response in PsA, with diffuse involvement of adjacent structures," observed Dr. Tan of the Academic Unit of Musculoskeletal Disease, University of Leeds (England).

Findings among patients with OA also included more ligament and enthesal changes than among the normal controls, but there was significantly less contrast enhancement, compared with PsA. The OA joints were characterized by less soft-tissue swelling, and with degenerative changes such as loss of cartilage, usually at the volar aspect, she noted.

Osteophytes also were present in some OA joints, along with focal bone edema at the tendon entheses.

These observations suggest that, while in PsA inflammatory changes are prominent in ligaments, tendons, and adjacent bone, changes in the enthesal insertions appear to be primary, Dr. Tan suggested. Similar changes are present in OA, but they are much less marked.

"This study in patients with PsA adds further weight to the argument that enthesitis is the unifying concept in patients with true PsA," Dr. Tan also wrote (*Arthritis Rheum.* 2006;54:1328-33).

## Psoriatic Arthritis Diagnostic Criteria Shift Toward Standardization, Specificity

BY KERRI WACHTER  
Senior Writer

STOCKHOLM — The search continues for sensitive and specific classification criteria for psoriatic arthritis.

At an international conference on psoriasis and psoriatic arthritis, the latest results were presented from the classification criteria for psoriatic arthritis (CASPAR) group, an international team of leading psoriatic arthritis researchers. The group has initiated a prospective study to evaluate existing diagnostic criteria as well as to derive new, more accurate criteria, said Philip S. Helliwell, Ph.D., of the rheumatology and rehabilitation research unit at the University of Leeds (England). The group's efforts are modeled on those of the OMERACT (Outcome Measures in Rheumatology) core set for rheumatoid arthritis.

Although clinical and radiologic evidence supports psoriatic arthritis as a separate disease, there's no consensus on diagnostic criteria. Such standardization would enhance research efforts by making patient comparisons easier. Although there are several sets of classification criteria for diagnosing psoriatic arthritis, only one was derived statistically from patient data, Dr. Helliwell said.

A diagnosis according to CASPAR criteria requires established

inflammatory articular disease and a score of at least 3 points from the following features: current psoriasis (2 points), history of psoriasis but no evidence of psoriasis (1 point), family history of psoriasis but no evidence of psoriasis (1 point), dactylitis (1 point), juxtaarticular new bone formation (1 point), negative rheumatoid factor (1 point), and nail dystrophy (1 point). These criteria were specific (0.99) and fairly specific (0.91) for the diagnosis of psoriatic arthritis.

The criteria were derived using data collected prospectively from 588 patients with psoriatic arthritis and from 536 controls with other inflammatory arthritis diagnoses at 30 clinics in 13 countries. Of the controls, 71% had rheumatoid arthritis, 14% had ankylosing spondylitis, 7% had connective tissue disorders, and 5% had other diseases.

The researchers collected data on more than 100 clinical and historical features. They also performed x-rays of the spine, hands, and feet. Samples were analyzed for rheumatoid factor, human leukocyte antigen, and anti-cyclic citrullinated peptide antibody.

For the first iteration of the criteria, the researchers performed a classification and regression tree analysis of existing criteria. The presence of two findings—a history of psoriasis and current

psoriasis—was 97% sensitive and 96% specific. "It's very hard to beat that," Dr. Helliwell noted.

By multivariate logistical regression analysis, the top predictive features were negative rheumatoid arthritis factor, current dactylitis, a history of psoriasis. The results of those two analyses were combined to produce the CASPAR criteria.

Until now, the diagnosis of psoriatic arthritis has been widely based on the Moll-Wright criteria developed in 1973 (*Semin. Arthritis Rheum.* 1973;3:55-78). These criteria require an inflammatory arthritis (peripheral arthritis and/or sacroiliitis or spondylitis), the presence of psoriasis, and the absence of serologic tests for rheumatoid factor.

The Moll-Wright criteria are considered simple and sensitive; however, they are not very specific, suggesting that some seronegative rheumatoid arthritis patients with coincidental psoriasis are mistakenly classified with psoriatic arthritis, Dr. Helliwell said.

"Clearly we need criteria to help us to distinguish this group that may be confounding because of the seronegative rheumatoid factor and coincidental psoriasis," he said. Another group that is hard to diagnose comprises those who meet all other criteria for psoriatic arthritis but who have not yet developed psoriasis.